SIG · SOC · OBSTET · LOND ·
1859



618.06 067
4-6

Library
of the
Academy of Medicine,
Toronto.
2423
Presented by
J. Millman, Esqr. M.D.
1915

Digitized by the Internet Archive
in 2010 with funding from
University of Toronto

http://www.archive.org/details/transactions46obst

OBSTETRICAL TRANSACTIONS.

VOL. XLVI.

TRANSACTIONS

OF THE

OBSTETRICAL SOCIETY

OF

LONDON.

VOL XLVI.

FOR THE YEAR 1904.

WITH A LIST OF OFFICERS, FELLOWS, ETC.

EDITED BY
AMAND ROUTH, M.D., Senior Secretary,
AND
HERBERT R. SPENCER, M.D.



LIBRARY
NOV 2 1 2001
UNIVERSITY OF TORONTO

LONDON:
LONGMANS, GREEN, AND CO.
1905.

PRINTED BY ADLARD AND SON, LONDON AND DORKING.

OBSTETRICAL SOCIETY OF LONDON.

OFFICERS FOR 1905.

PRESIDENT.	DAKIN, W. R., M.D.
VICE-PRESIDENTS.	BARBOUR, A. H. F., M.D. (Edinburgh). ROUTH, AMAND, M.D., B.S. SINCLAIR, Sir WILLIAM JAPP, Knt., M.D. (Manchester). BUTLER-SMYTHE, ALBERT C., F.R.C.S.Ed.
TREASURER.	HERMAN, GEORGE ERNEST, M.D.
CHAIRMAN OF THE BOARD FOR THE EXAMINATION OF MIDWIVES.	PHILLIPS, JOHN, M.D.
EDITOR OF 'TRANSACTIONS.'	SPENCER, HERBERT R., M.D.
HONORARY SECRETARIES.	HANDFIELD-JONES, MONTAGU, M.D. BOXALL, ROBERT, M.D.
HONORARY LIBRARIAN.	LEWERS, ARTHUR H. N., M.D.
EX-OFFICIO MEMBERS OF COUNCIL.	WILLIAMS, Sir JOHN, Bart., M.D. (*Trustee and Past President.* BLACK, J. WATT, M.D. (*Trustee and Past President*). CHAMPNEYS, FRANCIS HENRY, M.D. (*Trustee*). GERVIS, HENRY, M.D. (*Past President*). GALABIN, ALFRED LEWIS, M.D. (*Past President*). HERMAN, G. E., M.D. (*Past President*). MALINS, EDWARD, M.D. (*Ex-President*).
OTHER MEMBERS OF COUNCIL.	ANDREWS, HENRY RUSSELL, M.D. CAMERON, MURDOCH, M.D. (Glasgow). CULLINGWORTH, CHARLES JAMES, M.D. DAWSON, ERNEST RUMLEY. EDEN, THOMAS W., M.D. EWART, JOHN HENRY (Eastbourne). FAIRBAIRN, JOHN SHIELDS, M.D., B.Ch. GOULLET, CHARLES ARTHUR. HANDLEY, WILLIAM SAMPSON, M.S., F.R.C.S. HART, DAVID BERRY, M.D. (Edinburgh). LEA, ARNOLD W. W., M.D. (Manchester). LOCKYER, CUTHBERT, M.D., B.S. ROBERTS, CHARLES HUBERT, M.D. ROBERTS, DAVID W., M.D. RUSHWORTH, FRANK, M.D. SCHARLIEB, MARY ANN DACOMB, M.D. SWAYNE, WALTER C., M.D. (Bristol). WRIGHT, CHARLES J. (Leeds).

STANDING COMMITTEES.

BOARD FOR THE EXAMINATION OF MIDWIVES.

CHAIRMAN. JOHN PHILLIPS, M.D.

EDEN, THOMAS WATTS, M.D.
STABB, ARTHUR FRANCIS, M.B.
McCANN, FREDERICK JOHN, M.D.
FAIRBAIRN, JOHN SHIELDS, M.D.
STEVENS, THOMAS GEORGE, M.D.
LOCKYER, CUTHBERT, M.D.

EX-OFFICIO. DAKIN, W. R., M.D., *President.*
HANDFIELD-JONES, M., M.D., } *Hon. Secs.*
BOXALL, ROBERT, M.D., }

LIBRARY COMMITTEE.

DORAN, ALBAN, F.R.C.S.
ROBINSON, GEORGE H. DRUMMOND, M.D.
SPENCER, HERBERT R., M.D.
LOCKYER, CUTHBERT, M.D.
ANDREWS, H. RUSSELL, M.D.

EX-OFFICIO. DAKIN, W. R., M.D., *President.*
HERMAN, G. E., M.D., *Treasurer.*
HANDFIELD-JONES, M., M.D., } *Hon. Secs.*
BOXALL, ROBERT, M.D., }
LEWERS, ARTHUR H. N., M.D., *Hon. Lib.*

PUBLICATION COMMITTEE.

PHILLIPS, JOHN, M.D.
STABB, ARTHUR FRANCIS, M.B.
DORAN, ALBAN, F.R.C.S.
CULLINGWORTH, CHARLES JAMES, M.D.
EDEN, THOMAS WATTS, M.D.
ROUTH, AMAND, M.D.

EX-OFFICIO. DAKIN, W. R., M.D., *President.*
SPENCER, HERBERT R., M.D., *Editor.*
HANDFIELD-JONES, M., M.D., } *Hon. Secs.*
BOXALL, ROBERT, M.D.. }

FINANCE COMMITTEE.

BOULTON, PERCY, M.D.
CULLINGWORTH, CHARLES JAMES, M.D
WILLIAMS, Sir JOHN, Bart., K.C.V.O., M.D.
BLACK, J. WATT, M.D.
CHAMPNEYS, F. H., M.D.
ROUTH, AMAND, M.D.

EX-OFFICIO.
- DAKIN, W. R., M.D., *President.*
- HERMAN, G. E., M.D., *Treasurer.*
- HANDFIELD-JONES, M., M.D., } *Hon. Secs.*
- BOXALL, ROBERT, M.D., }

PATHOLOGY COMMITTEE.

GRIFFITH, W. S. A., M.D., *Chairman.*
BLACKER, GEORGE FRANCIS, M.D.
DORAN, ALBAN, F.R.C.S.,
EDEN, THOMAS WATTS, M.D.
FAIRBAIRN, JOHN SHIELDS, M.D.
KEEP, ARTHUR CORRIE, M.D., *Secretary.*
LOCKYER, CUTHBERT, M.D.
ROBERTS, CHARLES HUBERT, M.D.
SMITH, GUY BELLINGHAM, F.R.C.S.
SPENCER, HERBERT R., M.D.
TARGETT, JAMES HENRY, M.S.

EX-OFFICIO.
- DAKIN, W. R., M.D., *President.*
- HANDFIELD-JONES, M., M.D., } *Hon. Secs.*
- BOXALL, ROBERT, M.D., }

LIST OF PAST PRESIDENTS OF THE SOCIETY.

1859 EDWARD RIGBY, M.D.
1861 WILLIAM TYLER SMITH, M.D.
1863 HENRY OLDHAM, M.D.
1865 ROBERT BARNES, M.D.
1867 JOHN HALL DAVIS, M.D.
1869 GRAILY HEWITT, M.D.
1871 JOHN BRAXTON HICKS, M.D., F.R.S.
1873 EDWARD JOHN TILT, M.D.
1875 WILLIAM OVEREND PRIESTLEY, M.D.
1877 CHARLES WEST, M.D.
1879 WILLIAM S. PLAYFAIR, M.D.
1881 J. MATTHEWS DUNCAN, M.D., F.R.S.
1883 HENRY GERVIS, M.D.
1885 JOHN BAPTISTE POTTER, M.D.
1887 JOHN WILLIAMS, M.D.
1889 ALFRED LEWIS GALABIN, M.D.
1891 JAMES WATT BLACK, M.D.
1893 G. ERNEST HERMAN, M.B.
1895 F. H. CHAMPNEYS, M.A., M.D.
1897 CHARLES JAMES CULLINGWORTH, M.D.
1899 ALBAN DORAN, F.R.C.S.
1901 PETER HORROCKS, M.D.
1903 EDWARD MALINS, M.D.

REFEREES OF PAPERS FOR THE YEAR 1905

Appointed by the Council.

BLACK, J. WATT, M.D.
BLAND-SUTTON, J., F.R.C.S.
CHAMPNEYS, F. H., M.A., M.D.
CULLINGWORTH, CHARLES JAMES, M.D.
DAKIN, WILLIAM RADFORD, M.D.
DORAN, ALBAN, F.R.C.S.
EDEN, T. W., M.D.
GALABIN, ALFRED LEWIS, M.A., M.D.
HERMAN, G. ERNEST, M.B.
HORROCKS, PETER, M.D.
LEWERS, ARTHUR H. N., M.D.
MEREDITH, W. A., M.B., C.M.
PHILLIPS, JOHN, M.A., M.D.
ROUTH, AMAND, M.D.
SPENCER, HERBERT R., M.D.

OBSTETRICAL SOCIETY OF LONDON.

TRUSTEES OF THE SOCIETY'S PROPERTY.

Sir John Williams, Bart., K.C.V.O., M.D.
J. Watt Black, M.D.
F. H. Champneys, M.A., M.D.

HONORARY FELLOWS.

BRITISH SUBJECTS.

Elected

1899 Hutchinson, Jonathan, F.R.C.S., F.R.S., LL.D., 15, Cavendish square, W.

1892 Lister, The Right Honorable Lord, M.B., F.R.C.S., F.R.S., LL.D., 12, Park crescent, Portland place, W.

1892 Turner, Sir William, M.B., F.R.C.S., F.R.S., Principal of the University of Edinburgh; 6, Eton terrace, Edinburgh.

1904 Williams, Sir John, Bart., K.C.V.O., M.D., F.R.C.P., Physician-Accoucheur to H.R.H. Princess Beatrice, Princess Henry of Battenberg; Consulting Obstetric Physician to University College Hospital; Plâs Llanstephan, Carmarthenshire. *Council*, 1875-6, 1892, 1894. *Hon. Sec.* 1877-9. *Vice-Pres.* 1880-2. *Board Exam. Midwives*, 1881-2; *Chairman*, 1884-6. *Pres.* 1887-8. *Trans.* 12. *Trustee.*

FOREIGN SUBJECTS.

Elected

1899 Budin, P., M.D., Professor, 4, Avenue Hoche, Paris. *Trans.* 1.

1900 Chadwick, James R., M.A., M.D., Physician for Diseases of Women, Boston City Hospital; Clarendon street, Boston, Massachusetts, U.S.

1895 Gusserow, Professor, Berlin.

1866 Lazarewitch, J., M.D., Professor Emeritus and Physician to the Maximilian Hospital; Spaskaja, 2, St. Petersburg. *Trans.* 3.

1899 Martin, A. E., M.D., Professor of Obstetrics and Gynæcology, Greifswald. *Trans.* 1.

1899 Olshausen, R. M., Professor, N. Artilleriestrasse 19, Berlin.

1899 Pinard, A., Professor, 10, Rue Cambacérés, Paris.

1904 Pozzi, Samuel, M.D., 47, Avenue d'Iéna, Paris.

1895 von Winckel, Professor, Sonnenstrasse 16a, Munich.

ORDINARY FELLOWS.

1905.

Those marked thus (*) have paid the Composition Fee in lieu of further annual subscriptions.

Those marked thus (†) reside beyond the London Postal District.

The letters O.F. are prefixed to the names of the "Original Fellows" of the Society.

Elected

1898 Aarons, S. Jervois, M.D.Edin., 14, Stratford place, W.

1900 Abbott, Horatio White, L.R.C.P.Lond., 66, Jackson road, Holloway, N.

1890† Ackerley, Richard, M.B., B.S.Oxon., Croft House, The Hill, Surbiton.

1891 Adams, Charles Edmund, M.R.C.S., 227, Gipsy road, West Norwood, S.E. *Council*, 1901.

1884*†Adams, Thomas Rutherford, M.D., 119, North End, West Croydon. *Council*, 1894-7.

1890 Addinsell, Augustus W., M.B., C.M.Edin., M.R.C.P., Pathologist to the Chelsea Hospital for Women, 7, Upper Brook street, W. *Council*, 1898-1900. *Trans.* 1.

1903 Aldrich-Blake, Louisa Brandrath, M.D., M.S.Lond., 17, Nottingham place, W.

1883*†Allan, Robert John, L.R.C.P.Ed., The Bungalow, Dulwich hill, Sydney, New South Wales.

Elected

1887 Ambrose, Robert, B.A., L.R.C.P. & S.Ed., The Mount, Mile End road, E.

1901 Amsden, Walter, L.R.C.P.Lond., Chalford, Gloucestershire.

1875* Anderson, John Ford, M.D., C.M., 41, Belsize park, N.W. *Council*, 1882, 1898-9.

1903 Anderson, Louisa Garrett, M.B., B.S.Lond., 114a, Harley street, W.

1899 Andrews, E. Collingwood, M.A., M.D.Cantab., 110, Finchley road, South Hampstead, N.W.

1899 Andrews, Henry Russell, M.D., M.R.C.P.Lond., 7, Wimpole street, W. *Council*, 1905. *Trans.* 2.

1870*† Appleton, Robert Carlisle, M.R.C.S., The Bar House, Beverley.

1884 Appleton, Thomas A., M.R.C.S., 46, Britannia road, Fulham, S.W.

1883† Archibald, John, M.D., Hazelden, Wimborne road, Bournemouth.

1871 Argles, Frank, L.R.C.P.Ed., Hermon Lodge, Wanstead, Essex, N.E. *Council*, 1886-7.

1898† Auden, George A., M.D., B.C.Cantab., 54, Bootham, York.

1887 Bailey, Henry Frederick, M.R.C.S., The Hollies, Lee terrace, Lee, S.E.

1880† Balls-Headley, Walter, M.D., F.R.C.P., Lecturer on Obstetrics and Diseases of Women, University of Melbourne, 4, Collins street east, Melbourne, Victoria.

1869* Bantock, George Granville, M.D., Consulting Surgeon to the Samaritan Free Hospital; 14, Upper Hamilton terrace, N.W. *Council*, 1874-6. *Trans.* 2.

1886*† Barbour, A. H. Freeland, M.D.Edin., Lecturer on Midwifery and Diseases of Women, Edinburgh Medical School, 4, Charlotte square, Edinburgh. *Council*, 1898-1901. *Vice-Pres.* 1903–5.

1884† Barraclough, Robert W. S., M.D., Chatsworth, Battle road, St. Leonard's-on-Sea.

Elected

1896 Barrett, Sidney Edward, M.B., B.C.Cantab., 56, Manor road, Stoke Newington, N.

1886† Barrington, Fourness, M.B.Edin., F.R.C.S.Eng., 213, Macquarie street, Sydney, New South Wales.

1891 Barton, Edwin Alfred, L.R.C.P.Lond., 56, Kensington Court, W.

1895† Beachcroft, Francis Seward, L.R.C.P.Lond., The Chains, Petworth, Sussex.

1871 Beadles, Arthur, M.R.C.S., Park House, Dartmouth Park, Forest hill, S.E.

1892 Beauchamp, Sydney, M.B., B.C.Cantab., 95, Cromwell road, S.W. *Council*, 1904.

1896 Belben, Frank, M.B., F.R.C.S., Redlands, Knyveton road, Bournemouth.

1866*†Belcher, Henry, M.D., 28, Cromwell road, West Brighton.

1899 Belfrage, Sydney Henning, M.D.Lond., 1, Montagu place, Montagu square, W.

1871*†Bell, Robert, M.D.Glasg., 15, Half Moon street, Mayfair, W.

1901 Bell, Robert Hamilton, M.A., M.B., B.C.Cantab., Physician to Out-patients, Samaritan Hospital; 27, Seymour street, Portman square, W. *Trans.* 2.

1889† Benson, Matthew, M.D.Brux., Wyndholme, Wigan.

1894 Berkeley, Comyns, B.A., M.B., B.C.Cantab., Physician to Out-patients to Chelsea Hospital for Women; 53, Wimpole street, W. *Council*, 1902-3.

1883† Bertolacci, J. Hewetson, L.S.A., Elstead, Godalming, Surrey.

1889† Best, William James, M.R.C.S., 1, Cambridge terrace, Dover.

1893*†Betenson, William Betenson. L.R.C.P.Lond., Bungay, Suffolk.

1894* Betenson, Woodley Daniel, L.R.C.P.Lond., Holmdale, Woodridinge, Pinner.

Elected

1891† Beville, Frederick Wells, L.R.C.P.Lond., Sussex Lodge, Uxbridge.

1887*†Biden, Charles Walter, L.R.C.P.Lond., Laxfield, Framlingham.

1879* Biggs, J. M., M.R.C.S., L.R.C.P.Lond., Hillside, Child's hill, N.W. *Council*, 1903–4.

1889† Bisshopp, Francis Robert Bryant, M.A., M.B., B.C.Cantab., Parham House, Tunbridge Wells.

1890† Black, George, M.B., B.S.Lond., 15, King Edward street, Oxford.

1868* Black, James Watt, M.A., M.D., F.R.C.P., Obstetric Physician to the Charing Cross Hospital ; 15, Clarges street, Piccadilly, W. *Council*, 1872-4. *Vice-Pres.* 1885-6. *Chairman, Board Exam. Midwives*, 1887-90. *Pres.* 1891-2. *Treas.* 1898-1901. *Trustee.*

1893 Blacker, George Francis, M.D., B.S.Lond., F.R.C.S., Obstetric Physician to University College Hospital; 45, Wimpole street, W. *Council*, 1898-1901. *Board Exam. Midwives*, 1900-1. *Trans.* 2.

1901 Blair, G. MacLellan, M.B., B.S., 93, Maida Vale, W.

1861*†Blake, Thomas William, M.D.St.And., Hurstbourne, Bournemouth, Hants.

1888* Bland-Sutton, John, F.R.C.S., Surgeon to the Middlesex Hospital; 47, Brook street, W. *Council*, 1894-5. *Trans.* 5.

1902† Boardman, Edith, M.D.Brux., Hyderabad, Deccan, India.

1894 Bodilly, Reginald Thomas H., L.R.C.P.Lond., Woodbury, High road, South Woodford.

1902† Bonnar, Kathleen, L.R.C.P. and S.Edin., Dufferin Hospital, Allahabad, India.

1883 Bonney, William Augustus, M.D., 100, Elm park gardens, Chelsea, S.W.

Elected

1900 Bonney, William Francis Victor, M.S., M.D.Lond., F.R.C.S.Eng., Lecturer on Practical Midwifery at Middlesex Hospital; Assistant Physician to Chelsea Hospital for Women; 10, Devonshire street, Portland place, W.

1894† Borcherds, Walter Meent, M.R.C.S., L.R.C.P., Cathcart, Cape Colony.

1903 Bott, Percival George A., L.R.C.P.Lond., 17, Southwick street, Hyde park, W.

1866* Boulton, Percy, M.D., Physician to the Samaritan Free Hospital; 15, Seymour street, Portman square, W. *Council*, 1878-80, 1885, 1896. *Hon. Lib.* 1886. *Hon. Sec.* 1886-9. *Vice-Pres.* 1890-2. *Board Exam. Midwives*, 1890-1. *Chairman*, 1897-1900. *Editor*, 1894-1900. *Trans.* 4.

1886† Boustead, Robinson, M.D., B.C. Cantab., Lieutenant-Colonel, Indian Medical Service; c/o Messrs. H. S. King and Co., 45, Pall Mall, S.W.

1899 Bowie, Albert W., M.B., C.M.Edin., 49, Bruce Grove, Tottenham, N.

1899† Bowring, Walter Andrew, F.R.C.S.Eng., The Pines, Furze Hill, Brighton.

1884* Boxall, Robert, M.D.Cantab., Lecturer on Midwifery and Diseases of Women at the Middlesex Hospital; 40, Portland place, W. *Council*, 1888-90, 1894-5, 1899-1901. *Board Exam. Midwives*, 1891-3. *Hon. Lib.* 1902–3. *Hon. Sec.*, 1904-5. *Trans.* 12.

1902 Boyd, Florence Nightingale, M.D.Brux., L.R.C.P. and S.I., 134, Harley street, W. *Trans.* 1.

1897 Boyd, John Stewart, L.R.C.P.Lond., Victoria House, Custom House, E.

1884† Boys, Arthur Henry, L.R.C.P.Ed., Chequer Lawn, St. Albans.

1877*†Bradley, Michael McWilliams, M.B., Jarrow-on-Tyne.

Elected

1873† Braithwaite, James, M.D., Obstetric Physician to the Leeds General Infirmary; Lecturer on Diseases of Women and Children at the Leeds School of Medicine; 16, Clarendon road, Leeds. *Vice-Pres.* 1877-9. *Trans.* 6.

1880† Branfoot, Arthur Mudge, M.B., c/o Messrs. Woodhead and Co., 44, Charing cross, S.W.

1887 Bridger, Adolphus Edward, M.D.Ed., 18, Portland place, W.

1888*†Briggs, Henry, M.B., F.R.C.S., Surgeon to the Hospital for Women, and Professor of Midwifery and Gynæcology, University College (Victoria University), Liverpool; 3, Rodney street, Liverpool. *Council*, 1901–3.

1894 Brinton, Roland Danvers, B.A., M.D.Cantab., 8, Queen's Gate terrace, S.W.

1887† Brodie, Frederick Carden, M.B., The Hutch, Sandown, Isle of Wight.

1892 Brodie, William Haig, M.D., C.M.Edin., F.R.C.S.Eng., Battle, Sussex.

1902† Brook, William Henry Breffit, M.D., B.S., F.R.C.S., 8, Eastgate, Lincoln.

1868 Brown, Andrew, M.D. St. And., Mayfield, Royston park, Pinner. *Council*, 1893-4. *Trans.* 1.

1865* Brown, D. Dyce, M.D., 29, Seymour street, Portman square, W.

1898† Brown, Haydn, L.R.C.P.Edin., Moorcote, Eversley, Hants.

1889*†Brown, William Carnegie, M.D.Aber., Glassaugh House, Portsoy, N.B.

1902 Browne, Ada Margaret, L.S.A., 64, Belsize park, N.W.

1904 Brydone, James Marr, M.B., B.C.Cantab., 42, Welbeck street, Cavendish square, W.

Elected

1895† Buckley, Samuel, M.D.Lond., M.R.C.P., F.R.C.S.Eng., Physician to the Manchester Northern Hospital for Women and Children; 72, Bridge street, Manchester.

1885*†Bunny, J. Brice, L.R.C.P. Ed., Bishop's Lydeard, Taunton.

1877† Burd, Edward, M.D., M.C., Senior Physician to the Salop Infirmary; Newport House, Shrewsbury. *Council*, 1886-7.

1894 Burt, Robert Francis, M.B., C.M.Edin., 124, Stroud Green road, N.

1888 Burton, Herbert Campbell, L.R.C.P. Lond., Lee Park Lodge, Blackheath, S.E.

1878 Butler-Smythe, Albert Charles, F.R.C.S.Ed., Surgeon to Out-patients, Samaritan Free Hospital; 76, Brook street, Grosvenor square, W. *Council*, 1889-91, 1904. *Vice-Pres.* 1905.

1887* Buxton, Dudley W., M.D. Lond., 82, Mortimer street Cavendish square, W.

1886† Byers, John W., M.A., M.D., M.A.O. (Hon. Causâ), Professor of Midwifery and Diseases of Women and Children at Queen's College, and Physician for Diseases of Women to the Royal Hospital, Belfast; Dreenagh House, Lower crescent, Belfast. *Vice-Pres.* 1899-1902.

1891† Calthrop, Lionel C. Everard, M.B.Durh., c/o H. Calthrop, Esq., Messrs. Child and Co., 1, Fleet street, E.C.

1887† Cameron, James Chalmers, M.D., Professor of Midwifery and Diseases of Infancy, McGill University; 941, Dorchester street, Montreal.

1887† Cameron, Murdoch, M.D.Glas., Regius Professor of Midwifery in the University of Glasgow, 7, Newton terrace, Charing Cross, Glasgow. *Council*, 1903–5.

1903† Cameron, Samuel James Murdoch, M.B., Ch.B.Glasg., 13, Sandyford Place, Glasgow, W.

Elected

1902 Campbell, Janet, M.B., B.S.Lond., Royal Free Hospital, Gray's Inn road, W.C.

1894† Campbell, John, M.A., M.D.Dubl., F.R.C.S., Crescent House, University road, Belfast.

1888*†Campbell, William Macfie, M.D. Edin., 1, Princes gate East, Liverpool.

1886† Carpenter, Arthur Bristowe, M.A., M.B. Oxon., Wykeham House, Bedford park, Croydon.

1903 Chadburn, Maud Mary, M.D.Lond., 16, Harley street, W.

1876* Champneys, Francis Henry, M.A., M.D. Oxon., F.R.C.P., Physician-Accoucheur to, and Lecturer on Midwifery at, St. Bartholomew's Hospital; 42, Upper Brook street, W. *Council*, 1880-1, 1900-1. *Hon. Lib.* 1882-3. *Hon. Sec.* 1884-7. *Vice-Pres.* 1888-90. *Board Exam. Midwives*, 1883, 1888-90; *Chairman*, 1891-5. *Editor*, 1888-93. *Pres.* 1895-6. *Treas.* 1902. *Trans.* 16. *Trustee.*

1867*†Charles, T. Edmondston, M.D., F.R.C.P., 72, Via di San Niccolo da Tolentino, Rome. *Council*, 1882-4.

1874*†Charlesworth, James, M.D., Physician to the North Staffordshire Infirmary; 25, Birch terrace, Hanley, Staffordshire.

1897† Chinery, Edward Fluder, F.R.C.S.Edin., Monmouth House, Lymington, Hants.

1863*†Chisholm, Edwin, M.D., 44, Roslyn gardens, Sydney, New South Wales.

1897 Clark, William Gladstone, M.A.Cantab., F.R.C.S.Eng., Civil Service Club, Capetown.

1893 Clarke, W. Bruce, F.R.C.S., Assistant Surgeon to St. Bartholomew's Hospital, 51, Harley street, W.

1899 Clayton, Charles Hollingsworth, L.R.C.P., 10, College terrace, Belsize park, N.W.

1903† Clayton, John Hazelwood, M.B.Lond., 16, Hagley road, Edgbaston, Birmingham.

1889 Clemow, Arthur Henry Weiss, M.D., C.M.Edin., M.R.C.P.Lond., 101, Earl's Court road, Kensington, W.

Elected

1865*†Coates, Charles, M.D., Physician to the Bath General and Royal United Hospitals; 10, Circus, Bath.

1875* Coffin, Richard Jas. Maitland, F.R.C.P.Ed., 8, Wetherby terrace, Earl's Court, S.W.

1875*†Cole, Richard Beverly, M.D. Jefferson Coll., Philad., 218, Post street, San Francisco, California, U.S.

1888 Cooper, Peter, L.R.C.P.Lond., Stainton Lodge, 35, Shooter's Hill road, Blackheath, S.E.

1875*†Cordes, Aug., M.D., M.R.C.P., Consulting Accoucheur to the "Miséricorde;" Privat Docent for Midwifery at the University of Geneva; 12, Rue Bellot, Geneva. *Trans.* 1.

1883 Corner, Cursham, L.S.A., 113, Mile End road, E.

1903. Corthorn, Alice Mary, M.B., B.S.Lond., 30, St. Mary Abbot's terrace, Kensington.

1877 Crawford, James, M.D.Durh.

1893 Cripps, William Harrison, F.R.C.S., Surgeon to St. Bartholomew's Hospital; 2, Stratford place, W. *Trans.* 2.

1889† Croft, Edward Octavius, M.D.Durh., Hon. Surgeon to the Hospital for Women and Children; Hon. Demonstrator of Obstetrics to the Yorkshire College, Leeds; 33, Park square, Leeds. *Trans.* 1.

1881*†Cronk, Herbert George, M.B. Cantab., Repton, near Burton-on-Trent.

1893 Crosby, Herbert Thomas, M.A., M.B., B.C.Cantab., 19, Gordon square, W.C.

1895 Cross, Ernest W., L.R.C.P.Lond., The Limes, Wallwood Park, Leytonstone.

1886*†Cross, William Joseph, M.B., Horsham, Victoria, Australia.

1898† Cullen, Thomas, M.D.Toronto, Johns Hopkins Hospital, Baltimore, U S.A.

Elected

1875* Cullingworth, Charles James, M.D., D.C.L., LL.D., F.R.C.P., Consulting Obstetric Physician to St. Thomas's Hospital; 14, Manchester square, W. *Council*, 1883-5, 1891-3, 1904-5. *Vice-Pres.* 1886-8. *Board Exam. Midwives*, 1889-91. *Chairman*, 1895-6. *Pres.* 1897-8. *Trans.* 14.

1889*† Cursetji, Jehángir J., M.D. Brux., 123, Girgaum road, Bombay.

1894 Cutler, Lennard, L.R.C.P.Lond., 1, Kensington Gate, Kensington, W. *Trans.* 1.

1885 Dakin, William Radford, M.D., B.S., F.R.C.P., Obstetric Physician to, and Lecturer on Midwifery at, St. George's Hospital; 8, Grosvenor street, W., *Council*, 1889-91. *Hon. Lib.* 1892-3. *Hon. Sec.* 1894-7. *Vice-Pres.* 1898-1901. *Chairman*, 1901–4. *Trans.* 3. *Pres.* 1905.

1868 Daly, Frederick Henry, M.D., 185, Amhurst road Hackney Downs, N.E. *Council*, 1877-9. *Vice-Pres.* 1883-5. *Trans.* 2.

1901 Daly, Frederick James Purcell, L.R.C.P.Lond., 95, Upper Clapton road, N.E.

1904† Das, Kedernath, L.M.S., M.B.Cal., M.D.Madras, Campbell Hospital, Calcutta.

1893 Dauber, John Henry, M.A. Oxon., M.B., B.Ch., Physician to the Hospital for Women, Soho square; 29, Charles street, Berkeley square, W.

1892† Davis, Robert, M.R.C.S., Darrickwood, Orpington, Kent.

1877 Davson, Smith Houston, M.D., Campden villa, 203, Maida vale, W. *Council*, 1889-91.

1891 Dawson, Ernest Rumley, L.R.C.P.Lond., The Broadway, Leyton, E. *Council*, 1904-5. *Trans.* 1.

1889 Des Vœux, Harold A., M.D.Brux., 214, Buckingham gate, S.W. *Council*, 1896-8.

1894 Dickinson, Thomas Vincent, M.D.Lond., M.R.C.P., Physician to the Italian Hospital, Queen square; 33, Sloane street, S.W. *Council*, 1900-2.

Elected

1894 Dickson, John William, B.A., M.B., B.C. Cantab., 42, Hertford street, Mayfair, W.

1886† Donald, Archibald, M.D. Edin., M.R.C.P., Obstetric Physician to the Royal Infirmary, Manchester; Honorary Surgeon to St. Mary's Hospital for Women, Manchester; Sunnyside, Victoria Park, Manchester. *Council*, 1893-5. *Trans.* 3.

1879* Doran, Alban H. G., F.R.C.S., Surgeon to the Samaritan Free Hospital; 9, Granville place, Portman square, W. *Council*, 1883-5. *Hon. Lib.* 1886-7. *Hon. Sec.* 1888-91. *Vice-Pres.* 1892-4. *Pres.* 1899-1900. *Trans.* 23.

1890† Douty, Edward Henry, M.A., M.B., B.C.Cantab., Davos Platz, Switzerland.

1887 Dovaston, Milward Edmund, M.R.C.S., Hatchcroft house, Hendon, N.W.

1899† Down, Elgar, L.R.C.P.Lond., Wingfield House, Stoke, Devonport.

1896 Downes, J. Lockhart, M.B., C.M. Edin., 269, Romford road, E.

1884† Doyle, E. A. Gaynes, L.R.C.P., Colonial Hospital, Port of Spain, Trinidad.

1904† Drake, Ernest C., L.R.C.P.Lond., Station road, Redhill, Surrey.

1894† Drew, Henry William, F.R.C.S., Eastgate, East Croydon.

1883 Duncan, Alexander George, M.B., 25, Amhurst park, Stamford hill, N.

1871* Eastes, George, M.B., F.R.C.S., 35, Gloucester terrace, Hyde park, W. *Council*, 1878-80.

1883† Eccles, F. Richard, M.D., Professor of Gynæcology, Western University; 1, Ellwood place, Queen's avenue, London, Ontario, Canada.

1893 Eden, Thomas Watts, M.D.Edin., M.R.C.P.Lond., Assistant Obstetric Physician to, and Lecturer on Practical Midwifery at, Charing Cross Hospital, 26, Queen Anne street, W. *Council*, 1897-9, 1905. *Board Exam. Midwives*, 1903–5. *Trans.* 5.

Elected

1903† Edge, Frederick, M.D.Lond., F.R.C.S.Eng., 54, Darlington street, Wolverhampton.

1901† Ellis, Francis Hamilton, M.B., B.C.Cantab., Grove Hospital, Tooting Grove, Tooting Graveney, S.W.

1873*†Engelmann, George Julius, A.M., M.D., 336, Beacon street, Boston, Mass., U.S.A.

1898† Evans, David J., M.D.McGill, 939, Dorchester street, Montreal.

1897 Evans, Evan Laming, M.B., B.C.Cantab., F.R.C.S., 9, Stanhope place, Hyde park, W.

1875† Ewart, John Henry, M.R.C.S., L.R.C.P., Eastney, Devonshire place, Eastbourne. *Council*, 1904-5.

1899 Fairbairn, John Shields, M.D., B.Ch.Oxon., Assistant Obstetric Physician to St. Thomas's Hospital, 60, Wimpole street, W. *Council*, 1904-5. *Board Exam. Midwives*, 1904-5. *Trans.* 1.

1894 Fairweather, David, M.A., M.D., C.M.Edin., Carlton Lodge, Palmerston road, Bowes Park, N.

1876† Farncombe, Richard, M.D.Brux., 183, Belgrave road, Balsall heath, Birmingham.

1903† Farncombe, William Turberville, M.D., Harborne, Birmingham.

1869* Farquhar, William, M.D., Deputy Surgeon-General, 40, Westbourne gardens, Bayswater, W.

1882† Farrar, Joseph, M.D., Gainsborough. *Trans.* 1.

1894† Fazan, Charles Herbert, L.R.C.P. Lond., Belmont, Wadhurst, Sussex.

1868* Fegan, Richard, M.D., Westcombe park, Blackheath, S.E.

1883 Fenton, Hugh, M.D., Physician, Chelsea Hospital for Women; 27 George street, Hanover square, W.

1901 Ferguson, George Bagot, M.D., B.Ch.Oxon, Altidore Villa, Pittville, Cheltenham.

Elected

1893† Finley, Harry, M.D.Lond., West Malvern, Worcestershire.

1877*†Fonmartin, Henry de, M.D., 26, Newberry terrace, Lower Bullar street, Nichols Town, Southampton.

1904 Forbes-Ross, Frederick William, M.D.Edin., F.R.C.S. Eng., 15, Gower street, W.C.

1897† Fothergill, W. E., M.B., C.M.Edin., Lecturer on Midwifery and Diseases of Women, Victoria University; Assistant Physician Northern Hospital for Women and Children, Manchester; 13, St John Street, Manchester.

1884 Fouracre, Robert Perriman, M.R.C.S., 58, Tollington park, N.

1886† Fowler, Charles Owen, M.D., Cotford House, Thornton heath. *Council*, 1901–3.

1898 Frampton, Trevethan, M.R.C.S., F.R.C.P., 168, Gloucester terrace, Hyde park, W.

1875*†Fraser, Angus, M.D., Physician and Lecturer on Clinical Medicine to the Aberdeen Royal Infirmary; 232, Union street, Aberdeen. *Council*, 1897-1900.

1888† Fraser, James Alexander, L.R.C.P. Lond., Western Lodge, Romford.

1902† Freeland, Arthur Raymond Stilwell, L.R.C.P., M.R.C.S., St. John's Cottage, Leatherhead.

1883* Fuller, Henry Roxburgh, M.D.Cantab., 45, Curzon street, Mayfair, W. *Council*, 1893. *Trans.* 1.

1886† Furner, Willoughby, F.R.C.S., 13, Brunswick square, Brighton. *Council*, 1894-6.

1874* Galabin, Alfred Lewis, M.A., M.D., F.R.C.P., Obstetric Physician to, and Lecturer on Midwifery at, Guy's Hospital; 49, Wimpole street, Cavendish square, W. *Council*, 1876-8. *Hon. Lib.* 1879. *Hon. Sec.* 1880-3. *Vice-Pres.* 1884. *Treas.* 1885-8. *Pres.* 1889-90. *Trans.* 12.

1888 Galloway, Arthur Wilton, L.R.C.P.Lond., Malverns, Epping.

Elected

1863* Galton, John H., M.D., Chunam, Sylvan road, Upper Norwood, S.E. *Council*, 1874-6, 1891-2. *Vice-Pres.* 1895-8.

1881 Gandy, William, M.R.C.S., Hill Top, Central hill, Norwood, S.E. *Council*, 1897-8.

1886*†Garde, Henry Croker, F.R.C.S. Edin., Maryborough, Queensland.

1887 Gardiner, Bruce H. J., L.R.C.P. Ed., Gloucester House, Barry road, East Dulwich, S.E.

1879 Gardner, John Twiname, 5, Embankment gardens, Chelsea, S.W.

1872*†Gardner, William, M.A., M.D., Professor of Gynæcology. McGill University; Gynæcologist to the Royal Victoria Hospital; 109, Union avenue, Montreal, Canada.

1876† Garner, John, M.R.C.S., 21, Easy row, Birmingham.

1891† Garrett, Arthur Edward, L.R.C.S. & L.M.Ed., 5, Hertford street, Mayfair, W.

1873*†Garton, William, M.D., F.R.C.S., Inglewood, Aughton, near Ormskirk.

1901 Gayer, Reginald Courtenay, L.R.C.P., 13, Rosary gardens, South Kensington, S.W.

1889* Gell, Henry Willingham, M.A., M.B. Oxon., 36, Hyde park square, W.

1898*†Gemmell, John Edward, M.B., C.M.Edin., Hon. Surgeon to the Hospital for Women, Liverpool; 12, Rodney street, Liverpool.

1902 George, Jessie, L.R.C.P., L.R.C.S.Edin., 42, Marsden street, Calcutta, India.

1859* Gervis, Henry, M.D., F.R.C.P., Consulting Obstetric Physician to St. Thomas's Hospital; The Towers, Hillingdon, Uxbridge. *Council*, 1864-6, 1889-91, 1893. *Hon. Sec.* 1867-70. *Vice-Pres.* 1871-3. *Treas.* 1878-81. *Pres.* 1883-4. *Trans.* 8.

Elected

1866* Gervis, Frederick Heudebourck, M.D.Brux., 1, Fellows road, Haverstock hill, N.W. *Council*, 1877-9. *Vice-Pres.* 1892. *Trans.* 1.

1899† Gervis, Henry, M.A., M.B., B.C.Cantab., 74, Dyke road, Brighton.

1883* Gibbons, Robert Alexander, M.D., Physician to the Grosvenor Hospital for Women and Children; 29, Cadogan place, S.W. *Council*, 1889-90. *Trans.* 1.

1894 Gibson, Henry Wilkes, L.R.C.P. Lond., 6, College terrace, Fitzjohn's avenue, N.W.

1892 Giles, Arthur Edward, M.D. Lond., M.R.C.P., Physician to Out-patients, Chelsea Hospital for Women; 10, Upper Wimpole street, W. *Council*, 1898-1900. *Trans.* 7.

1869 Gill, William, L.R.C.P. Lond., 11, Russell square, W.C.

1891 Gimblett, William Henry, M.D.Durh., "Glanusk," Buckhurst hill, Essex.

1899† Glover, Thomas Anderson, M.D., C.M.Edin., 24, Hallgate, Doncaster.

1894† Goddard, Charles Ernest, M.D., Wembley, Harrow.

1871 *Godson, Clement, M.D., C.M.; 82, Brook street, W. *Council*, 1876-7. *Hon. Sec.* 1878-81. *Vice-Pres.* 1882-4. *Board Exam. Midwives*, 1877, 1882-86. *Trans.* 5.

1893† Gordon, Frederick William, L.R.C.P.Lond., Manukau road, Auckland, New Zealand.

1883 Gordon, John, M.D., 63, Cheapside, E.C.

1869† Goss, Tregenna Biddulph, M.R.C.S., 1, The Circus, Bath. *Hon. Loc. Sec.*

1891† Gostling, William Ayton, M.D., B.S.Lond., Barningham, West Worthing.

1889 Goullet, Charles Arthur, L.R.C.P.Lond., 2, Finchley road, N.W. *Council* 1902–5.

Elected

1890 Gow, William John, M.D.Lond., Physician-Accoucheur in charge of Out-patients, St. Mary's Hospital; 27, Weymouth street, W. *Council*, 1893-5-1901. *Board Exam. Midwives*, 1898-1900-1. *Trans.* 2.

1893† Gowan, Bowie Campbell, L.R.C.P.Lond., Raven Dene, Great Stanmore.

1893 Grant, Leonard, M.D.Edin., Hillside, New Southgate, N.

1902† Grech, Salvatore, M.D.Malta, Professor of Obstetrics in the University of Malta; Accoucheur and Gynæcologist and Teacher of Practical Midwifery at the Central Civil Hospital; 31, Strada Mezzodi, Valetta, Malta.

1894† Green, Charles Robert Mortimer, F.R.C.S.Eng., Major, Indian Medical Service, c/o Inspector-General of Civil Hospitals, Bengal.

1887 Greenwood, Edwin Climson, L.R.C.P., 19, St. John's wood park, N.W.

1863 *Griffith, G. de Gorrequer, M.R.C.S., L.R.C.P., 34, St. George's square, S.W. *Trans.* 2.

1879* Griffith, Walter Spencer Anderson, M.D. Cantab., F.R.C.S., F.R.C.P., Assistant Physician-Accoucheur to St. Bartholomew's Hospital; 96, Harley street, W. *Council*, 1886-8, 1893-5, 1901–3. *Hon. Lib.* 1896-7. *Board Exam. Midwives*, 1887-9. *Trans.* 10.

1888*†Grimsdale, Thomas Babington, B.A., M.B. Cantab., Surgeon to the Hospital for Women, and Medical Officer to the Liverpool Lying-in Hospital; 29, Rodney street, Liverpool.

1880 Grogono, Walter Atkins, M.R.C.S., L.R.C.P., Witham Lodge, 171, Romford road, Stratford, E.

1896† Groves, Ernest W. Hey, M.B., B.Sc., 16, Richmond Hill, Clifton. *Trans.* 1.

1881† Hair, James, M.D., Brinklow, Coventry.

Elected

1894 Hamilton, Bruce, L.R.C.P.Lond., Glenbrook, 5, Crediton Road, West Hampstead, N.W.

1887† Hamilton, John, F.R.C.S.Ed., Beechhurst House, Swadlincote, Burton-on-Trent.

1883* Handfield-Jones, Montagu, M.D. Lond., F.R.C.P., Physician-Accoucheur to, and Lecturer on Midwifery and Diseases of Women at, St. Mary's Hospital; 35, Cavendish square, W. *Council*, 1887-9, 1896-7. *Board Exam. Midwives*, 1894-6. *Hon. Lib.* 1900-3. *Hon. Sec.* 1902–5. *Trans.* 1.

1901 Handley, William Sampson, M.S., M.D.Lond., F.R.C.S.Eng., 51, Devonshire street, Portland place, W. *Council*, 1905. *Trans.* 2.

1892 Harold, John, M.B., B.Ch., B.A.O., 91, Harley street, W.

1877 Harper, Gerald S., M.B.Aber., 40, Curzon street, Mayfair, W. *Council*, 1894-5.

1898† Harper, John Robinson, L.R.C.P., Bear street, Barnstaple, Devon.

1878† Harries, Thomas Davies, F.R.C.S., Grosvenor House, Aberystwith, Cardiganshire.

1867* Harris, William H., M.D., Deputy Surgeon-General, Shirley, Parklands, Surbiton.

1880* Harrison, Richard Charlton, M.R.C.S., L.R.C.P., 33, Uxbridge road, Ealing, W.

1890† Hart, David Berry, M.D.Edin., Assistant Gynæcologist, Royal Infirmary, Edinburgh; 29, Charlotte square, Edinburgh. *Council* 1902–5.

1886† Hartley, Horace, L.R.C.P. Ed., Stone, Staffordshire.

1886 Hartley, Reginald, M.D. Durh., F.R.C.S.Ed., 68, Porchester terrace, Hyde park, W.

1893† Harvey, John Jordan, L.R.C.P. & S.Edin., The Aviary, Canning Town, E.

Elected

1880 Harvey, John Stephenson Selwyn, M.D.Durh., M.R.C.P., 1, Astwood road, Cromwell road, S.W.

1899† Hawes, Godfrey Charles Browne, L.R.C.P., Pangbourne, Reading.

1899*†Hawkes, Claude Somerville, L.R.C.P., Swansea place, Wickham Terrace, Brisbane, Queensland.

1893† Haydon, Thomas Horatio, M.B., B.C. Cantab., 22, High street, Marlborough.

1900 Hayford, Ernest James, M.D., c/o The Agent, Claude's Ashanti Goldfields, Ltd., Cape Coast Castle, Gold Coast, West Africa.

1901† Haynes, Edward James Ambrose, F.R.C.S.I., Weetalabah, Hay street west, Perth, Western Australia.

1880 Heath, William Lenton, M.D., 90, Cromwell road, Queen's gate, S.W. *Council*, 1891. *Trans.* 1.

1903† Heilborn, William Ernest, M.B., B.Ch.Cantab., 6, Walmer Place, Bradford, Yorks.

1892† Hellier, John Benjamin, M.D.Lond., Lecturer on Diseases of Women and Children, Yorkshire College; Hon. Obstetric Physician to Leeds Infirmary; 27, Park square, Leeds.

1890† Helme, T. Arthur, M.D.Edin., M.R.C.P., Hon. Surgeon for Women to the Northern Hospital for Women and Children, Manchester, 3, St. Peter's square, Manchester.

1867† Hembrough, John William, M.D., St. Nicholas Chambers Newcastle-on-Tyne.

1876* Herman, George Ernest, M.B., F.R.C.P., Consulting Obstetric Physician to the London Hospital; 20, Harley street, Cavendish square, W. *Council*, 1878-9, 1898-1901. *Hon. Lib.* 1880-1. *Hon. Sec.* 1882-5. *Vice-Pres.* 1886-7. *Board Exam. Midwives*, 1886-8. *Treas.* 1889-92, 1903-5. *Pres.* 1893-4. *Trans.* 33.

1903 Hicks, Henry Thomas, F.R.C.S.Eng., 24, St. Thomas's street, S.E.

Elected

1901 Hilliard, Francis Porteus Tyrrell, M.A., M.B.Oxon., Billericay, Essex.

1898 Hindley, Godfrey D., L.R.C.P.Lond., 11, Gwendolen avenue, Putney.

1886† Hodges, Herbert Chamney, L.R.C.P.Lond., Watton-at-Stone, Herts. *Trans.* 1.

1886† Holberton, Henry Nelson, L.R.C.P.Lond., East Molesey.

1891† Holman, Robert Colgate, M.R.C.S., Whithorne House, Midhurst, Sussex.

1864* Hood, Wharton Peter, M.D., 11, Seymour street, Portman square, W.

1896† Hopkins, George Herbert, F.R.C.S., 3, North Quay, Brisbane, Queensland.

1883* Horrocks, Peter, M.D., F.R.C.P.Lond., Obstetric Physician to Guy's Hospital; 42, Brook street, W. *Council*, 1886-7. *Hon. Lib.* 1888-9. *Hon. Sec.* 1890-3. *Vice-Pres.* 1894-6. *Pres.* 1901–2. *Trans.* 2.

1876 Horsman, Godfrey Charles, L.S.A., 22, King street, Portman square, W.

1883 Hoskin, Theophilus, L.R.C.P. Lond., 1, Amhurst park, N.

1884† Hough, Charles Henry, M.R.C.S., Ambleside, Westmorland.

1879† Hubbard, Thomas Wells, L.R.C.P., L.R.C.S., Barming place, Maidstone.

1901 Humphreys, Francis Rowland, L.R.C.P.Lond., 27, Fellows road, N.W.

1884*†Hurry, Jamieson Boyd, M.D. Cantab., 43, Castle street Reading. *Council*, 1887-9. *Vice.-Pres.* 1897-1900. *Trans.* 2.

Elected

1878* Husband, Walter Edward, M.R.C.S., L.R.C.P., Grove Lea, Lansdown, Bath.

1895 Huxley, Henry, L.R.C.P.Lond., 39, Leinster gardens, Hyde park, W.

1904 Illington, Edmund Moritz, Capt. I.M.S., L.R.C.P., 9, Alexander steeet, Westbourne gardens, W.

1894† Ilott, Herbert James, M.D. Aber., 57, High street, Bromley, Kent.

1901† Inglis, Arthur Stephen, M.D.Aber., 5, Pevensey road, St. Leonards-on-sea.

1902 Inglis, John, M.D., 18, Cornwallis gardens, Hastings.

1902† Ionides, Theodore Henry, M.B., B.S.Lond., 25, First avenue, Brighton.

1903 Ironside, Robert Adrian, M.D., C.M.Aber., Campbell House, Fitzjohn's avenue, N.W.

1884*†Irwin, John Arthur, M.A., M.D., 14, West Twenty-ninth street, New York.

1904 Ivens, Mary H. Frances, M.B., M.S.Lond., 25, Wimpole street, W.

1897 Jäger, Harold, M.B. Lond., 6, Darnley road, Royal crescent, W.

1890† James, Charles Henry, L.R.C.P.Lond., Major, Indian Medical Service; Lahore, Punjab, India.

1883*†Jenkins, Edward Johnstone, M.D. Oxon., 213, Macquarie street, Sydney.

1882* Jennings, Charles Egerton, M.D. Durh., F.R.C.S. Eng., Assistant Surgeon to the North-West London Hospital; Burke House, Beaconsfield.

1901*†Johnson, Edward Angus, M.B., B.S.Melb., L.R.C.P. Lond., "St. Catharine's" Prospect, South Australia.

Elected

1900 Johnson, Henry Heath Pochin, L.R.C.P., Ferry Hill, near Durham.

1868† Jones, Evan, M.R.C.S., Ty-Mawr, Aberdare, Glamorganshire. *Council*, 1886-8. *Vice.-Pres.* 1890-1.

1894 Jones, Evan, L.R.C.P. Lond., 89, Goswell road, E.C.

1902† Jones, Evan James Trevor, M.D.Brux., Ty-Mawr, Aberdare, Glamorganshire.

1895† Jones, George Horatio, M.R.C.S., Deddington, Oxon.

1894† Jones, John Arnallt, M.D.Durh., Heathmont, Aberavon, Port Talbot, Glamorganshire.

1887† Jones, J. Talfourd, M.B. Lond. Consulting Physician to the Breconshire Infirmary, St. David's, 11, Park road, Southborough.

1873† Jones, Philip W., M.R.C.S., L.R.C.P., River House, Enfield.

1886† Jones, William Owen, M.R.C.S., The Downs, Bowdon Cheshire.

1903 Jordan, John Furneaux, M.B., F.R.C.S., Surgeon to the Birmingham Hospital for Women, 9, Newhall street, Birmingham.

1884 Keates, William Cooper, L.R.C.P., 20, East Dulwich road, S.E.

1883† Keeling, James Hurd, M.D., 267, Glossop road, Sheffield.

1896 Keep, Arthur Corrie, M.D., C.M.Edin., Surgeon to Outpatients to the Samaritan Free Hospital; 14, Gloucester place, Portman square, W. *Council*, 1902-4.

1894 Kellett, Alfred Featherstone, M.B., B.C.Cantab., 142 Lewisham road, S.E.

1886 Kennedy, Alfred Edmund, L.R.C.P. Ed., Chesterton House, Plaistow, E.

1879 Ker, Hugh Richard, L.R.C.P.Ed., Tintern, 2, Balham hill, S.W.

Elected

1895† Kerr, John Martin Munro, M.B., C.M.Glasg.; Obstetric Physician to the Glasgow Maternity Hospital; 28, Berkeley terrace, Glasgow. *Trans.* 2.

1877*†Kerswill, John Bedford, M.R.C.P. Ed., Fairfield, St. German's, Cornwall.

1878† Khory, Rustonjee Naserwanjee, M.D., M.R.C.P., Medical Syndic, Bombay University; Honorary Physician, Bai Motlibai Obstetric and Gynæcological Hospital; Hormazd Villa, Khumballa hill, Bombay.

O.F.* Kiallmark, Henry Walter, M.R.C.S., 5, Pembridge gardens, Bayswater. *Council*, 1879-80.

1872* Kisch, Albert, M.R.C.S., 61, Portsdown road, W. *Council*, 1896-7.

1876*†Knott, Charles, M.R.C.P. Ed., Liz Ville, Elm grove, Southsea.

1889 Lake, George Robert, M.R.C.S., 177, Gloucester terrace, Hyde park, W.

1867* Langford, Charles P., M.R.C.S., Sunnyside, Hornsey lane, N.

1894† Lea, Arnold W. W., M.D., B.S.Lond., F.R.C.S., Lecturer on Midwifery and Diseases of Women, Owens College; 274, Oxford road, Manchester. *Council*, 1903-5. *Trans.* 2.

1901 Leahy-Lynch, Timothy, L.R.C.P., L.M.Edin., 2, Finsbury park road, N.

1884*†Lediard, Henry Ambrose, M.D., 35, Lowther street, Carlisle. *Council*, 1890-2. *Trans.* 1.

1903† Leicester, John Cyril Holdich, M.D., B.S., F.R.C.S. Eng., Captain, Indian Medical Service, c/o Messrs. Grindlay & Co., Calcutta.

1902† Lendon, Alfred Austin, M.D.Lond., Lecturer on Obstetrics in the University of Adelaide, North terrace, Adelaide, South Australia.

1897 Leslie, William Murray, M.D. Edin., 74, Cadogan place, Belgrave square, S.W.

Elected

1900* Levison, Hugo Adolf, M.D.(Columbia Univ.), L.R.C.P. Lond., 44, West 35th street, New York.

1885 Lewers, Arthur H. N., M.D. Lond., F.R.C.P., Obstetric Physician to, and Lecturer on Midwifery at the London Hospital; 72, Harley street, W. *Council*, 1887-9, 1893, 1901-3. *Board Exam. Midwives*, 1895-7. *Hon. Lib.* 1904–5. *Trans.* 13.

1902 Lewis, Ernest Wool, L.R.C.P., M.R.C.S., The Hermitage, Fulham Palace road, S.W.

1901† Littlewood, Harry, F.R.C.S., 25, Park square, Leeds. *Trans.* 1.

1894 Livermore, William Leppingwell, L.R.C.P. Lond., 52, Stapleton Hall road, Stroud green, N.

1899 Lockyer, Cuthbert, M.D., B.S.Lond., F.R.C.S., 117a, Harley street, W. *Council*, 1904–5. *Board Exam. Midwives*, 1905. *Trans.* 5.

1893† Logan, Roderic Robert Walter, M.R.C.S., Church street, Ashby-de-la-Zouch.

1893† Lowe, Walter George, M.D. Lond., F.R.C.S., Burton-on-Trent.

1878*†Lycett, John Allan, M.D., Gatcombe, Consulting Gynæcologist to the Wolverhampton and District Hospital for Women, Wolverhampton.

1902† Lynn, Edward, M.R.C.S., 638, Woolwich road, New Charlton, Kent.

1896† Lyons, A., M.B., Thames Ditton.

1871† McCallum, Duncan Campbell, M.D., Emeritus Professor McGill University; 45, Union avenue, Montreal, Canada. *Trans.* 4.

1890 McCann, Frederick John, M.D., C.M.Edin., F.R.C.S Eng., M.R.C.P., Physician to In-patients at the Samaritan Hospital; 5, Curzon street, Mayfair, W. *Council*, 1897-8. *Board Exam. Midwives*, 1904–5. *Trans.* 3.

Elected

1894† McCausland, Albert Stanley, M.D. Brux., Churchill House, Swanage.

1890 McCaw, J. Dysart, M.D., F.R.C.S., Wallington, Surrey. *Council*, 1898-1900.

1894† McDonnell, Æneas John, M.D., Ch.M. Sydney, Toowoomba, Queensland.

1896 M'Donnell, W. Campbell, L.R.C.P. Lond., Park House, Park lane, Stoke Newington, N.

1892† McKay, W. J. Stewart, M.B., M.Ch.Sydney, Australian Club, Macquarie street, Sydney, N.S.W.

1897† McKerron, Robert Gordon, M.B. Aberd., 1, Albyn place, Aberdeen. *Trans.* 2.

1900† Macan, Jameson John, M.A., M.D.Cantab., Crossgates, Cheam, Surrey.

1893 Maclean, Ewen John, M.D., F.R.S.Edin., M.R.C.P.Lond., Senior Gynæcologist to Cardiff Infirmary; 12, Park place, Cardiff. *Council*, 1900.

1899 Macleod, William Aitken, M.B., C.M.Edin., 9, Pembridge villas, Bayswater, W.

1886 McMullen, William, L.K.Q.C.P.I., 319A, Brixton road, S.W.

1878*† Macnaughton-Jones, H., M.D., M.A.O. (Hon. Causâ), F.R.C.S.I. & Edin., 131, Harley street, Cavendish square, W. *Trans.* 1.

1898 Macnaughton-Jones, Henry, M.B., B.Ch., 12, Sandwell mansions, West End lane, N.W.

1894† McOscar, John, L.R.C.P.Lond., The Shrubbery, Woking.

1899† Maguire, George J., M.B., B.Ch., Kew road, Richmond. *Trans.* 1.

1895† Maidlow, William Harvey, M.D.Durh., F.R.C.S.Eng. Ilminster, Somerset.

1884* Malcolm, John D., M.B., C.M., Surgeon to the Samaritan Free Hospital; 13, Portman street, W. *Council*, 1894-6. *Trans.* 2.

Elected

1871†*Malins, Edward, M.D., Obstetric Physician to the General Hospital, Professor of Midwifery at Mason College, Birmingham ; 50, Newhall street, Birmingham. *Council*, 1881-3. *Vice-Pres.* 1884-6, 1901-2. *Pres.* 1903–4.

1903† Malins, Herbert, B.A.Oxon., M.B.Edin., 283, London Road, West Croydon.

1868*†March, Henry Colley, M.D., Portisham, Dorchester. *Council*, 1890-2.

1887 Mark, Leonard P., M.D.Durh., 49, Oxford Terrace, Hyde-park, W.

1862*†Marriott, Robert Buchanan, M.R.C.S., Swaffham, Norfolk.

1887† Marsh, O. E. Bulwer, L.R.C.P. Ed., Parkdale, Clytha park, Newport, Monmouthshire.

1904 Marshall, James Cole, M.B.Lond., F.R.C.S.Eng., 1e, Maida Vale mansions, Maida Vale, W.

1890† Martin, Christopher, M.B., C.M.Edin., F.R.C.S.Eng., Surgeon to the Birmingham and Midland Hospital for Women ; 35, George road, Edgbaston, Birmingham. *Trans.* 1.

1883† Maurice, Oliver Calley, M.D.Heidelb., 75, London street, Reading. *Council*, 1888-90.

1899† Maxwell, John Preston, M.B.Lond., F.R.C.S., E.P. Mission, Engchhun, Amoy, China. *Trans.* 1.

1904 Maxwell, R. Drummond, M.D.Lond., 102, Oxford gardens, North Kensington, W.

1890 May, Chichester Gould, M.A., M.D.Cantab., Assistant Physician to the Grosvenor Hospital for Women and Children ; 59, Cadogan place, S.W.

1884† Maynard, Edward Charles, L.R.C.P.Ed., 39, Wynnstay gardens, Kensington.

1886 Mennell, Zebulon, M.R.C.S., 1, Royal crescent, Notting hill, W.

1898 Menzies, Henry, M.B.Cantab., 4, Ashley gardens, S.W.

Elected

1882 Meredith, William Appleton, M.B., C.M., F.R.C.S.Eng., Surgeon to the Samaritan Free Hospital for Women and Children; 21, Manchester Square, W. *Council*, 1886-8. *Vice-Pres.* 1891-3. *Trans.* 3.

1893† Michie, Harry, M.B. Aber., 27, Regent street, Nottingham.

1875*†Miles, Abijah J., M.D., Professor of Diseases of Women and Children in the Cincinnati College of Medicine, Cincinnati, Ohio, U.S.

1902 Milligan, Wyndham Anstruther, M.B., C.M.Aber., 104, Bethune road, N.

1876* Millman, Thomas, M.D., 490, Huron street, Toronto, Ontario, Canada.

1880† Mills, Robert James, M.B., M.C., 35, Surrey street, Norwich.

1892† Milton, Herbert M. Nelson, M.R.C.S., Kasr-el-Aini Hospital, Cairo, Egypt.

1869*†Minns, Pembroke R. J. B., M.D., Thetford, Norfolk.

1867* Mitchell, Robert Nathal, M.D., Brookwood, Hollington, St. Leonard's-on-Sea.

1877 Moon, Frederick, M.B.

1903 Moore-Ede, William Edward, M.B., B.C.Cantab., 64, Jesmond Road, Newcastle-on-Tyne.

1859† Moorhead, John, M.D., Surgeon to the Weymouth Infirmary and Dispensary; Weymouth, Dorset.

1895 Morison, Henry Bannermann, M.B. Durh., Lindley Lodge, Mottingham, Eltham, S.E.

1890 Morris, Charles Arthur, C.V.O., M.A., M.B., M.C. Cantab., F.R.C.S., Surgeon to the Grosvenor Hospital for Women and Children, 28, Chester square, S.W.

1883* Morris, Clarke Kelly, M.R.C.S., Gordon Lodge, Charlton road, Blackheath, S.E.

1899 Morris, Edwin Hugh Grant, M.B., B.C.Cantab., 47, Onslow gardens, S.W.

Elected

1893† Morse, Thomas Herbert, F.R.C.S., All Saints' green, Norwich. *Trans.* 1.

1896 Mugford, Sidney Arthur, L.R.C.P., 135, Kennington park road S.E.

1893 Muir, Robert Douglas, M.D., The Limes, New Cross road, S.E.

1896† Murphy, James Keogh, M.A., M.D., B.C.Cantab., 35, Princes square, Bayswater, W.

1885 Murray, Charles Stormont, L.R.C.S. and L.M.Ed., 85, Gloucester place, Portman square, W.

1896† Nariman, R. T., M.D. Brux., Parsi Lying-in Hospital, Bombay.

1902† Nariman, Temulfi Bhicafi, L.M.&F.Bombay, Bombay, India.

1892† Nash, W. Gifford, F.R.C.S., Senior Surgeon to the Bedford County Hospital, Clavering House, De Parys avenue, Bedford.

1902† Newland, H. Simpson, M.B.Adel.,F.R.C.S.Eng., Adelaide, South Australia.

1889† Newnham, William Harry Christopher, M.A., M.B. Cantab., Physician-Accoucheur to the Bristol General Hospital; Chandos Villa, Queen's road, Clifton, Bristol.

1895† Newstead, James, M.R.C.S., 9, York place, Clifton, Bristol.

1893† Nichol, Frank Edward, M.A., M.B., B.C. Cantab., 1, Ethelbert crescent, Margate.

1873† Nicholson, Arthur, M.B. Lond., 30, Brunswick square, Brighton. *Council*, 1897-9.

1904† Nicholson, Harry Oliphant, M.D.Edin., 20, Manor place, Edinburgh.

1876* Nix, Edward James, M.D., 11, Weymouth street, W. *Council*, 1889-90.

1903 Nolan, William, L.R.C.P.& S.I., L.M.Dubl., 28, Upper Phillimore place, Kensington.

1882† Norman, John Edward, M.D.Durham, Lismore House, Hebburn-on-Tyne.

Elected

1903† Nott, Arthur Holbrook, M.B.Durh., Major, Indian Medical Service, c/o Messrs. Grindlay & Co., Calcutta.

1903† Nuthall, Alexander Wathen, F.R.C.S.Eng., 35, Newhall Street, Birmingham.

1904† Odgers, Norman Blake, M.B., B.Ch.Oxon, F.R.C.S.Eng., South Devon and East Cornwall Hospital, Plymouth.

1888 Oliver, Franklin Hewitt, L.R.C.P. Lond., 2, Kingsland road, N.E.

1899† Osborn, Francis Arthur, L.R.C.P.Lond., Ennismore House, Dover.

1877† Osterloh, Paul Rudolph, M.D. Leipzic, Physician for Diseases of Women, Diaconissen Hospital; Wienerstrasse 8, Dresden.

1892 Owen, Samuel Walshe, L.R.C.P.Lond., 10, Shepherd's Bush road, W.

1902 Oxley, Alfred James Rice, M.D.Dubl., 7, Courtfield road, S.W.

1889* Page, Harry Marmaduke, M.D.Brux., F.R.C.S., 14, Grenville place, S.W.

1877* Paramore, Richard, M.D., 2, Gordon square, W.C.

1867*† Parks, John, M.R.C.S., Bank House, Manchester road, Bury, Lancashire.

1887 Parsons, John Inglis, M.D.Durh., M.R.C.P., Physician to the Chelsea Hospital for Women, 3, Queen street, Mayfair, W. *Trans.* 2.

1880 Parsons, Sidney, M.R.C.S., 78, Kensington Park road, W.

1904 Paterson, Herbert John, M.A., M.B., B.C.Cantab., F.R.C.S.Eng., 9, Upper Wimpole street, W.

1899 Paul, J. E., M.D., 26, Queensborough terrace, Bayswater, W.

1902 Payne, Edward Marten, M.B., C.M., 38, Chichele road, Cricklewood, N.W.

1882* Peacey, William, M.D., Rydal Mount, St. John's road, Eastbourne.

Elected

1894 Peake, Solomon, M.R.C.S., 228, Goldhawk road, Shepherd's Bush, W.

1899 Peck, Francis Samuel, M.R.C.S.Eng., Major, Indian Medical Service; 6, Harington street, Calcutta.

1871* Pedler, George Henry, M.R.C.S., L.R.C.P., 6, Trevor terrace, Rutland gate, S.W. *Council*, 1897-8.

1880*† Pedley, Thomas Franklin, M.D., Rangoon, India. *Trans.* 1.

1898 Penny, Alfred Gervase, M.A., M.B., B.C.Cantab.

1881† Perigal, Arthur, M.D., New Barnet, Herts. *Council*, 1892–3.

1893 Perkins, George C. Steele, M.D., 85, Wimpole street, W.

1879*† Pesikaka, Hormasji Dosabhai, 23, Hornby row, Bombay.

1894 Petty, David, M.B., C.M.Edin., 6, High road, South Tottenham, N.E.

1903† Philbrick, John Harold, M.B., B.Ch.Cantab. c/o Messrs. Grindlay & Co., Calcutta.

1879 Phillips, George Richard Turner, M.R.C.S., 28, Palace court, Bayswater hill, W. *Council*, 1891.

1882 Phillips, John, M.A., M.D. Cantab., F.R.C.P., Obstetric Physician to King's College Hospital, and Lecturer on Practical Obstetrics in King's College; 68, Brook street, W. *Council*, 1887-9, 1893. *Hon. Lib.* 1894-5. *Hon. Sec.* 1896-9. *Board Exam. Midwives*, 1892-4. *Vice-Pres.* 1900-3. *Chairman* 1905. *Trans.* 11.

1897 Phillips, Llewellyn C. P., M.B., B.C. Cantab.

1878* Philpot, Joseph Henry, M.D., 61, Chester square, S.W. *Council*, 1891.

1889† Pinhorn, Richard, L.R.C.P. Lond., 5, Cambridge terrace, Dover. *Council*, 1897-9.

1893 Playfair, Hugh James Moon, M.D.Lond., Assistant Physician, Hospital for Women and Children, Waterloo road; 7, Upper Brook street, Grosvenor square, W. *Council*, 1900.

Elected

1891* Pollock, William Rivers, M.B., B.C.Cantab., Assistant Obstetric Physician to the Westminster Hospital, 56, Park street, Grosvenor square, W. *Council*, 1895-7, 1902-4. *Board Exam. Midwives*, 1898-9.

1876* Pope, H. Campbell, M.D., F.R.C.S., Broomsgrove Villa, 280, Goldhawk road, Shepherd's Bush, W. *Council*, 1902-4.

1891† Pope, Henry Sharland, M.B., B.C.Cantab., Castle Bailey, Bridgwater.

1888* Popham, Robert Brooks, M.R.C.P. Edin., L.R.C.P.Lond., "Beancroft," Queen's road, Boscombe, Hants.

1903† Potts, William Alexander, B.A.Cantab., M.D.Edin., 160, Hagley road, Birmingham.

1893 Powell, Herbert Edward, M.R.C.S., Manor Lodge, Upper Clapton, N.E.

1901 Powell, Llewellyn, M.B., B.C.Cantab., 37, Brunswick gardens, Campden Hill, W.

1886 Prangley, Henry John, L.R.C.P. Lond., Tudor House, 197, Anerley road, Anerley, S.E.

1880* Prickett, Marmaduke, M.A.Cantab., M.D., Physician to the Samaritan Hospital; 27, Oxford square, W. *Council*, 1892.

1895 Priestley, R. C., M.A., M.B.Cantab., 81, Linden gardens, Bayswater, W.

1898† Purslow, Charles Edwin, M.D., M.R.C.P.Lond., Honorary Obstetric Officer, Queen's Hospital, Birmingham; 192, Broad street, Birmingham.

1876*†Quirke, Joseph, M.R.C.P. Ed., The Oaklands, Hunter's road, Handsworth, Birmingham.

1878† Rawlings, John Adams, M.R.C.P.Ed., 14, Northampton place, Swansea.

1897 Rawlings, J. D., M.B.Lond., Rose Hill House, Dorking.

1870* Ray, Edward Reynolds, M.R.C.S., 15a, Upper Brook street, W. *Council*, 1902-4.

Elected

1894† Rayner, Herbert Edward, F.R.C.S., Harcourt House, Camberley, Surrey.

1899† Rayner, David Charles, F.R.C.S.Eng., 9, Lansdowne place, Victoria square, Clifton, Bristol.

1860* Rayner, John, M.D., Swaledale House, Highbury quadrant, N.

1879 Read, Thomas Laurence, M.R.C.S., 11, Petersham terrace, Queen's gate, S.W. *Council*, 1892.

1879† Reid, William Loudon, M.D., Professor of Midwifery and Diseases of Women and Children, Anderson's College; Physician to the Glasgow Maternity Hospital; 7, Royal crescent, Glasgow. *Council*, 1899-1901-2.

1893† Renshaw, Israel James Edward, F.R.C.S.Edin., Ashton Grange, Cross street, Ashton-upon-Mersey.

1875*†Rey, Eugenio, M.D., 39, Via Cavour, Turin.

1890 Reynolds, John, M.D.Brux., 11, Brixton hill, S.W.

1872*†Richardson, William L., M.D., A.M., Professor of Obstetrics in Harvard University; Physician to the Boston Lying-in Hospital; 225, Commonwealth avenue, Boston, Massachusetts, U.S.

1889† Richmond, Thomas, L.R.C.P. Ed., 22, Holyrood crescent, Glasgow.

1871* Rigden, Walter, M.D. St. And., 16, Thurloe place, S.W. *Council*, 1882-3. *Trans.* 1.

1892 Roberts, Charles Hubert, M.D.Lond., F.R.C.S.Eng., M.R.C.P., Physician to Out-patients to Queen Charlotte's Hospital; Demonstrator of Practical Midwifery and Diseases of Women, St. Bartholomew's Hospital; 21, Welbeck street, Cavendish square. *Council*, 1897-9, 1905. *Board Exam. Midwives*, 1901. *Trans.* 4.

O.F.*† Roberts, David Lloyd, M.D., F.R.C.P., F.R.S. Edin., Consulting Obstetric Physician to the Manchester Royal Infirmary; and Lecturer on Clinical Midwifery and the Diseases of Women in Owens College; 11, St. John street, Deansgate, Manchester. *Council*, 1868-70, 1880-2. *Vice-Pres.* 1871-2. *Board Exam. Midwives*, 1900-4. *Trans.* 5.

Elected

1867* Roberts, David W., M.D., 56, Manchester street, Manchester square, W. *Council*, 1905.

1890† Roberts, Hugh Jones, M.R.C.S., Llywenarth, Penygroes, R.S.O., N. Wales.

1893 Roberts, Thomas, L.S.A., 152, Westbourne Grove, Bayswater, W.

1874* Robertson, William Borwick, M.D., St. Anne's, Thurlow park road, West Dulwich, S.E.

1892 Robinson, George H. Drummond, M.D., B.S. Lond., Assistant Obstetric Physician, West London Hospital; 84, Park street, Grosvenor square, W. *Council*, 1899-1900. *Board Exam. Midwives*, 1898-1900. *Trans.* 2.

1887 Robinson, Hugh Shapter, L.R.C.P. Ed., Talfourd House, 78, Peckham road, Camberwell, S.E.

1895† Robson, Alfred William, M.D. Brux., Kempstow House, 111, Park road, Aston, Birmingham.

1890† Robson, A. W. Mayo, F.R.C.S., 8, Park crescent, Portland place, W.

1876†* Roe, John Withington, M.D., Ellesmere, Salop.

1874*† Roots, William Henry, M.R.C.S., Canbury House, Kingston-on-Thames.

1903† Rose, Alexander Macgregor, M.B., Ch.B., 15, Victoria street, Aberdeen, N.B.

1904 Rose, Thomas, L.R.C.P., Chelsea Hospital for Women.

1893† Rosenau, Albert, M.D., Haus Rosenau (am Kurgarten), Kissingen, Bavaria. (*Winter*, Winter Palace, Monte Carlo.)

1884† Rossiter, George Frederick, M.B., Surgeon to the Weston-super-Mare Hospital; Cairo Lodge, Weston-super-Mare.

1884† Roughton, Walter, F.R.C.S., Cranborne House, New Barnet.

Elected

1882* Routh, Amand, M.D., B.S., F.R.C.P., Obstetric Physician and Lecturer on Midwifery at Charing Cross Hospital; 14a, Manchester square, W. *Council*, 1886-8, 1896-7. *Board Exam. Midwives*, 1893-5. *Hon. Lib.* 1898-9. *Hon. Sec.* 1900-3. *Vice-Pres.* 1904–5. *Trans.* 5.

O.F.* Routh, Charles Henry Felix, M.D., Consulting Physician to the Samaritan Free Hospital for Women and Children; 52, Montagu square, W. *Council*, 1859-61. *Vice-Pres.* 1874-6. *Trans.* 13.

1887*†Rowe, Arthur Walton, M.D. Dur., 1, Cecil street, Margate.

1886 Rushworth, Frank, M.D. Lond., 153, Finchley road, South Hampstead, N.W. *Council*, 1905.

1886† Rutherfoord, Henry Trotter, M.A., M.D. Cantab., Salisbury House, Taunton. *Council*, 1892-3. *Trans.* 1.

1866*†Saboia, Baron V. de, M.D., Director of the School of Medicine, Rio de Janeiro; 7, Rua dom Affonso, Petropolis, Rio Janeiro. *Trans.* 2.

1864*†Salter, John H., M.R.C.S., D'Arcy House, Tolleshunt d'Arcy, Kelvedon, Essex. *Council*, 1894-6.

1868* Sams, John Sutton, M.R.C.S., St. Peter's Lodge, Eltham road, Lee, S.E. *Council*, 1892.

1886† Sanderson, Robert, M.B. Oxon., 56, Brunswick square, Brighton.

1872 Sangster, Charles, M.R.C.S., 148, Lambeth road, S.E.

1903† Savage, Smallwood, M.B.Oxon., F.R.C.S.Eng., 133, Edmund street, Birmingham.

1877 Savory, Charles Tozer, M.D., 25, Grange road, Canonbury, N. *Trans.* 1.

1894† Savory, Horace, M.A., M.B., B.C.Cantab., Assistant Physician to Bedford County Hospital, 2, Harpur place, Bedford. *Trans.* 1.

1890 Schacht, Frank Frederick, B.A., M.D.Cantab., 153, Cromwell road, S.W.

Elected

1902 Scharlieb, Mary Ann Dacomb, M.D.Lond., M.S., B.S., 149, Harley street, W. *Council*, 1905.

1888 Scott, Patrick Cumin, B.A., M.B. Cantab., 38, Shooter's Hill road, Blackheath, S.E.

1882 Serjeant, David Maurice, M.D., 27, Peckham road, S.E.

1875 Seton, David Elphinstone, M.D., 1, Emperor's gate, S.W. *Council*, 1884.

1896† Sharman, Mark, M.B., C.M.Glas., Rickmansworth.

1894† Sharpin, Archdale Lloyd, L.R.C.P. Lond., Kimbolton house, Bedford.

1891 Shaw-Mackenzie, John Alexander, M.D. Lond., 42, Green street, Park lane, W.

1900† Shepherd, Thomas William, L.R.C.S.Edin., Castle Hill House, Launceston.

1902 Sikes, Alfred Walter, M.D., B.Sc.Lond., 40, Argyll road, Campden hill, W.

1902 Simson, Henry J. F., M.B., F.R.C.S.Ed., 80, Brook street, W.

1888† Sinclair, William Japp, Knt., M.D. Aber., Honorary Physician to the Southern Hospital for Women and Children and Maternity Hospital, Manchester; and Professor of Obstetrics and Gynæcology, Owens College, Manchester; 250, Oxford road, Manchester. *Council*, 1899-1902. *Vice-Pres.*, 1903-5. *Trans.* 1.

1881† Sloan, Archibald, M.B., 21, Elmbank street, Glasgow.

1876† Sloan, Samuel, M.D., C.M., 5, Somerset place, Sauchiehall street west, Glasgow.

1890† Sloman, Frederick, M.R.C.S., 18, Montpellier road, Brighton.

1903 Smith, Arthur Lionel Hall, L.R.C.P., M.R.C.S.Lond., 16, New Cavendish street, W.

1901 Smith, Guy Bellingham, M.B., B.S.Lond., F.R.C.S., 24, St. Thomas's street, S.E. *Trans.* 1.

Elected

1867* Smith, Heywood, M.D., 25, Welbeck street, Cavendish square, W. *Council*, 1872-5. *Board Exam. Midwives*, 1874-6. *Trans.* 6.

1875 Smith, Richard Thomas, M.D., Physician to the Hospital for Women, Soho square; 33, Wimpole Street, W.

1886† Smith, Samuel Parsons, L.K.Q.C.P.I., Park Hyrst, Addiscombe road, Croydon.

1899*† Smyly, William Josiah, M.D., F.R.C.P.I., 58, Merrion square, Dublin.

1899† Smithson, Oliver, L.R.C.P., New Bedford road, Luton, Beds.

1895 Soden, Wilfred Newell, M.B.Lond., Upcote, Mapesbury road, Brondesbury, N.W.

1868* Spaull, Barnard E., M.R.C.S., L.R.C.P., 1, Stanwick road, West Kensington, W.

1888* Spencer, Herbert R., M.D., B.S.Lond., F.R.C.P., Professor of Midwifery in University College, London, and Obstetric Physician to University College Hospital; 104, Harley street, W. *Council*, 1890-92. *Board Exam. Midwives*, 1896-7. *Hon. Sec.* 1898-1901. *Vice-Pres.*, 1902–4. *Editor*, 1903-5. *Trans.* 10.

1876† Spencer, Lionel Dixon, M.D., Brigade-Surgeon, I.M.S., Bengal Establishment [care of Messrs. Grindlay and Co., 55, Parliament street, S.W.].

1882* Spooner, Frederick Henry, M.D., Maitland Lodge, Maitland place, Clapton, N.E.

1876† Spurgin, Herbert Branwhite, M.R.C.S., 82, Abington street, Northampton.

1897 Stabb, Arthur Francis, M.B., B.C. Cantab., Assistant Obstetric Physician to St. George's Hospital, and Lecturer in Midwifery in the University of Cambridge; 132, Harley street, W. *Council*, 1899-1901. *Board Exam. Midwives*, 1903-5.

1894 Stevens, Thomas George, M.D., B.S. Lond., 8, St. Thomas's street, S.E. *Council*, 1902-3. *Board Exam. Midwives*, 1904-5. *Trans.* 2.

Elected

1884† Stevenson, Edmond Sinclair, F.R.C.S. Ed., Strathallan House, Rondebosch, Cape of Good Hope. *Trans.* 2.

1877† Stephenson, William, M.D., Professor of Midwifery, University of Aberdeen; 3, Rubislaw terrace, Aberdeen. *Council*, 1881-3. *Vice-Pres.*, 1887-9. *Trans.* 2.

1875*†Stewart, William, F.R.C.P. Ed., 26, Lethbridge road, Southport.

1884 Stivens, Bertram H. Lyne, M.D.Brux., 107, Park street, Grosvenor square, W.

1883 Stocks, Frederick, M.R.C.S., 421, Wandsworth road, S.W.

1894† Stott, William Atkinson, M.R.C.S., L.R.C.P. Lond., 2, Hillary place, Woodhouse lane, Leeds.

1866* Strange, William Heath, M.D., 2, Belsize avenue, Belsize park, N.W. *Council*, 1882-4.

1898† Sturmer, Arthur James, M.R.C.S., L.R.C.P., Lieut.-Col., Indian Medical Service, Madras. *Trans.* 1.

1884 Sunderland, Septimus, M.D., M.R.C.P., Physician to the Royal Hospital for Children and Women; 11, Cavendish place, Cavendish square, W.

1904 Swaffield, Walter H., M.D., F.R.C.S.Ed., 39, Weymouth street, Portland place, W.

1894 Swallow, Allan James, M.B., B.S. Durh., Taunton House, 404, Clapham road, S.W.

1896 Swan, Charles Atkin, M.B., B.Ch.Oxon., 4, Devonport street, Hyde Park, W.

1901 Swanton, James Hutchinson, M.D., M.Ch., 40, Harley street, W.

1893 Swayne, Francis Griffiths, M.A., M.B., B.C.Cantab., 140, Church road, Norwood, S.E.

1892† Swayne, Walter Carless, M.D.Lond., Obstetric Physician, Bristol Royal Infirmary; Professor of Midwifery in University College, Bristol; Mathon house. 56, St. Paul's road, Clifton. *Council*, 1903-5.

1888* Sworn, Henry George, L.K.Q.C.P. & L.M., 5, Highbury crescent, N.

Elected

1883 Tait, Edward Sabine, M.D., 48, Highbury park, N. *Council*, 1892-4. *Trans.* 1.

1880*†Takaki, Kanaheiro, F.R.C.S., 10, Nishi-Konyachō, Kio-bashika, Tokio, Japan.

1891 Targett, James Henry, M.B., M.S. Lond., F.R.C.S., Assistant Obstetric Surgeon to Guy's Hospital, 19, Upper Wimpole street, W. *Council*, 1895. *Board Exam. Midwives*, 1900-2.

1892* Tate, Walter William Hunt, M.D.Lond., Obstetric Physician to, and Lecturer on Midwifery and the Diseases of Women at, St. Thomas's Hospital; 32, Queen Anne street, Cavendish square, W. *Council*, 1895-7. *Board Exam. Midwives*, 1898-9. *Trans.* 2.

1900 Taylor, Frank Edward, M.A., M.B., F.R.C.S., Pathologist to Chelsea Hospital for Women, 11, Bentinck street, Cavendish square, W.

1890*†Taylor, John William, F.R.C.S., Surgeon to the Birmingham and Midland Hospital for Women; Professor of Gynæcology, Birmingham University; 22, Newhall street, Birmingham. *Council*, 1900-2. *Trans.* 4.

1892 Taylor, William Bramley, M.R.C.S., 145, Denmark hill, S.E.

1894† Tench, Montague, M.D. Brux., L.R.C.P. Lond., Great Dunmow, Essex.

1902† Tennant, John, M.A., M.B., C.M.Edin., Ashley, Doncaster.

1890† Thomas, Benjamin Wilfred, L.R.C.P. Lond., Welwyn.

1887† Thomas, William Edmund, L.R.C.P.Ed., Ashfield, Bridgend, Glamorganshire.

1901 Thompson, Charles Herbert, M.D.Dubl., 133, Harley street, W.

1867*†Thompson, Joseph, L.R.C.P.Lond., Surgeon to the General Hospital and Hospital for Women, Nottingham; 1, Oxford street, Nottingham. *Council*, 1896-8. *Trans.* 1.

Elected

1902 THORNE, MARY, M.D., 148, Harley street, W.

1873* TICEHURST, CHARLES SAGE, M.R.C.P.Edin., Petersfield, Hants.

1895† TINLEY, WILLIAM EDWIN FALKINGRIDGE, M.B., B.S.Durh., Hildegard House, Whitby.

1879† TIVY, WILLIAM JAMES, F.R.C.S. Ed., 8, Lansdown place, Clifton, Bristol.

1884 TRAVERS, WILLIAM, M.D., 2, Phillimore gardens, W.

1893† TRETHOWAN, WILLIAM, M.B., C.M. Aber., care of Dr. Mac-Williams, Perth, Western Australia.

1886† TUCKETT, WALTER REGINALD, M.R.C.S., Woodhouse Eaves, near Loughborough.

1898 TURNER, ARTHUR SCOTT, L.R.C.P.Lond., 39, Anerley road, Upper Norwood, S.E.

1865* TURNER, JOHN SIDNEY, M.R.C.S., Stanton House, 81, Anerley road, Upper Norwood, S.E. *Council*, 1893-4.

1891 TURNER, PHILIP DYMOCK, M.D.Lond., Sudbury villa, Ryde, Isle of Wight. *Trans.* 1.

1897 TWYNAM, GEORGE EDWARD, L.R.C.P.Lond., 31, Gledhow gardens, S.W.

1890 TYRRELL, WALTER, L.R.C.P.Lond., 104, Cromwell road, S.W.

1893 UMNEY, WILLIAM FRANCIS, M.D.Lond., Heatherbell, 15, Crystal Palace park road, Sydenham, S.E.

1904† VAN BUREN, ASA CLAUDE, M.B., B.S.Lond., Hazelmere, Ashford, Middlesex.

1903 VAUGHAN, ETHEL MAY, M.D., B.S.Lond., 21, Upper Wimpole street, W.

1874* VENN, ALBERT JOHN, M.D., 3, Hanover court, Hanover square, W.

1873* VERLEY, REGINALD LOUIS, F.R.C.P. Ed., Constitutional Club, W.C.

1903† VINCENT, GEORGE FOURQUEMIN, F.R.C.S.Edin., Rozelle, Maybury road, Woking.

Elected

1900* Vincent, Ralph Henry, M.D., B.S.Durh., 1, Harley street, W.

1894† Wagstaff, Frank Alex., L.R.C.P. Lond., Saffron Walden, Essex.

1898† Walker, Alfred, M.D., B.C., M.A.Cantab., 12, Lingfield road, Wimbledon.

1866*†Walker, Thomas James, M.D., Surgeon to the General Infirmary, Peterborough; 33, Westgate, Peterborough. *Council*, 1878-80.

1901† Wallace, Arthur John, M.D.Edin., Surgeon to the Hospital for Women, Liverpool; 1, Gambier terrace, Liverpool.

1870 Wallace, Frederick, M.R.C.S., L.R.C.P., Foulden Lodge, Upper Clapton, N.E. *Council*, 1880-2.

1883 Wallace, Richard Unthank, M.B., 148, Stamford hill, N.

1893† Walls, Willlam Kay, M.B. Lond., 14, St. John street, Manchester.

1879*†Walter, William, M.A., M.D., Surgeon to St. Mary's Hospital, Manchester; 20, St. John street, Manchester.

1867*†Walters, James Hopkins, M.R.C.S., Surgeon to the Royal Berkshire Hospital; 15, Friar street, Reading, Berks. *Council*, 1884-6. *Trans.* 1.

1898*†Ward, Charles, F.R.C.S.I., M.R.C.S.Eng., Pietermaritzburg, Natal, S. Africa.

1898† Watson, C. R., M.D.Brux., 5, Mount Ephraim road, Tunbridge Wells.

1899† Watson, Harry Jackson, M.D., C.M. Toronto, Baker Block, Winnipeg, Manitoba, Canada.

1884† Waugh, Alexander, L.R.C.P. Lond., Midsomer-Norton, Bath.

1894† Webb, John Curtis, M.A., M.B., B.C.Cantab., 6, Bina, Gardens, S.W.

1893† Webster, Thomas James, M.R.C.S., Brynglâs, Merthyr Tydvil.

Elected

1901† Weekes, Henry Holman, M.D.Brux., L.R.C.P.Lond., 21, Kidbrook park road, Blackheath, S.E.

1897† Weeks, Courtenay Charles, L.R.C.P.Lond., 9, Lewisham park, Lewisham, S.E.

1888* Weston, Joseph Theophilus, M.D.Brux., Civil Surgeon, Hissar, Punjab (care of Messrs. Thacker, Spink, and Co., booksellers and publishers, Government place, Calcutta).

1890* Wheaton, Samuel W., M.D.Lond., Physician to the Royal Hospital for Children and Women; 10, Rastell avenue, Streatham hill, S.W.

1890 White, Charles Percival, M.A., M.B., B.C.Cantab., 22, Cadogan gardens, S.W. *Council*, 1901.

1902† White, Clement, M.B., B.C.Cantab., Star hill, Rochester.

1903† Whitehouse, William H., M.D.Durh., Keston House, Aston road, Birmingham.

1902† Whitelocke, Richard Henry A., M.B., C.M.Edin., 6, Banbury road, Oxford.

1882 Wholey, Thomas, M.B. Durh., Room 79, Electra House, Moorgate street, E.C.

1901† Wigg, Henry Higham, M.D.Brux., L.R.C.P., F.R.C.S. Edin., 8, North Terrace, Adelaide.

1902 Willett, John Abernethy, M.B.Oxon., 36, Wimpole street, W.

1903 Willey, Florence Elizabeth, M.B., B.S.Lond., 1A, Devonshire street, Portland place, W.

1901 Willey, Frederick J. I., M.B., B.S., The Wych, Avenue road, Highgate.

1904† Williams, Edward Colston, M.B., B.S.Lond., 175, Brownlow hill, Liverpool.

1890 Williams, Reginald Muzio, M.D.Lond., 35, Kensington park gardens, W.

1899 Williamson, Herbert, M.A., M.B., M.R.C.P., Assistant Obstetric Physician, Royal Hospital for Women and Children; 45, Weymouth street, W. *Trans.* 2.

Elected

1898† Wilson, Claude, M.D.Edin., Belmont, Church road, Tunbridge Wells.

1892† Wilson, Thomas, M.D., B.S.Lond., F.R.C.S., Assistant Obstetric Physician at the General Hospital, Birmingham; 87, Cornwall street, Newhall street, Birmingham. *Trans.* 3.

1901† Wilson, Thomas George, M.B., Ch.M.Sydney, F.R.C.S. Edin.; 296, Ward street, North Adelaide, South Australia.

1900† Wingate, William Warburton, M.B., B.C.Cantab., 60, St. Andrew's street, Cambridge.

1886† Winterbottom, Arthur Thomas, L.R.C.P. Ed., c/o H. R. D. Pearson, Esq., King Island, Tasmania.

1877* Wintle, Henry, M.B., 33, Strawberry High road, Twickenham.

1893 Wise, Robert, M.D.Edin., 5, Weston park, Crouch End, N.

1887† Withers, Robert, M.R.C.S., Stenteford Lodge, Spencer terrace, Lipson road, Plymouth.

1890 Wornum, George Porter, M.R.C.S., 58, Belsize park, Hampstead, N.W.

1904† Worthington, Richard, M.B., B.C.Cantab., Gordon road, Lowestoft.

1876† Worts, Edwin, M.R.C.S., L.R.C.P., 6, Trinity street, Colchester.

1887† Wright, Charles James, M.R.C.S., Senior Surgeon to the Hospital for Women and Children, Leeds; Professor of Midwifery to the Yorkshire College; Lynton Villa, Virginia road, Leeds. *Council,* 1903-5.

1888*† Wyatt-Smith, Frank, M.B., B.C.Cantab., British Hospital, Buenos Ayres.

1882*† Young, Charles Grove, M.D., Berbice, Sea road, Bexhill-on-Sea.

Number of Fellows 609

CONTENTS.

	PAGE
List of Officers for 1905	v
Standing Committees	vii
List of Past Presidents	ix
List of Referees of Papers for 1905	x
Trustees of the Society's Property	xi
List of Honorary Fellows	xi, xii
List of Ordinary Fellows	xiii
Contents	lv
List of Plates	lxi
List of Illustrations	lxiii
Advertisement	lxiv
Hours of Attendance at Library	lxiv

January 6th, 1904—

Abscess in the Uterus, by Dr. W. F. Victor Bonney 2

Case of Abscess of the Uterus developing during the Puerperium; Rupture into the Peritoneal Cavity; Abdominal Section; Recovery, by Dr. A. W. W. Lea 7

Fibro-myoma of the Cervix Uteri removed by Abdominal Panhysterectomy, by Mr. W. A. Meredith 12

Report of the Pathology Committee on Mr. Meredith's specimen of Cervical Fibroid 14

Case of Sloughing of the Central Part of a Uterine Fibro-myoma shortly after Delivery, by Mr. J. D. Malcolm 15

Unsuspected Tuberculous Salpingitis and Pyosalpinx, by Mr. J. H. Targett 20

PAGE

Cyst in connection with the Right Fallopian Tube, arising probably from an Accessory Fallopian Tube, by Dr. R. Hamilton Bell . . . 21

I. Fibro-myoma of the Intra-abdominal Portion of the Round Ligament of the Uterus, by Dr. Herbert R. Spencer 26

February 3rd, 1904—

Annual Meeting 53

Unruptured Tubal Gestation, by Mrs. Scharlieb, M.D. 54

Chorionepithelioma of the Uterus with Secondary Growths in the Vagina, the Lungs, and the Liver, by Dr. G. F. Blacker . . . 55

Primary Cancer of the Right Fallopian Tube; Right Ovary Normal, by Dr. H. Briggs . . 60

Annual Meeting: the Audited Report of the Treasurer (Dr. G. E. Herman) . . . 62, 63

Report of the Honorary Librarian (Dr. Robert Boxall) 62

Report of the Chairman of the Board for the Examination of Midwives (Dr. Dakin) . . . 64

Alterations in the Laws 64

Election of Officers and Council for the year 1904 . 65

Annual Address of the President (Dr. Malins) . 67

March 2nd, 1904—

Two Specimens of Extra-uterine Fœtation, by Dr. Handfield-Jones 88

II. Two Cases involving the Question of the Site of Impregnation, by Mr. Harrison Cripps and Dr. Herbert Williamson 89

III. Two Cases of Abdominal Hysterectomy for Fibroids, complicated by Pregnancy; with specimens, by Mrs. Boyd, M.D. 106

Pregnant Fibroid Uteri removed by Operation, by Mr. Alban Doran 119

Degenerated Fibro-myoma weighing over seventeen pounds enucleated from the Broad Ligament nine hours before Delivery at Term, by Dr. Herbert R. Spencer 122

PAGE

April 6th, 1904—

Forty-one Cases of Puerperal Eclampsia treated by Thyroid Extract, by Lieut.-Col. A. J. Sturmer, I.M.S. 126

Tuberculous Disease of Cervix and Fallopian Tubes, by Dr. Walter Tate 138

Fibro-myoma of Uterus with extensive Carcinoma of Body of Uterus and Fibroma of Ovary, by Dr. Walter Tate 139

Two Cases of Diffuse Adeno-myoma of Uterus, by Dr. Walter Tate 141

Solid Mesenteric Tumour (Fibro-myoma) weighing thirty pounds, by Mr. Alban Doran . . 145

Ovarian Dermoid with a twisted Pedicle six inches in length, by Mr. J. Bland-Sutton . . 147

On a Case of Acute Axial Rotation of a Calcified Fibroid of the Uterus, by Mr. J. Bland-Sutton . 149

IV. Torsion of the Pedicle in Hydrosalpinx, and other Morbid Conditions of the Fallopian Tube, by Dr. R. Hamilton Bell 152

May 4th, 1904—

Report of the Pathology Committee on two specimens of Diffuse Adeno-myoma of the Uterus, shown by Dr. Walter Tate at meeting of the Society, April 6th, 1904 178

Two Cases of Enlarged Wandering Spleen forming Pelvic Tumours, by Mr. Frank E. Taylor . 179

Twin Monster, by Dr. Peter Horrocks . . 183

Fibro-myoma of the Uterus undergoing Sarcomatous Degeneration, by Dr. Peter Horrocks . . 184

Case of Adeno-myoma of the Uterus, by Mr. Frank E. Taylor 188

Uniovular Twins, by Dr. Cuthbert Lockyer . 191

Necrobiotic Fibroid removed from a recently delivered patient aged twenty-two, by Dr. J. S. Fairbairn . 194

Necrobiotic Fibroid, by Dr. Florence N. Boyd . 198

Lithopædion of fourteen years' duration successfully removed, by Dr. H. C. Bartlett . . 200

V. Hæmatoma and Hæmatocele; a Study of Two Cases of Early Tubal Pregnancy, by Mr. Alban Doran. 206

PAGE

June 1st, 1904—

Primary Carcinoma of both Ovaries, by Dr. CUTHBERT LOCKYER 229

Cancer of the Body of the Uterus simulating Fibroid in a Woman aged 36 years, by Dr. HERBERT R. SPENCER 235

Pregnancy in a Uterus with Fibroids; Panhysterectomy during Labour at the sixth month, by Mr. J. BLAND-SUTTON 238

Parovarian Cyst with Twisted Pedicle, by Dr. COMYNS BERKELEY 242

VI. Primary Hydatid Disease (Echinococcus) of the Fallopian Tube, by Dr. T. W. EDEN . . 243

VII. Notes on a Case of Hydatids of, or connected with both Ovaries, Right Broad Ligament, Liver, Omentum, Mesentery, and other parts, by Dr. C. J. CULLINGWORTH and Mr. H. H. CLUTTON, F.R.C.S. 254

July 6th, 1904—

Report of the Pathology Committee on Dr. Horrocks' Specimen of Fibro-myoma of the Uterus undergoing Sarcomatous Degeneration . . . 265

Report of the Pathology Committee on Dr. Herbert R. Spencer's Specimen of Cancer of the Body of the Uterus simulating Fibroid . . . 265

Further Note on a Case of Primary Tuberculosis of Cervix, by Dr. W. H. B. BROOK . . 265

Uterus with Carcinoma of the Body and Multiple Fibroids, by Dr. LEWERS . . . 266

Cystic Tumour of Uterus, by Dr. PURSLOW . 269

Tubal Mole, by Dr. PURSLOW . . . 271

Three Cases of Variation of the Posterior Fontanelle in Children, by Dr. A. W. SIKES . . 272

Fibro-myoma and Cystic Disease co-existing in the same Ovary, by Dr. WALTER TATE . . 273

Necrobiotic Uterus associated with recent Pregnancy, by Mr. ALBAN DORAN and Dr. HERBERT WILLIAMSON 274

Fibroma of the Ovary, by Dr. FRANK E. TAYLOR . 280

PAGE

VIII. On Sacs containing Fœtuses and lying free in the Peritoneal Cavity of a Rabbit, by Dr. M. S. Pembrey and Mr. G. Bellingham Smith . 283

Acute Inversion of the Uterus: Spontaneous Reposition, by Dr. Boxall . . 292

October 5th, 1904—

Section of the Wall of an Ovarian Dermoid showing Giant Cells, shown by Dr. Herbert Williamson 299

Carcinoma in the Muscular Wall of the Uterus secondary to Cancer of both Ovaries, shown by Dr. Cuthbert Lockyer 302

Cancer and Fibro-myoma co-existing in the Body of the Uterus, shown by Dr. Handfield-Jones . 305

Fibroid of the Uterus with Cystic Degeneration of the surrounding Tissues, shown by Dr. Handfield-Jones 307

IX. Certain details regarding the Operation of Cæsarean Section in Cases of Contracted Pelvis, based upon a series of Thirty Cases, by Dr. J. M. Munro Kerr 309

November 2nd, 1904—

Report of Pathology Committee on Dr. Purslow's Specimen of Cystic Tumour of Uterus . . 339

Report of Pathology Committee on Dr. Purslow's Specimen of a Case of Tubal Mole . . 340

Report of Pathology Committee on Dr. Frank E. Taylor's Specimen of Fibroma of the Ovary . 341

Case of Double Symmetrical Cystoma of unusual Origin and Connections, shown by Dr. Dauber . 341

Dermoid Cyst of the Ovary, removed by Abdominal Section five years after causing Obstruction to Labour, shown by Dr. Walter Tate . . 344

Pregnant Uterus with Cancerous Cervix removed by Pan-hysterectomy, shown by Mrs. Boyd, M.D. . 345

Fibroid of Broad Ligament, shown by Mrs. Boyd, M.D. 348

Carcinoma of the Ovary of unusual type, shown by Dr. Lockyer 349

A new Galvano-cautery Knife, shown by Dr. H. R. Spencer 353

PAGE

X. Three Cases of Cancer of the Cervix complicating Labour in Advanced Pregnancy, the Patients remaining well eleven, eight and a half, and eight years after High Amputation of the Cervix, by Dr. H. R. SPENCER 355

December 7th, 1904—

Report of Pathology Committee on Dr. Handfield-Jones' Specimen of Fibroid Tumour of the Uterus and Cystic Disease of the surrounding Tissues . 383

Report of the Pathology Committee on Dr. J. H. Dauber's Specimen of Double Symmetrical Cystoma of unusual Origin and Connections . . 384

Report of the Pathology Committee on Mrs. Boyd's Specimen of Fibroma of the Ovary . . 384

A Case of Abdominal Gestation, shown by Lieut.-Col. A. J. STURMER, I.M.S. . . . 385

XI. Three Cases of Intestinal Obstruction following Operations for Fibroid Tumour of Uterus, with special reference to the choice of Operation, by Dr. WALTER TATE 391

INDEX 411

ADDITIONS TO THE LIBRARY . . 431

PLATES.

PLATE		PAGE
I.	Fibro-myoma of the Cervix Uteri, removed by Abdominal Pan-hysterectomy (Mr. W. A. Meredith)	12
II.	Sloughing of the Central Part of a Uterine Fibro-myoma shortly after Delivery (Mr. J. D. Malcolm)	18
III.	Cyst in connection with the Right Fallopian Tube, arising probably from an Accessory Fallopian Tube (Dr. R. Hamilton Bell): Fig 1.—Wall of Cyst under low power showing Plicæ. Fig. 2.—Portion of Plica under high power, showing the Lining of definite Columnar Epithelium	24
IV.	Unruptured Tubal Gestation (Dr. Scharlieb)	54
V.	Chorion-epithelioma of the Uterus, with secondary growths in the Vagina, the Lungs, and the Liver (Dr. G. F. Blacker): Fig. 1.—The Uterus and Vagina laid open along the Primary Tumour in the Uterus and the Secondary Growths in the Peri-vaginal Connective Tissue Fig. 2.—Microscopic section of the Uterine Tumour showing a Syncytial Mass and numerous large Discrete Cells	58
VI.	Degenerated Fibro-myoma weighing over seventeen pounds, enucleated from the Broad Ligament nine hours before Delivery at Term (Dr. H. R. Spencer)	122
VII.	Cancer of the Body of the Uterus simulating Fibroid in a woman aged 36 (Dr. H. R. Spencer)	236
VIII.	Section of the Wall of an Ovarian Dermoid showing Giant Cells (Dr. H. Williamson)	300

PLATE PAGE

IX. Three Cases of Cancer of the Cervix complicating Labour in Advanced Pregnancy (Dr. H. R. Spencer):
Fig. 1, Case 1.—Squamous Epithelioma of Cervix. Sketch by author just before operation (natural size)
Fig. 2, Case 1.—Squamous Epithelioma of ervix, microscopic section under low power . . 359

X. Ditto:
Fig. 1, Case 2.—Squamous Epithelioma of Cervix, showing amount amputated
Fig. 2, Case 2.—Squamous Epithelioma of Cervix. Sketch by author just before operation (natural size) 362

XI. Ditto:
Fig. 1, Case 3.—Squamous Epithelioma of Cervix, showing amount amputated.
Fig. 2, Case 3.—Squamous Epithelioma of Cervix. Sketch by author of specimen which had been five years in spirit (natural size) . . 366

ILLUSTRATIONS.

PAGE

Fibro-myoma of the Intra-abdominal Portion of the Round Ligament of the Uterus (Dr. H. R. Spencer)
Fig. 1 41
Fig. 2 42

Ovarian Dermoid with a Twisted Pedicle six inches in length (Mr. J. Bland Sutton)
An Ovarian Dermoid containing light brown hair and grease; its twisted pedicle measured at the time of removal 15 cm. (6 inches) . . 148

Hæmatoma and Hæmatocele; a study of two cases of Early Tubal Pregnancy (Mr. Alban Doran)
Fig. 1, Case 1.—The dotted line shows the peritoneum of Douglas's pouch in normal position. The clot fills the pouch 212
Fig. 2, Case 2.—The dotted line shows the peritoneum completely displaced upwards by the clot . 220

Pregnancy in a Uterus with Fibroids: Pan-hysterectomy during Labour in the Seventh Month (Mr. J. Bland Sutton) 240

Primary Hydatid Disease (Echinococcus) of the Fallopian Tube (Dr. T. W. Eden) 246

Notes on a Case of Hydatids of, or connected with, both Ovaries, Right Broad Ligament, Liver, Omentum, Mesentery, and Other Parts (Dr. C. J. Cullingworth)
Right Ovary and Fallopian Tube from the preparation (No. 2379 B) in the Museum of St. Thomas's Hospital 256

New Galvano-cautery Knife (Dr. H. R. Spencer) . . 353

ADVERTISEMENT.

The Society is not as a body responsible for the facts and opinions which are advanced in the following papers and communications read, nor for those contained in the abstracts of the discussions which have occurred at the meetings during the Session.

20, Hanover Square, W.

LIBRARY AND MUSEUM.

20, Hanover Square, W.

Hours of attendance: Monday to Friday, 1.30 p.m. to 6 p.m.; Saturday, 9.30 a.m. to 2 p.m.: and in the evenings on which the Society meets, from 7.15 p.m. to 7.45 p.m.

AGNES HANNAM, F.R.S.L.,
Secretary and Librarian.

OBSTETRICAL SOCIETY

OF

LONDON.

SESSION 1904.

JANUARY 6TH, 1904.

EDWARD MALINS, M.D., President, in the Chair.

Present—40 Fellows and 3 visitors.

Books were presented by the Medical Society of London, Dr. Frommel, and Dr. Strassmann.

The following gentleman was admitted a Fellow of the Society:—Percival G. A. Bott, L.R.C.P.

The following gentlemen were elected Fellows of the Society:—Ernest C. Drake, L.R.C.P.Lond., M.R.C.S.Eng.; Walter H. Swaffield, M.D., F.R.C.S.Edin.; Richard Worthington, M.B., B.C.Cantab.

ABSCESS IN THE UTERUS.

By W. F. Victor Bonney, M.S., M.D.Lond., F.R.C.S.

The following case, which I believe to be one of retention of pus in one half of a subseptate uterus, presented features so peculiar and puzzling, that I think it is worthy of being placed on record in the 'Transactions' of this Society.

The patient, who was under the care of Dr. Humphrey, of Chichester, is 24 years of age, and was confined of her first and only child in November, 1901. There was nothing unusual about the labour.

In June, 1902, having been previously in good health, she was seized, just at the time of the period, with severe left-sided abdominal pain. Pelvic peritonitis was diagnosed, and she was sent to bed. The attack was a severe one, lasting over a period of two months.

At the end of this time she was sufficiently recovered to get about again, but never lost the pain in the left side, which was accentuated at each period.

In March, 1903, there was a recurrence of the attack, lasting for two weeks, when she again recovered, except for the continuance of the left-sided pain.

In the beginning of August, 1903, there was a still more severe return of the attack. The pain, abdominal rigidity, and tenderness were marked. The fever was continuous and high, and all the signs of severe pelvic suppuration were present.

I saw her, at Dr. Humphrey's request, on October 17th, the attack having then lasted for eight weeks, during which period two discharges of pus from the rectum were stated to have taken place, but without remission of the symptoms.

The diagnosis made was pyosalpinx, and I went to Chichester prepared to perform abdominal section.

On my arrival I went at once to see the patient. Abdominal examination was not feasible, as she had an antiseptic compress on, but by the vagina I was able to make out that an indurated mass filled the whole pelvis, in the midst of which was the uterus, immovably fixed, and obviously very considerably enlarged. The cervix was shortened, very high up, and somewhat soft to the touch.

On inquiry I found that she had missed the last two periods, having been previously regular, and one elicited the fact that opportunity for impregnation had occurred shortly before the onset of the attack eight weeks ago.

I examined the breasts, and found a copious amount of secretion in both of them, which was the more suspicious seeing that she had nursed her child for a very short period only.

I believed her to be pregnant, but inasmuch as there was very obviously some severe inflammatory condition as well, her temperature being 102° F. then, I decided to operate.

Assisted by Drs. Humphrey and Tallant I opened the abdomen.

There was a centrally situated tumour underlying a mass of dense adhesions, which, when I had with difficulty separated them, I found to be the uterus. The organ was enlarged to the size of about eight weeks' pregnancy. It was universally adherent, and I at first despaired of clearing it, but after some time I was able to expose the whole of its upper part by separating the bladder in front and finding a plane of cleavage behind between it and a sort of adventitious capsule of peritoneal adhesions. The lower part remained embedded in a dense inflammatory mass, partly cellulitic and partly perimetritic. Its contour was slightly asymmetrical, being larger and more obviously fluctuating on the left side, whilst on the right it was firmer and thicker walled.

I exposed both cornua, and found the relations of the

tube, round ligament, and ovarian ligament unaltered on either side. I satisfied myself of this with great distinctness, and it is a point on which, in view of what follows, I would lay particular stress. I traced each tube in turn into the dense mass of adhesions which filled the recto-uterine pouch, and I could indistinctly make out the ovaries lying embedded in the same mass. The tubes were not thickened or altered in any way, except for the adherent peritoneum covering them, nor did the ovaries appear to be enlarged. I could find no pus in the pelvis; nothing, indeed, but the dense mass of old adhesion of which I have spoken. I therefore decided that the case was one of pregnancy occurring in a totally adherent uterus, and lighting up a quiescent inflammation, the purulent results of which had already escaped *per rectum*.

The question now was what to do.

Believing her to be eight weeks pregnant, there were three courses open to me:

1. To close the wound and allow the pregnancy to go on or abort naturally. Against this was the fact that the patient was very ill, feverish, and in constant pain, and continual vomiting was rapidly reducing her strength still further. Moreover, the previous discharges of pus had not relieved the symptoms.

2. To close the wound and induce abortion or dilate the cervix and empty the uterus. Against this was the difficulty of dilating a uterus so high up in the pelvis and so extremely immobile. Moreover, the uterine wall appeared so thin and softened by inflammation that I realised that any extra-uterine instrumentation would be attended with grave risk, not to mention the dangers of an abortion, very probably incomplete, occurring in a uterus the centre of a large inflammatory mass.

3. To open the uterus from above, remove the eight weeks' gestation, and suture up the uterine wall.

This last alternative I decided to pursue.

Having packed off the rest of the peritoneal cavity I

incised the uterus in the middle line, when, to my surprise, not liquor amnii but a quantity of very foul pus mixed with old blood gushed out. Placing my finger in the cavity from which it came I found that I was inside one half of a subseptate uterus. The cavity extended towards the left as far as the left cornu; downwards it reached to what I took to be the level of the internal os, whilst on the right it was bounded by the non-distended right half of the uterus, the limits and outline of which could now be clearly made out. The wall of the cavity was soft, muscular, and vascular, but the lining membrane appeared to be completely destroyed and was represented by a soft ragged semi-necrotic layer. I stitched the opening of the cavity into the abdominal wound at its lower part and closed the upper part, and I inserted a couple of large rubber drain tubes through the hole so left. I would have removed the uterus but that it was impossible to clear its lower half from the inflammatory mass in which it was bedded.

The subsequent history of the case is that there was for many days a profuse purulent discharge from the wound, which had a strong fæcal odour, but the temperature never rose again, and at the present time she is convalescent. She has not yet menstruated, so that I am unable to tell you if any blood has escaped from the wound, but it is, I should say, extremely unlikely in view of the extensive destruction of the mucous membrane.

Such then is the history of the case, and I venture to think that it is interesting from several points of view.

The septate and sub-septate uterus is the rarest class of the congenitaly bipartite womb, and moreover it is the most difficult to recognise because the outward aspect of the double organ does not materially differ from that of the normal one.

It appears to me that the occlusion of one half and its subsequent distension with pus is probably to be explained by the assumption that her pregnancy occurred in the right half, and that in consequence of inflammation occur-

ring in connection with the separation and expulsion of the sympathetic decidua formed in the left half an adhesion of the median septum to the left wall of the uterus took place. The left half then occluded became distended with pus.

That septic changes even to the death of the patient may occur in connection with the sympathetic decidua formed in the non-impregnated half of a bipartite uterus is proved by the interesting case which Dr. Cleveland, in 1884, brought before this Society in which a woman was judged to have a uterus bicornis unicollis from the regular passage of a decidual cast some days after labour.

After her last pregnancy puerperal sepsis occurred, of which she died, and a post-mortem examination showed that the fatal infection had occurred in the non-impregnated half of a uterus, the type of which had been previously suspected.

Another point which I should wish to draw attention to is the extraordinary manner in which this case simulated pregnancy, so that even after the abdomen was opened a correct diagnosis was impossible.

That the case was one of pyometra in one half of a subseptate uterus I have no doubt. The absolutely unchanged relations of the structures about the uterine cornua leaves only one other possibility—namely, an abscess in the left uterine wall itself. But the shape of the cavity, its extension down to the level of the internal os, and its prolongation into the left cornu appear to me to negative this view quite apart from the very suggestive presence of blood mixed with its purulent contents, and the presence of a half uterus adjoining its right wall.

And finally as regards the treatment I adopted. This I feel in view of what I found to be undoubtedly justified.

Supposing, however, that my conjecture had proved well founded, and I had performed Cæsarean section on a uterus eight weeks pregnant. Would such an unusual procedure have been deemed the right one? I myself think so, and for the reasons I have told you, but it is on

this point particularly that I should like to hear the views of the Society.*

A CASE OF ABSCESS OF THE UTERUS DEVELOPING DURING THE PUERPERIUM; RUPTURE INTO THE PERITONEAL CAVITY; ABDOMINAL SECTION; RECOVERY.

By Arnold W. W. Lea, M.D., B.S.Lond., F.R.C.S.Eng.,

SURGEON TO THE NORTHERN HOSPITAL FOR WOMEN AND CHILDREN, MANCHESTER; ASSISTANT LECTURER ON OBSTETRICS AT THE VICTORIA UNIVERSITY OF MANCHESTER.

The development of an abscess in the wall of the uterus is an event of sufficient rarity to justify the publication of every undoubted instance. In the case here related the abscess developed during the puerperal period in a patient who was suffering from gonorrhœa at the time of delivery. Its existence was not suspected until the abscess ruptured into the general peritoneal cavity six weeks later. Abdominal section was then performed, and the condition recognised. The patient made a good recovery. The notes are as follows :

Mrs. H—, eight-para, was admitted into the Manchester Eye Hospital on May 1st, 1903, solely that she might be able to nurse her infant, which was suffering from acute gonorrhœal ophthalmia. She had previously enjoyed good health, and none of her other children had had ophthalmia. During the later months of pregnancy she had profuse yellow discharge from the vagina, but this had not been treated. Labour was easy and rapid. She

* Since writing this short communication Dr. Cullingworth has very kindly drawn my attention to a somewhat similar case which came under his care at St. Thomas's Hospital some years ago. A full report of his case, together with references from literature bearing on such occurrences will be found in the 'American Gynecological Transactions,' vol. xviii, 1893, p. 434.

was attended by a midwife. Severe ophthalmia developed in both eyes of the child on the third day. This speedily resulted in perforation of the cornea, and the sight of one eye was lost. During the puerperium her general condition remained good until the twelfth day. She then commenced to have severe hypogastric pain, but was able to get up. She was admitted into the hospital three weeks after delivery, and remained there nearly three weeks, getting up each day in the ward, but she states that she had continual abdominal pain during this time. No special record was kept of her condition, and the temperature was not recorded.

On May 17th, 1903, six weeks after the delivery, she was suddenly seized with intense pain in the lower part of the abdomen, accompanied by a severe rigor. The temperature rose to 103·6° and the pulse to 130. I saw her late in the evening. The patient lay with her knees drawn up, and had an anxious expression on her face. The temperature was 103·8°, pulse 132. The abdomen was extremely tender, and distended below the umbilicus. *Per vaginam* the uterus was bulky and soft, slightly mobile, anteflexed, and very sensitive. No definite swelling was felt in the region of the appendages or in the pouch of Douglas. Twelve hours later the patient's condition was much worse ; temperature was 104·2°, pulse 146, and respiration embarrassed. The abdomen was generally distended ; vomiting had also come on during the night, and was incessant, bilious in type. The tongue was dry.

Abdominal section was performed at 1 p.m. On opening the peritoneal cavity pus was seen around the uterus and among the intestines. On separating the coils of bowel lightly adherent to the fundus about four ounces of thick pus escaped. The finger passed into an abscess cavity in the posterior wall of the uterus, one inch below the fundus. This was irregular in shape, with edges soft and infiltrated, and during manipulation the finger slipped into the uterine cavity. The right ovary and tube were normal in size and apparently healthy. They had, how-

ever, been bathed in pus and were covered with recent yellow lymph. The left appendages were normal. As the uterus appeared to be otherwise healthy it was decided not to remove it. The right ovary and tube were taken away, as it was thought probable they had become infected. Throughout this procedure the peritoneal cavity was continuously irrigated with normal saline solution.

Posterior vaginal section was now performed, and a large-sized indiarubber tube passed from the lower part of the abdominal wound into the vagina. The abscess cavity in the wall of the uterus was packed with iodoform gauze, which also loosely filled the pouch of Douglas, and was brought out into the vagina. The abdominal wound was united by through and through silkworm gut sutures.

The patient was somewhat collapsed, but speedily rallied with the usual restoratives. Vomiting ceased almost immediately. The temperature varied from 100° to 101° for several days, becoming normal on the tenth day. The bowels acted well on the third day. The indiarubber tube was irrigated through into the vagina twice daily for a week and then once daily. The gauze was removed on the fourth day. The tube was gradually shortened from below, and at the end of three weeks was removed entirely from the vaginal wound. A recent examination (December 28th, 1903) shows that the uterus is normal in size, anteflexed, and movable. There is no swelling in the region of the appendages or pelvic peritoneum. Menstruation is regular, painless, and normal in amount. The abdominal scar is quite sound. The successful result of this case is largely to be attributed to the great care and attention bestowed on the after-treatment by Drs. McNabb and Wharton, House Surgeons to the Hospital.

It is well known that in cases of septic or gonorrhœal infection of the endometrium the organisms may invade the mesometrium, producing areas of leucocytic exudation. It is, however, very rare for these to terminate in the formation of an abscess of considerable size, although it is

not uncommon in cases of severe infection to find minute foci of suppuration in the uterine wall. In this instance there was no history of injury or placental retention to suggest any cause for the localisation of the infective focus. The occurrence of acute purulent ophthalmia in the infant is strong clinical evidence of the presence of gonorrhœa, and it is probable that the uterine cavity became infected after delivery. No bacteriological examination of the pus was made, and it is therefore possible that the infection may have been of a "mixed" type.

The slow development of the abscess is a noteworthy feature. The patient suffered from pain in the lower part of the abdomen, intermittent in character, and often severe for nearly four weeks. She was not, however, compelled to keep in bed. Perforation was immediately followed by very severe peritonitis.

The *symptoms* of abscess of the uterine wall must often be obscure. The condition is frequently complicated by intra-peritoneal inflammation which must render its recognition in many cases almost impossible.

Von Franqué* recently collected fifteen undoubted cases of abscess of the uterus, and mentions the following points as suggestive of this condition:

1. *Pyrexia.* This often commences suddenly, and is accompanied by rigors. The fever, however, presents nothing characteristic, but may continue indefinitely, especially in the gonorrhœal cases.

2. *Pain.* This is usually severe, paroxysmal in character, and felt in the lower part of the abdomen.

3. *Physical signs.* The uterus is enlarged, softened, and very sensitive. In some cases a rounded swelling has been detected, often situated asymmetrically, and accompanied by signs of pelvic inflammation.

It is obvious, however, that these symptoms are not very definite. A small infected myoma of the uterus would produce quite similar symptoms, and it would be in many cases impossible to distinguish between this and an abscess.

* 'Centralb. für Gynäkol.,' No. 20, 1902.

Abscess of the uterus usually terminates in perforation. According to von Franqué this most often takes place into the peritoneal cavity. In two of his cases the abscess perforated into the uterus, and in one case into the rectum.

The *prognosis* after perforation into the peritoneum is very grave. Seventy-five per cent. of the cases end fatally from general peritonitis unless operation is performed.

The *treatment* of abscess of the uterine wall must always be difficult. If the abscess is suspected any attempt to open and drain from the uterine cavity would be extremely dangerous. In the more chronic cases, and especially if multiple abscesses are present, vaginal hysterectomy would be the best course to adopt. If perforation occurs, as shown by symptoms of acute peritonitis, abdominal section should be carried out without loss of time. If the abscess is single and the uterus is otherwise fairly healthy, and if one or both appendages are normal, conservative measures should be adopted. If the uterine wall is extensively infiltrated with pus supra-vaginal or total hysterectomy should be performed. If it is decided to leave the uterus it is essential to provide sufficient drainage. This is best carried out by incision of the posterior *cul-de-sac*, and the introduction of a large-sized drainage tube, which allows of frequent irrigation. Gauze packing alone is not sufficient.

Dr. Amand Routh, alluding to the great rarity of pregnancy during uterine fixation, related a case of pregnancy occurring in a uterus entirely fixed by parametric exudation, resembling therefore in its essential aspects the case of Dr. Victor Bonney, as first diagnosed by him. In this case hæmorrhage occurred at about the twelfth week, and the temperature rose to 102°. It was impossible to draw down the cervix, but after rapid dilatation he was nevertheless able to empty the uterus by means of his fingers and a ring-forceps. He thought, therefore, that if Dr. Bonney's diagnosis had been correct he would have been able to deal with it *per vaginam*, though as the case turned out he had clearly adopted the best method. It was, however, not certainly a case of abscess in the half of a septate uterus, and might well be an abscess in the wall of the uterus similar to Dr. Arnold Lea's.

FIBRO-MYOMA OF THE CERVIX UTERI, REMOVED BY ABDOMINAL PAN-HYSTERECTOMY.

Shown by W. A. Meredith, F.R.C.S.

(With Plate I.)

The specimen, weighing three and a half pounds, afforded a characteristic example of the so-called intracervical or interstitial variety of growth involving practically the entire cervix, and producing considerable elongation of the cervical canal, which passed directly upwards for a distance of some four to five inches over the anterior surface of the tumour to the cavity of the uterus. This latter organ, seated on the summit of the tumour, was slightly enlarged, and showed two small nodules of fibro-myoma in its anterior wall. The cervical growth was undergoing degenerative change.

The patient from whom the specimen had been removed was a single woman 48 years of age, who had suffered for two years past from profuse menstruation, latterly complicated by increasing pressure symptoms of so severe a character as to seriously impede locomotion. The pelvis was found to be completely blocked by the growth, which extended upwards nearly to the umbilicus.

The tumour was removed through the abdomen by a complete hysterectomy. The opening through the vaginal vault was subsequently closed by a continuous suture of fine silk, and the walls of the sac, whence the growth had been enucleated, were laced together from below upwards by means of a running suture of No. 1 silk in order to arrest oozing and ensure the obliteration of the cavity; finally, the parts were covered in by uniting the divided edges of the pelvic peritoneum as in the ordinary retro-

DESCRIPTION OF PLATE I,

Illustrating Mr. W. A. Meredith's specimen of "Fibro-myoma of the Cervix Uteri, removed by Abdominal Pan-hysterectomy."

A, A. Anterior lip of cervix.
B, B. Posterior lip of cervix.
C. Capsule of cervical tissue.
D, D. Canal of cervix.

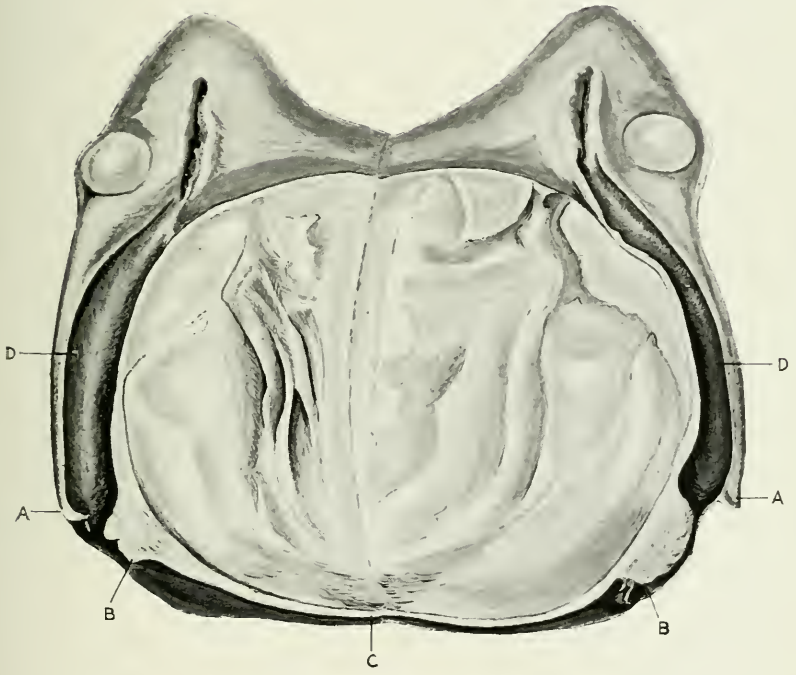

Illustrating Mr. W. A. MEREDITH's Specimen of Fibro-myoma of the Cervix Uteri.

Bale, Sons and Danielsson, Ltd.

peritoneal treatment of the uterine stump after supra-vaginal hysterectomy.

The patient made an uneventful and rapid recovery.

Mr. Alban Doran observed that Mr. Meredith's was a genuine case of fibroid of the cervix. In several well-known text-books the condition described and figured under that name was really fibroid in the connective tissue of the pelvis immediately behind the cervix, which was pushed upwards and forwards and flattened against the back of the symphysis. The surgery of these two varieties of fibroid disease was not the same; in the latter it might be possible to save the cervix and uterus.

Dr. Herbert Spencer said that the case appeared to be a genuine cervical fibroid; he was not sure, however, that it was interstitial. The interstitial fibroids which he had seen usually distended the affected lip of the cervix and thinned the opposite lip by stretching. In Mr. Meredith's case both lips were intact. He wished, however, to emphasise the fact that it was often impossible in a case which did not involve the vaginal portion to say whether the tumour grew from the lower segment of the body or from the cervix unless the uterus were removed entire (as in Mr. Meredith's case) and a section were made through the tumour and uterine cavity. He hoped the specimen exhibited would be treated in this way and submitted to the Pathology Committee, as it appeared to be a cervical fibroid; while he agreed with Mr. Doran in regarding some of the cases which had been published as originating not in the cervix but in the broad ligament or lower segment of the body. He had removed a tumour weighing 13 lbs., which appeared externally to grow from the supra-vaginal cervix, but which a section showed to grow from the lower segment. He did not agree with Mr. Doran that it was necessary to sacrifice the uterus in removing cervical fibroids. He had successfully removed six cervical fibroids by enucleation through the vagina, and thought that all cervical fibroids not much larger than a fœtal head should be removed in this way. He had only once operated by the abdomen for a cervical fibroid (weighing 8 lbs.), which he showed last year at the Society. The last cervical fibroid he had operated on by enucleation *per vaginam* weighed 1 lb. 6 oz., and was removed in twenty minutes from a patient suffering from severe anæmia, having less than 2,000,000 red corpuscles. She recovered well.

Report of the Pathology Committee on Mr. Meredith's Specimen of Cervical Fibroid.

In the natural state the tumour is obtusely oval with its longer axis in the transverse diameter. It is surmounted by the entire body of the uterus, in the anterior wall of which a small growth can be felt of the size of a small walnut. The entire growth is devoid of peritoneum, except at its extreme summit, and over an area about 2 cm. in width behind the left half of the corpus uteri. The cervical canal opens at the external os uteri on the front aspect of the lower pole of the tumour. An incision has been made through the front of the uterus and tumour, so as to divide the cervical canal and the cavity of the uterus into two equal halves. The uterus and tumour were then pinned out and hardened so as to present the cut surfaces on the flat.

The tumour was then seen to be entirely cervical. It lay in the posterior cervical wall with its convex anterior surface projecting forwards so as to elongate and arch the canal of the cervix in front of the growth. The tumour before hardening was pale, translucent, and œdematous, made up of reticular strands of tissue with definite arrangement into whorls; it was a typical "soft fibroid." The growth measured 14 cm. in the vertical and 19 cm. in the transverse diameter.

The body of the uterus is everywhere covered by peritoneum, the latter being incised, during the enucleation of the growth, at the junction of the latter with the uterus. The uterine body measures 6 cm. in the vertical and 7 cm. from cornu to cornu. Its wall is 2 cm. in thickness. In its anterior wall, immediately above the level of the internal os, is situated a circular fibroid with a diameter of 2 cm. The cavity of the uterus is 4 cm. in length. It is in no way altered by the large cervical growth.

The canal of the cervix is 10 cm. in length. It describes a wide curve on the front of the posterior cervical growth which projects towards it. It joins the cavity of

the body at the summit of the curve, and when taken with that cavity the two describe a double curve like the italic letter *f*. The anterior wall of the cervix is much thinned out in its lower 7 cm., measuring only ½ cm. where it bounds the cervical canal. The posterior lip of the cervix is of normal size and thickness; the anterior lip is thinned, drawn up, and represented by a slight thickening in the thinned-out anterior cervical wall.

In conclusion, the Committee are of opinion that this specimen may be correctly described as a cervical fibroid, that is to say, a fibro-myoma developing entirely in the cervix uteri and not originating either in the body of the uterus or in the pelvic connective tissue around the walls of the cervix.

G. F. Blacker.
J. S. Fairbairn.
Corrie Keep.
Cuthbert Lockyer.
W. A. Meredith.
G. Bellingham Smith.
J. H. Targett.
Alban Doran, *Chairman*.

A CASE OF SLOUGHING OF THE CENTRAL PART OF A UTERINE FIBRO-MYOMA SHORTLY AFTER DELIVERY.

Shown by John D. Malcolm, F.R.C.S.Edin.,
SURGEON TO THE SAMARITAN FREE HOSPITAL.

(With Plate II.)

Mr. Malcolm showed a specimen taken from a woman whose age was 32. She married in March, 1902, and miscarried in September of the same year. On October

25th, 1903, she had a stillborn child of about seven months' gestation. Her medical attendant was not present, but he delivered the placenta an hour later. Much blood was lost for five hours after delivery, and many clots were passed during the following four days. On the fifth day the vaginal discharge was very offensive, the patient's temperature was high, and she felt very ill. She gradually got better, and the discharge ceased, but much pain in the pelvis continued. Her doctor told her that this was caused by a tumour attached to the womb, which had been there since her delivery, and which would probably get all right. He ceased to attend after about four weeks. The pain increased very much as the patient tried to move about, and on December 10th she sent for another doctor with whom Mr. Malcolm saw her seven weeks after delivery, and she was admitted to the Samaritan Free Hospital the next day.

She had then a mass in the pelvis apparently between four and five inches in diameter, closely attached to the womb which lay to the right and behind. The swelling was always painful, but the slightest manipulation and every movement caused intense suffering. The uterine cavity measured just over two and a half inches in length, and there was no vaginal discharge. The temperature was 99·4° F. on admission to hospital, but next day it was normal, and it did not again rise until after the operation. Except for the presence of the mass attached to the uterus and some anæmia the patient seemed quite healthy. It was thought that possibly there might be an extra-uterine fœtation, but a diagnosis of inflamed fibro-myoma seemed to explain the conditions better.

On December 18th, 1903, the fifty-fourth day after delivery, as there was no improvement, the abdomen was opened, and a tumour, which was obviously an uterine fibroid was exposed. The most prominent part seemed to be covered by little, if anything, but peritoneum, and the uterus, which was well involuted, was attached to the back and right side of the growth. The body of the

uterus could be seen and felt standing well out from the growth, and they seemed to be slightly mobile on each other. The appearances suggested that the tumour was not very deeply buried in the wall of the uterus, and it was therefore decided to attempt to remove the fibroma and to leave the womb. An incision was made through the capsule, and enucleation was effected without much difficulty. Only one vessel bled sufficiently to require a ligature, all other hæmorrhage being controlled by sponge pressure. The tumour was, however, much more deeply placed than was expected, and in removing it the cavity of the uterus was laid freely open. A sound passed through the cervix made this quite certain. Nevertheless, hæmorrhage was unimportant, and the wound in the uterine wall was therefore closed. The deeper parts were brought together by a continuous catgut suture, but it was impossible to adjust the mucous surfaces accurately, and drainage into the uterine cavity was therefore free. The outer walls of the capsule, which had contained the tumour, were then inverted, but to do so it was necessary to shorten them considerably. This had the advantage of making their edges much thicker, and there was no difficulty in inserting Czerny-Lembert sutures, so that no part of the silk entered the cavity from which the tumour was removed. The necessary shortening of these flaps caused very little bleeding. Two small pedunculate fibroids, about the size of marbles, were also removed from the back of the uterus, and no other tumour was detected.

The patient made an uninterrupted recovery, there being a considerable vaginal discharge for the first few days.

The tumour appeared to be an ordinary fibroid and showed no sign of degeneration until it was incised. Then it was seen that nearly half an inch all round had the appearance of an ordinary living fibro-myoma, whilst the central part was a whitish-grey slough. There was no odour. After being in spirit a few days the colour

had all gone, but it was obvious that the external part had contracted more than the central. The appearance was very similar to that shown when a fibroid in the uterine wall has been incised, and kept in spirit, but then it is normal uterine tissue that retracts. There was no possibility of separating the central from the outer part except by using a knife.

Mr. Sampson Handley kindly made a section of the growth including part of the sloughed and part of the surrounding unaltered tissue (Plate II). The surrounding growth stained well with eosin and hæmatoxylin, and showed numerous muscular cells with well-stained nuclei. The sloughed part took on little stain and showed hardly any structure, no nuclei being visible. It was apparently in a state of mucoid degeneration. There was a well-marked line of demarcation between the sloughed and the healthy parts.

The condition was unique in Mr. Malcolm's experience. It did not seem that there was an ordinary sloughing due to septic influences absorbed from the uterine cavity. The growth was so close to the mucous membrane that contamination from this source must inevitably have induced an ordinary putrid slough of the whole tumour, and the death of the patient would probably have followed, because the growth was as near to the peritoneal as to the mucous surface.

The greater contractility of the outer portion of the growth suggested that the central part was more fibroid and less vascular, but probably the difference was due to a degeneration of the central sloughed tissue. Nevertheless the large number of muscular cells must have subjected the central part of the growth to considerable pressure, and Mr. Malcolm suggested that this, together with the diminution of the vascular supply caused by the involution of the uterus, might afford the most satisfactory explanation of the sloughing of the central part of the growth. According to this view the slough was aseptic, and it is probable that, if the patient had been kept

DESCRIPTION OF PLATE II,

Illustrating Mr. John D. Malcolm's specimen of Sloughing of the Central Part of a Uterine Fibro-myoma shortly after Delivery.

× 100. The section is taken at the junction of the sloughed central part and the healthy surrounding tissue. The former, on the right, shows no structure; the latter, on the left, shows the ordinary structure of a fibro-myoma uteri.

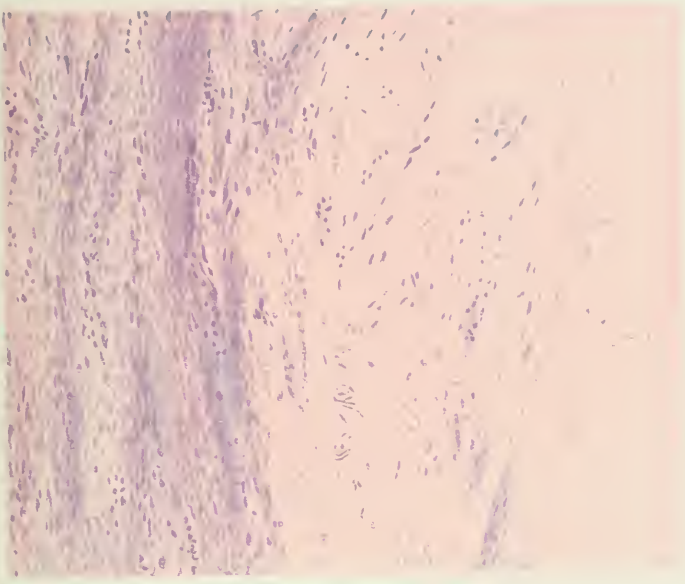

Illustrating Mr. John D. Malcolm's Specimen of Sloughing of the central part of a Uterine Fibro-myoma shortly after Delivery.

Photo-chromatic process. *Adlard and Son, Imp.*

absolutely quiet sufficiently long, the dead tissues would have been very slowly absorbed.

The advantages of enucleating the tumour and leaving the uterus in a recently married woman, thirty-two years of age, were obvious, but it should not be forgotten that the surgical completeness of the operation, which gave the patient the opportunity of becoming a mother, exposed her at the same time to the risks involved in the presence of a long scar in the uterine wall, and these could not be thought of without some anxiety if pregnancy occurred.

Dr. Herbert Spencer asked whether the tumour could not have been removed through the cervix by enucleation. He had treated several cases in this way after delivery or abortion. In two cases the patients had high fever at the time of the removal. All the cases had recovered well, and two of them had since had children naturally. In Mr. Malcolm's case the conditions may not have been suitable for enucleation *per vaginam;* but he thought if abdominal hysterectomy were performed for an infected fibroid the uterus ought to be wholly removed and not amputated.

Dr. Amand Routh agreed that Mr. Malcolm's method of removal by abdominal section was the correct one two months after labour. During the puerperium all sloughing or extruding fibroids should be removed *per vaginam*, and if other intramural fibroids were infected death could only be averted by pan-hysterectomy.

Mr. Alban Doran observed that thirty years ago no operation would have been performed, and in that case it was not improbable that the necrosed fibroid would have been expelled through the vagina. Had it been discharged entire the true condition would have been recognised, but if it had come away slowly and piecemeal in discharges, without the doctor's knowledge, the case might have been described as an instance of "absorption of a fibroid." Mr. Doran, remembering Dr. John Phillips's well-known case of disappearance of a fibroid after delivery, as well as Dr. Murdoch Cameron's views, would have liked to hear the opinions of those two authorities on Mr. Malcolm's case.

UNSUSPECTED TUBERCULOUS SALPINGITIS AND PYOSALPINX.

Shown by J. H. Targett, M.S.

The association of tuberculous salpingitis with a large fibroid tumour of the uterus requiring hysterectomy must be sufficiently rare to justify a short record of the case. The patient, aged 42, had been married twenty-five years, but was never pregnant. She had enjoyed excellent health throughout her life until the last six months, when she began to suffer from increasing menorrhagia. Menstruation had always been regular, but for the past three years it was more profuse than before, and latterly the periods lasted from ten to fourteen days. She had been under medicinal treatment for the menorrhagia during these three years with little avail, and the abdomen had now considerably enlarged. The patient was decidedly stout, and rather anæmic. A tumour could be felt rising out of the pelvis to the level of the umbilicus, and it presented the usual characters of a fibroid of the uterus; other organs appeared healthy. No pyrexia, sweating, or œdema; no physical signs of phthisis or ascites. Urine normal.

Abdominal hysterectomy was performed, and the operation proved difficult, partly owing to the obesity of the abdominal wall. The tumour was in the lower segment of the uterus, and was firmly held down by the round and broad ligaments. Moreover, there were numerous adhesions about the left uterine appendages, on which side the ovary was enlarged and cystic. On the right side there was also a cystic tumour of the size of a hen's egg, which was thought to be an ovarian cyst. Hence both uterine appendages were removed with the uterus by supra-vaginal amputation. There was nothing of note in the peritoneal cavity, no intestinal adhesions or matting

of the omentum. A good recovery ensued, and no symptoms of tuberculosis have appeared since the operation (five months ago), but the patient will be kept under observation.

On examining the specimen the following morning I was greatly surprised to find that the Fallopian tubes were thickened and nodular from tuberculous salpingitis, and that the supposed right ovarian cyst was in reality a tuberculous pyosalpinx, the ampullary extremity being distended with caseous pus. The right ovary was small, and adherent to the broad ligament. The uterine tumour was a typical fibro-myoma, and microscopic examination of the endometrium showed *no* evidence of tubercle.

Dr. Herbert Spencer said he had met with an interesting case of tubercular tubes complicating uterine fibroids. The patient had also recently developed angular curvature from a tubercular deposit in the spine. Acting on Sir Victor Horsley's advice he had removed the tubes. After a year's rest in bed the spine appeared to be solidified and the patient to be quite well. The rapid and marked improvement in the patient's symptoms and general condition after the removal of the tubes had surprised him.

A CYST IN CONNECTION WITH THE RIGHT FALLOPIAN TUBE, ARISING PROBABLY FROM AN ACCESSORY FALLOPIAN TUBE.

Shown by R. Hamilton Bell, M.A., M.B.Cantab., M.R.C.P.

(With Plate III.)

The specimen which I bring before the Society to-night I believe to be an example of a cyst arising in an accessory Fallopian tube. If this view be correct it shows that these cysts may have a clinical as well as a pathological interest, from the fact that it caused symptoms leading the patient to consult a doctor, first in Italy, and subse-

quently in England, and ultimately to consent to abdominal section.

The patient (C. A—), an Italian woman without any knowledge of English, was admitted to St. Thomas's Hospital, under the care of Dr. Cullingworth, in March, 1903. The specimen, which was removed by abdominal section, March 26th, was handed over to me for examination, and I am indebted to Dr. Cullingworth for permission to publish the result of my investigation.

The clinical history of the case was briefly as follows :—

Previous to this illness she had always been a healthy woman, had been married fifteen years, but never pregnant. Up to two years ago menstruation had been regular, but somewhat profuse. The first indication of any pelvic trouble was a change in the character of her periods, which recurred at much more frequent intervals, often twice a month, but with a scanty instead of a profuse flow. Concurrently with this she had pain in the right hypogastric and lumbar regions, and also severe headaches. Two years before admission she had been told by an Italian doctor that there was a small tumour in the right side. This had now enlarged so as to be a lump in the right iliac fossa appreciable to herself, and the pain had continued, and become more severe; she therefore came into hospital prepared to undergo an operation.

On palpation of the abdomen a smooth swelling could be felt on the right side, rising about two and a half inches above Poupart's ligament. It was cystic in nature, and appeared to be fixed. *Per vaginam* the swelling could be felt depressing the vaginal roof posteriorly and to the right. It was smooth, round, soft, elastic, and fixed, and was continuous with the swelling felt in the abdomen. The uterus was of normal size, but it was pushed forwards, and a little to the left, and its mobility was impaired.

At the operation, after adhesions had been separated, a large cystic mass was extruded from the wound. It con-

sisted apparently of two portions, a hydrosalpinx of the right Fallopian tube, and a large darker cyst, bound to the hydrosalpinx by strong adhesions. The ovary was seen lying separately. The hydrosalpinx and adherent cyst were removed together. The ovary was left *in situ*.

The parts removed were handed over to me for examination. I endeavoured first to find out whether there was any communication between the hydrosalpinx and the large cyst. The latter was placed above the tube, and was adherent to it for rather more than an inch along its upper border. I passed a fine probe down the tube, which was very slightly dilated at its uterine end, but could not make it pass from the dilated ampulla into the large cyst. Failing in this, I carefully separated the adhesions until the two were connected by a thin pedicle only, less than an eighth of an inch in diameter. Further efforts were then made to pass the probe, but without success. I then snipped through the pedicle, and separated the cyst, no drop of fluid escaping.

Whilst separating adhesions another small cyst was discovered tucked in between the hydrosalpinx and the large cyst, but communicating with neither.

The large cystic mass measured $3\frac{1}{2} \times 2\frac{1}{2} \times 2\frac{3}{4}$ inches. The wall was exceedingly thin at places, and translucent, especially at its upper pole, away from the Fallopian tube. When opened the contents were seen to be a clear yellowish fluid.

On opening the hydrosalpinx the fimbriæ could be seen radiating from a central band of fibrous tissue, which represented the abdominal ostium. The contents of the tube were a clear, thin, practically colourless fluid.

Various suggestions were made as to the origin of the large cyst, for example that it was a perimetric cystoma, but it seemed clear that microscopic examination of the wall was necessary before a definite opinion could be formed.

The first sections cut not proving very satisfactory further portions of the wall were removed. On examin-

ing the interior of the cyst slightly raised strands were seen, and on the supposition that these might possibly be plicæ, the sections were made to include them.

Sections were also cut horizontally through the wall, and stained by van Gieson's method to ensure that a small quantity of muscle which might be present should not be overlooked. The result of this section I may state at once. The fibrous tissue, stained red, very much predominated, but here and there were small areas stained yellow, with well-marked long nuclei, stained a dark yellowish brown, and there can, I think, be no doubt that these areas represented patches of muscular tissue which had escaped the general fibrosis.

The perpendicular section was stained with hæmalum and eosin. After several fruitless efforts a definite plica was discovered, and to prove that it was a ridge and not a fold serial sections were cut. The plica could be seen in every one of the series.

Detailed description of one section.—The wall is seen to consist mainly of fibrous tissue. At one or two places are a few fibrils with long nuclei which appear to be muscle fibres, but this is not nearly so obvious as in the section stained by van Gieson's method. No peritoneal lining can be made out on the outer surface of the cyst. (In regard to this I would point out that the wall was exceedingly thin and the sections consequently difficult to cut, so that it may be that the delicate peritoneum was lost in the preparation, or, on the other hand, that this large cyst growing *above* the Fallopian tube may have ruptured the peritoneum and entered the peritoneal cavity.)

The inner surface is lined throughout by epithelium, partly flattened, partly cubical, and in the neighbourhood of the plica, and over the plica itself, columnar in character. The plica is seen to consist of two or three folds of connective tissue, covered throughout with a columnar epithelium, and having at its base a large blood vessel. Close to the large plica is a smaller fold, with its epi-

DESCRIPTION OF PLATE III,

Illustrating Dr. R. Hamilton Bell's specimen of "Cyst in connection with the Right Fallopian Tube, arising probably from an Accessory Fallopian Tube."

Fig. 1.—Wall of cyst under low power showing plicæ.

Fig. 2.—Portion of plica under high power, showing the lining of definite columnar epithelium.

Fig. 1.

Fig. 2.

Illustrating Dr. R. Hamilton Bell's Specimen of Cyst in connection with the Fallopian Tube.

Bale & Danielsson, Ltd.

thelial covering more flattened, but with two distinct blood vessels at its base, an artery and a vein. Further down the section is a space lined on both sides by a columnar epithelium. This appears to me to be without much doubt a subplical space.

This perpendicular section, together with the horizontal one stained by van Gieson's method, seems to afford a fairly certain proof of the origin of this cyst from an accessory Fallopian tube. The points to which I would specially direct attention are (1) the muscle tissue found in the wall, (2) the epithelial lining, definitely columnar in places, and (3) and most convincing, the serial sections of a well-marked plica.

If this view be correct the specimen is interesting as showing that cysts arising in this manner may reach such a size as to present identical clinical phenomena with a hydro-salpinx of the main Fallopian tube.

Sections were also made of the wall of the smaller cyst mentioned above, but they were still more difficult to cut, and were not very successful. Although I personally believe its origin to be similar to that of the large cyst, I am not able to bring forward definite proof of this, which must remain only a conjecture.

The sections were all cut and stained for me in the clinical laboratory of St. Thomas's Hospital, and I must express my debt to Mr. Dudgeon, the superintendent of the laboratory.

The woman made a rapid and uninterrupted recovery from the operation.

FIBRO-MYOMA OF THE INTRA-ABDOMINAL PORTION OF THE ROUND LIGAMENT OF THE UTERUS.

By Herbert R. Spencer, M.D., B.S., F.R.C.P.,

PROFESSOR OF MIDWIFERY AND OBSTETRIC MEDICINE IN UNIVERSITY COLLEGE, LONDON; OBSTETRIC PHYSICIAN TO UNIVERSITY COLLEGE HOSPITAL.

(Received October 15th, 1903.)

(*Abstract.*)

The writer records a case of fibro-myoma of the intra-abdominal portion of the round ligament weighing six pounds, removed by abdominal myomectomy from a virgin 24 years old, who remains well after five years. He also gives a short account of the thirteen cases previously published.

A consideration of the facts furnished by these fourteen cases shows that fibroids in this situation occur usually in women over forty, the writer's case being the youngest (twenty-four) and Winckel's the oldest (seventy-six).

The tumours are more frequent on the right side than on the left (nine to five): in one case they were found in both ligaments, in another two tumours existed on one ligament.

They may occur in virgins; they do not tend to prevent pregnancy or to cause abortion. They do not influence menstruation, menorrhagia and dysmenorrhœa when present being due to uterine fibroids, which are associated in half the cases.

The tumours are subject to lymphangiectasis and to myxomatous and calcareous degeneration, and may cause trouble after the menopause.

They vary in size (from that of a nut to twelve kilogrammes), and may be pedunculated or sessile, intra-peritoneal or sub-peritoneal.

The pedicle may be the ligament itself, which is hypertrophied, or there may be a separate pedicle attaching the tumour to the ligament. Torsion of the pedicle may occur.

Special symptoms due to the tumour are often not marked; abdominal pain and stiffness, pain on walking, sacral pains, intestinal pains, and pressure on the bladder have been met with. In the writer's case the superficial abdominal reflex was much increased on the side of the tumour. Ascites is absent. The tumours, which vary in consistence, closely simulate ovarian, uterine, and broad-ligament growths.

The tumours should be removed as soon as they cause symptoms or attain a considerable size. The pedicle should be carefully tied, and, when possible, the ends of the ligament should be united. If a sac be left after enucleation it should be closed by suture or drained.

Two cases died (of eleven operated on), *i. e.* 18·18 per cent.; but the fatal cases occurred twenty years ago.

Tumours of the round ligament are rare, and the cases which have hitherto been recorded have been mostly extra-abdominal, arising in the termination of the ligament in the labium majus; a very few also have occurred in the inguinal canal. With regard to these extra-abdominal cases, it may be said that, at an operation for the removal of the tumour, there may sometimes exist a doubt as to whether the tumour is actually situated in the round ligament itself or in the adjacent structures, a doubt which could only be definitely settled by an extensive dissection which is impracticable in the living patient. I have removed a fibro-myoma from the inguinal canal which I believe originated in the round ligament. The tumour, of the size of a small walnut, occurred in the right inguinal canal, was removed through a small incision which healed by first intention, and proved to be a fibro-myoma on microscopic examination.

Tumours of the round ligament have mainly proved

to be of a fibroid nature, but Brainerd has recorded a case of cyst, Reboul a cystic fibro-myoma, E. Wilte a fibro-lipoma, Cullen and Bluhm cases of adeno-myoma, Gottschalk and Schramm cases of hæmatoma, A. Martin a case of abscess, Hausemann a case of sarcoma, Frigyesi a fibro-sarcoma, Walter a case of stone, and Fischer a dermoid.

The commoner extra-abdominal tumours will only incidentally be referred to in this paper as they offer fewer points of interest to gynæcologists than the intra-abdominal tumours, which closely simulate growths of the uterus, broad ligament, and ovary.

Of fibroids of the intra-abdominal portion of the round ligament I have found records of thirteen cases, all observed since 1875, the first having been described by the late Dr. Matthews Duncan in the 'Edinburgh Journal of Medical Science' for 1875—1876. The rarity of these tumours has prompted me to give notes of the following case, together with a brief description and review of the cases previously published:

C. M—, single, aged 24 years, having been born on December 8th, 1873, was sent to me on January 3rd, 1898, by Mr. J. M. Biggs complaining of a swelling in the abdomen for three months, and pain there for a year. Menstruation began at fourteen, and was always regular, lasting from five to six days, and being moderate in amount. The amount of the discharge had been rather less during the last year. There had always been pain at the periods. The patient's father died, when between twenty and thirty years of age, of consumption; her mother and her only two sisters and only three brothers were alive and well. There was no history of tumour in the family. Twelve months ago the patient had some pain in the right side of the abdomen above the iliac crest; this was thought to be due to indigestion. There was at that time some stiffness in walking. Three months ago she first noticed a slight swelling of the abdomen,

but did not pay much attention to it. She was surprised when told by her medical attendant that she had a tumour. The patient was admitted to University College Hospital, and looked in good health. The breasts were well developed. The heart and lungs were healthy. The abdomen was distended as by the uterus at the eighth month of gestation; the umbilicus was rather prominent. The superficial abdominal reflex was much more marked on the right side than on the left. The distension was due to a tumour reaching up for 9½ inches above the pubes, most prominent 2½ inches above the umbilicus. The abdominal girth was 30 inches (15½ inches on the right side, 14½ inches on the left). The distance of the umbilicus from the right anterior superior iliac spine was 6 inches, from the left spine 6½ inches. The tumour was ovoid in shape, of slightly uneven surface, the larger end upwards, the lower end somewhat to the left of the middle line. It was of firmish consistence, but appeared to fluctuate, and gave a superficial and deep thrill to palpation-percussion. The hymen was intact. The cervix could be felt a little to the right side of and behind the lower end of the tumour. The uterus was not enlarged apparently,* though the body itself could not be felt, but the tumour could be felt on the left and in front of the uterus apparently distinct from it (see Figs. 1 and 2). It was diagnosed as a multilocular cystic tumour of the ovary. The patient menstruated on the 11th to the 14th of June, and had some pain. The tumour was removed by me by abdominal myomectomy on June 16th, 1898. An incision six inches in length was made a little to the left of the middle line. The abdominal wall was very vascular. On opening the peritoneum it was found that the upper part of the tumour was covered by that membrane, having lifted up the anterior layer of the broad ligament so that the reflexion from the abdominal wall was about four inches above the pubes. The very vascular peritoneum

* It was, in fact, not enlarged.

over the tumour was incised transversely, the cut vessels ligated and the tumour enucleated without difficulty. In doing this several fine strands of fibrous tissue were torn across, and the tumour was found to be attached to the uterus by a pedicle about an inch in length and as thick as a lead pencil, which was the round ligament, situated symmetrically with the left round ligament, but much thicker. A silk pedicle-ligature was placed through the base of the right round ligament and adjacent part of the broad ligament, and tied in two portions, but, as some oozing occurred, it was necessary to apply a second ligature, which effectually controlled the hæmorrhage from the pedicle. There was still some oozing from the capsule from which the tumour had been enucleated which did not cease on sponge pressure. A strip of iodoform gauze was therefore inserted. The wound was then closed by silkworm gut through-stitches and silk fascia-sutures, except the lower inch through which the gauze projected. The operation lasted seventy-five minutes. The tumour weighed 6 lbs., and measured 8 in. × 6 in. × 5 in. To the naked eye and to microscopic examination it has the typical structure of a fibro-myoma. The pedicle is represented on the specimen by a tag of tissue only, as it was found necessary to cut the pedicle close to the tumour to avoid slipping of the ligature. The gauze was removed on the third day. The wound healed by first intention except the gauze track, which had completely healed by July 5th. On that day there was no tenderness anywhere, and the superficial abdominal reflex was distinctly more marked on the left side than on the right.

On July 9th the uterus was freely movable. *Per vaginam* a little nodule as big as the tip of the fore-finger could be felt at the site of the stump; this nodule moved with the uterus, and there was no induration of the tissues around. The highest temperature after the operation was 101·2° on June 17th, and 100° on the 18th and 19th. It returned to normal on June 23rd, and

remained practically normal till the patient's discharge. The highest frequency of pulse was 96 till June 24th and 80 after.

On July 10th the patient left the hospital quite well. I saw her on March 5th, 1899. She had been very well since the operation, but had had a little pain on and off in the right side if she walked further than usual or rode in an omnibus. She was regular, though she missed two periods in September and October following the operation. The uterus appeared quite normal and freely movable. The scar was quite sound.

I heard from Mr. Biggs on April 24th, 1901, that the patient continued well, but that she occasionally had neuralgic pains in the right side when tired; the scar was sound and menstruation regular. The patient continued well in October, 1903.

I now give an account of the thirteen cases already published:

Case 1 (J. Matthews Duncan, 'Edin. Journ. of Med. Science,' 1875–76, iii, 846).—Dr. Matthews Duncan exhibited a specimen of fibrous tumour of the round ligament. The tumour was of about the size and shape of a hen's egg. It lay quite free in front of the broad ligament. The right round ligament could be traced to its surface where it ended in the capsule. Its pedicle was small, thick, about a quarter of an inch broad. The structure of the tumour was that of a dense fibroid with numerous cretaceous portions near its centre, and having a fibrous capsule from the round ligament. Dr. Duncan remarked that practically such a tumour was interesting, as it might be mistaken for the ovary if felt during life.

Case 2 (Leopold, 'Archiv für Gynäkol.,' 1880, Bd. xvi, Ht. 3, p. 402).—Mrs. M—, aged 43, small and thin, had had two children, the last fourteen years before. There was no history of traumatism. She first noticed the tumour shortly after the last labour; in a short time

it attained the size of a fist, then remained stationary; now and again it caused a certain amount of pain. After a few years it appeared to diminish, and gave rise to no pain. In 1879 the tumour rapidly increased in size and painfulness. The "facies ovarica" of Spencer Wells was well marked. The lower abdomen, especially on the right side, was filled, even to the pelvis, with a half-solid, half-cystic tumour, in which were small and large fluctuating cavities. Menstruation was scanty, but fairly regular. The abdomen was filled, especially on the right side, by a firm mass as big as a full-term uterus, rising up to a point 8 cm. above the navel and passing on either side beyond the mammillary line. The thin walls allowed easy palpation of the tumour. Fluctuation was clear in places. The tumour could be moved a little upwards and laterally. Multilocular ovarian cystoma was diagnosed. An exploratory operation was performed, but the tumour was not removed, apparently owing to fear of hæmorrhage in separating the tumour. The patient died of "collapse" on the third day. At the necropsy peritonitis was found over the parts of the tumour lying under the linea alba. There were several strong adhesions to omentum and intestine. The ovaries were flattened, atrophic, and unconnected with the tumour. The tumour had the round ligament as a pedicle, which might easily have been tied. It weighed 12 kilogrammes. The cysts contained a thickish yellowish-brown fluid, and were lined with epithelium. Leopold styles the tumour "myoma lympangiectodes."

Case 3 (Winckel, 'Path. der Weibl. Sex. Organe,' Lief viii, 1881, p. 219).—The patient, aged 76, had several children. There was a tumour in each round ligament of the size of a filbert. The central end of the tumour was in each case 2 cm. from the point of insertion of the round ligament. The microscope showed the tumours to be leiomyomata.

Case 4 (Kleinwächter, 'Zeits. für Geburts. und Gynäkol.,' 1882, viii, pp. 181—186).—The patient, aged 44, had had five children. The tumour appeared a year ago as a result (?) of a blow on the abdomen, and developed slowly and progressively. The increase was greater at the periods. There was slight pain occasionally. The tumour was mobile, filled the pelvis, and was situated in front of the uterus. When one tried to raise it pain was caused in the position of Poupart's ligament. The uterus, immobile, was pushed to the right and behind the tumour. The left ovary was behind the tumour. Solid tumour of the right ovary was diagnosed. At the operation there were numerous adhesions to the parietal peritoneum and the great omentum. The pedicle was clamped and the abdomen drained. Secondary hæmorrhage occurred, and the patient died of septic peritonitis on the third day. At 2½ cm. from the origin of the round ligament was found a pedicle 1½ cm. long, as thick as a pencil, and terminating at its inferior extremity in the round ligament. It was a fibroma of the round ligament, and weighed 1750 grammes.

Case 5 (E. Hasenbalg, 'Zeits. für Geburts. und Gynäkol.,' 1892, Bd. xxiii, p. 54).—The patient, a virgin, 58 years old, had suffered as a girl from chlorosis. Menstruation began at sixteen, was at first scanty, irregular, and painless. Slight hæmorrhage occurred in her thirtieth year, then menstruation became normal every four weeks. The menopause occurred three years ago. For four or five years severe pain had occurred in the left lower abdominal region, and had increased for the last six months. A round hard tumour of the size of a goose's egg could be felt in the left lower abdomen reaching as high as the anterior superior iliac spine. The uterus was small, atrophic, movable. The diagnosis was "solid tumour of the left ovary." It was removed by ligature of the pedicle and suture of the space (the broad ligament) from which it was enucleated. Union took place by first intention.

Although this tumour was in the broad ligament it appears to have been a tumour of the round ligament.

Case 6 (P. Delbet and P. Héresco, 'Revue de Chirurgie,' 1896, p. 607).—The patient was 48 years old, the mother of two children, and had always had good health. The menses had always been regular, but scanty. In 1891 she accidentally noticed on turning in bed that the abdomen was large and had an unusual appearance. There was no pain. The increase in volume was slow. In 1893 stifling sensations supervened, which obliged the patient to leave off her corset, especially after meals. The abdomen (by its weight) began to give her inconvenience in 1894. Walking was painful. The tumour increased with much greater rapidity, and the general condition was altered. There was considerable loss of flesh and strength. In 1895 the tumour caused difficulty in stooping and rising and in lying on the back unless the knees were bent. Menstruation became irregular (the patient was near the menopause). For some time she had experienced pain in the right side. She was extremely thin, while the abdomen was enormously distended by the tumour, which gave the impression on inspection of a large ovarian cyst; but palpation showed that the tumour was solid, though some parts were softer than others. There was no ascites. The tumour descended into the small pelvis, forming a prominence to the right side and backwards. The diagnosis was a "solid tumour of the right ovary." The tumour was removed by enucleation. The pedicle was tied by chain ligature, which slipped; a continuous suture was then applied. Some serous cysts were also removed, and with them the right ovary and tubes. Apparently no drainage was employed. The lower part of the wound opened on the 21st day, and clots and serum escaped and a fistula was left. The patient recovered. The tumour weighed 10 lbs., and was a fibro-myoma with some myxomatous degeneration.

Case 7 (C. Martin, 'British Gyn. Journ.,' 1898, vol. xiv, p. 347).—The patient, aged 44, was seen on October 1st, 1897, for a rapidly growing abdominal tumour. Menstruation was regular every three weeks, lasting five days, and was very profuse and painful. The pelvis was found blocked with a large myoma. In addition there was a globular mass as big as a melon in the umbilical region, freely movable, but tethered to the uterus. At the operation the mobile mass was found to be a myoma of the round ligament very adherent to the bowel. Mr. Martin removed it, and then removed the myomatous uterus by pan-hysterectomy. The patient recovered. The myoma of the round ligament weighed $1\frac{1}{2}$ lb., and the myomatous uterus $2\frac{3}{4}$ lbs.

Case 8 (André Claisse, 'Bulletin et Mém. de la Soc. Anat. de Paris,' 1900, p. 21).—The patient, aged 31, complained of metrorrhagia and pains for several months; at the same time a tumour, manifestly uterine, developed and became very large. Dr. Paul Segond, having diagnosed uterine fibroids, performed total abdominal hysterectomy. The uterus contained a large number of myomata, some interstitial, others subperitoneal, sessile, and pedunculated; they had a softish consistence, but presented no peculiar features. The total weight of the mass removed was 2900 grammes. The left round ligament had a little tumour in it; it was absolutely independent of the uterus, separated from the point of implantation of the ligament by a distance of 12 mm. It was situated in the free upper border of the ligament with a base of implantation 11 mm. long; it had a spheroidal form, a smooth rosy surface, a firmish consistence, and measured 10 to 11 mm. in diameter. On section the usual white aspect of fibro-myomata was seen. The periphery was formed by a very thin shell, a little deeper in colour, continuous with the ligament, which opened out slightly so as to form a sort of cupola to the tumour.

Case 9 (Gustav Prang, "Inaugural Dissertation," Königsberg, 1900).—The patient was 47 years old. Menstruation began at twenty-one, and was irregular (intervals three weeks to two months), lasting eight days, and painless. In the first year it was free, but less abundant later. Married at twenty-one, she had five normal labours, the first at twenty-three and the last at thirty-two. The puerperium was always normal, except on the last occasion, when she had eight days' fever. For twenty years she had suffered from an inguinal hernia, and for ten years she had had sacral pains, which of late extended to the feet. About a year ago she noticed swelling of the abdomen, and about six months ago a hard resistance in the lower abdomen. This was painful to pressure, the pain spreading to the sacral and epigastric regions. On palpation was found on the right side of the abdomen a hard tumour as large as a man's head, freely movable, and by its side ("daneben") the uterus sinistroverted. The left ovary was felt of normal size and mobility, and the uterus could be distinguished from the tumour. The right external abdominal ring could be well felt; in front of it lay a tumour of the size of an apple, which could be pushed fairly easily into the canal. Percussion note dull. To the large tumour was attached a smaller one by a thin pedicle. *Diagnosis:* Tumour of the right ovary; slight inguinal hernia. The tumour was removed by abdominal section and enucleation. The pedicle was of the size of a small lead pencil. The large tumour sent a prolongation into the inguinal canal, which simulated a hernia. The tumour was adherent to the right side of the abdominal wall by broad vascular adhesions. The ligament could not be separated from the tumour. The hinder part of the tumour was not covered with peritoneum, but that towards the right inguinal canal was. The cavity from which the tumour was enucleated was closed with continuous catgut stitches. There was a myoma of the size of an apple in the fundus uteri. Microscopically the

tumour was a fibro-myoma. The patient recovered well.

Case 10 (G. Baermann, 'Central. für Gynäkol.,' 1901, p. 1280, and "Inaug. Dissertation," München, 1901).—The patient, 52 years old, who had had two children and an abortion, began to menstruate at nineteen years, at first every three months, later every five to seven weeks. A year ago she noticed a protrusion of the right abdominal region. Examination showed a right-sided tumour of about the size of a man's head, fairly movable and firm; to the left of this lay the uterus, of about the size of the fist. On moving the tumour the uterus was moved, but the tumour and uterus were distinct. The diagnosis was pedunculated subserous uterine myoma or solid ovarian tumour. At the operation it was found that the tumour sprang from the right round ligament. It weighed 1300 grammes. Microscopically it was a fibro-myoma with myxomatous degeneration. The patient recovered.

Case 11 (Michaux, 'Bulletin et Mém. de la Soc. de Chir. de Paris,' 1901, p. 165).—The patient was 50 years old. The tumour was removed by operation. There was a second fibroid of the size of a nut in the round ligament, and the uterus itself contained a fibroid of the size of an orange. The right tube and ovary were intact and distinct from the tumour. The tumour rose above the umbilicus nearly to the left hypochondrium. The pedicle (as thick as the thumb) was twisted. The tumour, in consequence, was inflamed, its peritoneum thickened and adherent—above to the mesentery and loops of small intestine, below to the sigmoid flexure and appendices epiploicæ. The operation was easy. The result is not given, the operation having been done on the day when the specimen was exhibited. The tumour was probably right-sided.

Case 12 (J. A. Amann, jun., 'Monats. für Geburts. und Gynäkol.,' 1901, p. 772).—The patient was 41 years old, a virgin. For a year she had had tenesmus-like pains in the intestine and pressure on the bladder, and occasionally stomach-ache. Menstruation was regular and quite painless. There was an irregular tumour reaching up to the navel. The uterus was enlarged by fibroids to the size of a fist. To the right of the uterus was a large rounded tumour connected with the uterine wall by a slender bridge only. Total abdominal hysterectomy was performed. The patient recovered. Myxomatous degeneration had occurred in parts of the tumour.

Case 13 (Oscar Nebesky, 'Monats. für Geburts. und Gynäkol.,' 1903, p. 443).—The patient, aged 43, had had four children and two abortions. Menstruation was regular, lasting one to four days, slight in amount. A year ago there was metrorrhagia, which ceased on the removal of two polypi (? fibroid) from the uterus. There had been pain and pressure on micturition for two months, also slight pricking pain in the left lower abdomen. On the left side above the pubes, was felt a firm knobby tumour, somewhat movable; bimanually it could be separated from the retroflexed uterus, but was fixed to the side of the uterus by a palpable pedicle. The diagnosis was subserous uterine myoma. On opening the abdomen an elastic firm tumour of the size of a fist was found growing from the left round ligament 2½ cm. from its uterine end. It was completely intra-ligamentary. The pedicle was tied in two places and cut, the tumour enucleated, the bed of the tumour closed with a few sutures, and the abdomen closed in three stages. The patient was discharged well on the 23rd day.

The age of the patients is given in thirteen cases—my own case is the youngest, twenty-four; Claisse's case was only thirty-one; of the others seven were over forty, three over fifty, and Winckel's was seventy-six. It would

appear then that fibroids of the intra-abdominal portion of the round ligament, like those of the uterus, mostly occur in women over forty years old, though their occurrence in young women under twenty-five does not appear to be relatively so rare as it is in the uterus. Saenger has published a case of tumour in the extra-peritoneal portion in a woman of twenty-two, and Fischer one in a woman of twenty-four. Saenger quotes Nicolaysen as having observed tumours in the extra-peritoneal portion of both round ligaments of a girl four and a half years old, who also had a double hydrocele of the processus vaginalis. The tumours in this young child were described as resembling flat beans, and Saenger playfully observes that perhaps they would bear fruit, especially as a truss was ordered. From Saenger's description it appears doubtful whether they were tumours at all, and there is no evidence that they were fibroids. The original communication is in Norwegian, and I have not been able to read it.

The tumours occurred nine times on the right side and five times on the left (one patient having both ligaments affected). The greater frequency with which the right ligament is affected is noteworthy, and is also met with in the extra-peritoneal cases. I am unable to suggest the cause. Seven of the patients had had children; two had also miscarried; one patient was single, and three were virgins. The statement of Delbet and Héresco that all the tumours had developed in multiparæ is therefore no longer true. In three cases there is no information as to pregnancy, but all the patients married appear to have borne children, so that we may conclude that tumours in this situation do not tend to prevent pregnancy or to cause abortion. The tumours do not seem to influence menstruation. In Cases 4 and 5 it was normal, in Case 2 scanty, in Case 10 irregular but painless, in Case 14 painful. Although metrorrhagia and painful menstruation are mentioned, in several of the other cases those symptoms appear to be due to the co-existence of

uterine fibroids, which were present in no less than seven of the fourteen cases. Kleinwächter's case is said to have increased in size at the periods.

The tumour.—In all the cases the tumour was a fibroid. In Leopold's case lymphangiectasis had occurred; in Delbet and Héresco's, and in Baermann's case mucous degeneration; in Matthews Duncan's calcareous degeneration. In none of the cases were true cysts found such as those described by Cullen and Bluhm in extra-peritoneal cases. The tumour may be pedunculated or sessile, and be freely covered with peritoneum, or raise up the anterior layer of the broad ligament. In size it varies from that of a nut (Claisse and Michaux's cases), or hen's egg (Matthews Duncan's case) to six pounds (as in my own case), ten pounds (Delbet and Héresco's case), or even twelve kilogrammes (Leopold's case). Two tumours were found in the same ligament by Michaux. The pedicle (which is usually the ligament itself) was found in my case, and in Cases 1, 4, 9, to be of the size of a lead pencil, being therefore hypertrophied. In Michaux's case it was twisted and as thick as a thumb.

Symptoms—It is difficult to estimate the symptoms, inasmuch as more than half the cases were complicated by *uterine* fibroids. As shown above, menstruation does not appear to be directly affected. Besides the general discomfort the tumour, when large, appears to cause local pain and stiffness and pain on walking, and sacral and intestinal pain and pressure on the bladder. In my own case the symptoms were not marked. Hasenbalg's case shows that trouble does not always cease at the menopause. The *consistence* is sometimes stated to be hard, firm or firmish. In other cases the softness of the tumour in places was due to myxomatous degeneration or dilated lymphatics. In others the tumour was elastic and even fluctuating although solid, a condition not uncommon in *uterine* fibroids.

The relative positions of the tumour and uterus are not very fully given in most cases. It would appear from

the published notes that the uterus is usually pushed to the opposite side. The tumour is of course in front of the uterus and gives the uterus a tilt not easy to describe in words. The accompanying diagram made from sketches

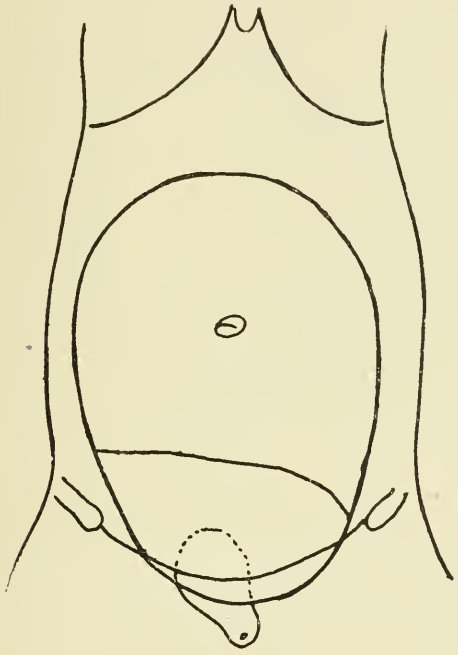

Fig. 1.

taken just before and after the operation shows the relations in my case.

In no case is there mention of the presence of ascites, which is so common in *ovarian* fibroids. The case of "fibro-sarcoma," published by Frigyesi,* had from eight to ten litres of ascitic fluid. In this case the evidence of

* 'Centrabl. für Gynäkol.,' 1902, p. 830.

sarcoma is not given; it may possibly have been a case of fibroid. It is to be hoped that a full account of the microscopic appearances and of the after-history in this case will be published, as the presence of ascites, if the condition were not malignant, would be of great interest.

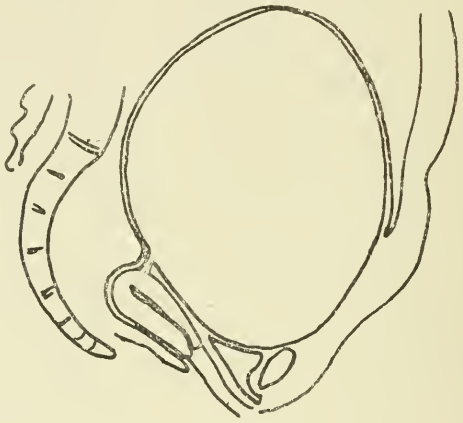

Fig. 2.

The increased abdominal reflex met with on the side of the tumour in my case before operation and the diminution after operation may have been merely accidental, but I note it that other observations may be made on the point. Matthews Duncan in exhibiting the first specimen, in 1876, pointed out that a tumour in this situation might easily be mistaken for an ovarian tumour, and in fact this mistake has been made in all the cases in which a diagnosis was made except when it was mistaken for a uterine fibroid. The tumour is always in front of the uterus and more or less to one side; the position in front of the uterus is rare in ovarian tumours except in certain dermoids, and then the tumour is usually more movable than the round-ligament fibroid. When the consistence is hard it may be mistaken for a sessile uterine fibroid, from which the absence of

enlargement of the uterus or of its union with the tumour would help to distinguish it; or for a pedunculated uterine fibroid, which would usually be more movable and be associated with enlargement of the uterus. A fibroid of (or in) the broad ligament sometimes occupies the same situation as a fibroid of the intra-peritoneal portion of the round ligament, and it would be impossible to distinguish the two conditions until an operation showed that the round ligament formed the pedicle. It might be mistaken for an ovarian fibroid (though these are rarely in front of the uterus) from which its limited mobility, the presence of the ovary on the same side and the absence of ascites (see Frigyesi's * case of fibro-sarcoma) will help to distinguish it. But in some cases where fluctuation is present the diagnosis from ovarian cyst is very difficult, the important points to bear in mind being the presence of the tumour in *front* of and to one side of the uterus, which is not enlarged (unless uterine fibroids be also present), and the presence of the ovary on the same side; this will best be made out by drawing down the cervix while the posterior surface of the broad ligament is examined *per rectum*.

In view of the tendency to degeneration and the danger of the operation in the case of large tumours, fibroids of the intra-abdominal portion of the round ligament should be removed as soon as they cause symptoms or attain any considerable size. If the tumour be pedunculated and free the operation will be very simple. But if, as is usually the case, the tumour burrow beneath the peritoneum, it may entail a very extensive enucleation which will leave a large sac very liable to free oozing on account of the vascularity of the parts; such sacs it will be generally wise to drain with gauze. Care should be taken to securely tie the round ligament artery, which, like the ligament itself, is hypertrophied in these cases. If both ends of the ligament can be identified it is advisable where possible to stitch them together.

* Ibid.

In the cases recorded particulars are given of the results of operation in eleven cases; of these two died = 18·18 per cent. The two fatal cases occurred twenty years ago. The operation is probably a very safe one if the pedicle be securely tied and the sac obliterated by suture or drained.

TABLE OF CASES

OF

FIBRO-MYOMA OF THE INTRA-ABDOMINAL PORTION OF THE ROUND LIGAMENT OF THE UTERUS.

No.	Author.	Age, No. of ch., No. of ab.	Side.	Tumour first noticed.	Chief symptoms.	Consiste
1	Matthews Duncan, 'Edin. J. of M. Science,' 1875-6, iii, p. 846	—	R.	—	—	Dense fil with cretace portio
2	Leopold, 'Archiv für Gyn.,' xvi, 1880, p. 402	43. 2 ch.	R.	After labour 14 years ago	"Facies ovarica." Tumour, after remaining stationary or even diminishing for years, increased rapidly. Menses scanty	Fluctua in plac
3	Winckel, 'Path. der weiblich. sex. Organe,' 1881, Lief. viii, p. 219	76. Several ch.	R. and L.	—	(Fibroid in posterior uterine wall)	—
4	Kleinwächter, 'Zeitschr. für Geb. und Gyn.,' 1882, viii, p. 181	44. 5 ch.	L.	A year after blow on lower abdomen	Slight pains; pain at Poupart's ligament on raising tumour, which was movable and increased in size at periods. Menstruation normal	Firm a hard, h indisti fluctuat at front outer p
5	E. Hasenbalg, 'Zeitschr. für Geb. und Gyn.,' 1892, Bd. xxiii, p. 54	58. Virgo	L.	7 months ago	Menstruation normal; menopause 3 years ago. Pain left lower abdomen for 4 or 5 years; worse for 7 months	Quite h
6	Delbet and Héresco, 'Rev. de Chirurgie,' 1896, p. 607	48. 2 ch.	R.	4 years ago	Menstruation regular, small in amount. No pain or other symptoms till tumour large, when stifling feelings, painful walking, and wasting occurred, also irregular menstruation	Firm a elastic certain s a little s (it wa tapped w out res during operatio
7	C. Martin, 'Brit. Gyn. J.,' xiv, 1898, p. 347	44. Single	—	—	Menstruation irregular, profuse, painful (uterine fibroids present)	—
8	André Claisse, 'Bulletins et Mémoires de la Soc. Anat. de Paris,' Jan. 1900, p. 21	31.	L.	Several months ago	Metrorrhagia and pains for several months (due to uterine fibroids)	Firmis

iagnosis.	Position of uterus (u.).	Size, weight, and pedicle of tumour (t.).	Operation.	Adhesions.	Result.
—	—	T. size of hen's egg; pedicle ¼ inch broad	—	—	—
ltilocular varian ystoma	U. retroverted, slightly movable	T. = 12 kilos., 28 × 25 × 17 cm. T. cystic; cysts lined with epithelium	Exploratory; portion only of t. removed	To omentum and intestines	Death ("collapse," peritonitis) 3rd day.
—	U. had normal relation to tumours (size of beans)	Ts. bilateral, symmetrical, 20 × 12—15 × 10 mm.; pedicle 2 cm. from broad ligament	No	None around tumours	(Patient died of old age).
S d tumour R. ovary	U. pushed to right and behind, not movable. U. not moved on moving T.	T. = 1750 grms., 16 × 18 × 55 cm., pedicle as thick as pencil, 1·5 cm. long, 2·5 cm. from U.	T. removed, pedicle clamped, abdomen drained	To parietes and great omentum	Death (septic peritonitis) 3rd day.
S d tumour L. ovary	Normal (tumour had long axis antero-posterior)	T. of size of goose's egg, 5·2 × 3·5 × 3 cm., weighed 43 grms.	Ligature of pedicle, suture of space from which t. enucleated (broad ligament)	No (t. grew between the layers of the broad ligament)	Recovery (union by first intention).
S d tumour R. ovary	U. to left side and back, "absolutely independent of the tumour"	T. = 10 lbs.; pedicle thin and stretched	T. enucleated, pedicle slipped, chain suture (apparently no drainage)	—	Recovery (lower part of wound opened on 21st day and fistula left).
—	—	T. = 1½ lbs.	T. removed, then total abdominal hysterectomy for fibroid uterus	To bowel	Recovery.
ot made as a case uterine broids)	—	T. 10 to 11 mm. in diameter; pedicle 12 mm. from U.	(Total abdominal hysterectomy for the uterine fibroids)	—	Recovery.

No.	Author.	Age, No. of ch., No. of ab.	Side.	Tumour first noticed.	Chief symptoms.	Consiste
9	G. Prang, 'Inaug. Diss.,' Königsberg, 1900	47. 5 ch.	R.	About 6 months ago	Sacral and gastric pains; metrorrhagia (uterine fibroids present)	Hard (a remova was four fluctuat place
10	G. Baermann, 'Centralb. für Gyn.,' 1901, p. 1280; 'Inaug. Diss.,' München, 1901; J. A. Amann, jun., 'Monatssch. für Geb. und Gyn.,' 1901, Bd. xiv, p. 772	52. 2 ch. 1 ab.	R.	A year ago	Sacral pains every 2 to 3 weeks, lasting 3 to 4 days. Menstruation began at 19, irregular, painless (several uterine fibroids present)	Firm, indisti fluctua noticed several
11	Michaux, 'Bull. et Mémoires de la Soc. de Chirurgie de Paris,' 1901, p. 165	50.	? R.	—	(Uterine fibroids of size of orange present)	—
12	J. A. Amann, jun., 'Monatssch. für Geb. und Gyn.,' 1901, Bd. xiv, p. 772	41. Virgo	R.	—	For a year tenesmus-like pains in intestines, pressure on bladder, occasional stomach pains. Menstruation regular, quite painless (uterine fibroids present)	Parts tumour und myxom degene
13	Oscar Nebesky, 'Monatsschr. für Geb. und Gyn.,' 1903, Bd. xvii, p. 443	43. 4 ch. 2 ab.	L.	—	Menstruation regular, slight in amount. A year ago metrorrhagia, which ceased on removal of two polypi (? fibroid) from uterus. For 2 months pain and pressure on micturition and pricking pain in left side of abdomen	Fir
14	H. R. Spencer (present case)	24. Virgo	R.	3 months ago	12 months ago pain in right side of abdomen above iliac crest; stiffness in walking; symptoms not marked. Menstruation began at 14, always regular, 5 to 6 days, moderate in amount, painful	Firmish appear fluctu and ga superf and d thrill palpat percus

Diagnosis.	Position of uterus (u.).	Size, weight, and pedicle of tumour (t.).	Operation.	Adhesions.	Result.
of R. ovary	U. sinistro-verted	T. = 23·5 × 20·5 × 9·5 cm., weighed 1890 grms.; pedicle size of small pencil	T. enucleated, and cavity stitched with catgut; fibroid in fundus similarly treated	Vascular adhesions to R. abdominal wall	Recovery.
Peduncu-ed subse-us uterine yoma or id ovarian tumour	U. to left of t. and distinct from it	T. = 1300 grms., 18 cm. × 14 cm.; it had undergone myxomatous degeneration	T. removed	No	Recovery.
—	—	T. above umbilicus; pedicle size of thumb, twisted; a second t. size of nut outside this	T. removed (operation very easy)	—	Not given; reported on day of operation.
Uterine yomata here were several broids in uterus)	U. to left side and behind	T. as big as fist, begins 2 cm. from uterine end of ligament	Total abdominal hysterectomy	—	Recovery.
ubserous uterine myoma	U. retro-flexed, distinct from t. but attached to it by palpable pedicle	T. of size of fist; pedicle attached 2½ cm. from uterine end of ligament	T. enucleated after double ligature of pedicle	—	Recovery.
R. multi-locular arian cyst	U. behind and to right of lower end of tumour	T. = 8 in. × 6 in. × 5 in., weighed 6 lbs. = 2721 grms.; pedicle of size of lead pencil	Laparotomy; t. enucleated and removed after ligature of ligament with silk; gauze drainage	No	Recovery.

Mr. Alban Doran was not surprised to find that more than half the cases were associated with fibroids in the uterus. In one instance where he had operated he enucleated a fibro-myomatous growth of the size of a pigeon's egg from the uterine end of one round ligament, and removed the fibroid uterus. It was significant that, as in the case of fibroid of the broad ligament, the same kind of tumour was found both in the intra- and extra-peritoneal portion of the round ligament with relative frequency in young subjects, one patient being only four years old. Fibroid disease was also relatively common in the band representing arrested development of a uterine cornu, and in that case the corresponding round ligament was usually very large. Josephson and Falk believed that too rapid development of that ligament in fœtal life was the cause of malformations of the uterus; hence fibroid of the round ligament might in one sense represent a teratological condition. Quite recently Mr. Doran had removed a uterus bicornis for a large fibroid developed in the septum, another half teratological condition not very rare. Mr. Doran dwelt on the surgical aspect of operations involving division of the round ligament. He thought that Dr. Spencer was right in recommending the union of the divided ends by suture when practicable. The outer stump should not be allowed to recede towards the internal abdominal ring.

Mr. Sampson Handley said he would like to hear Dr. Spencer's views on the pathology of these fibro-myomata of the round ligament. Mr. Doran had brought forward reasons for thinking that they might originate from persistent embryonic structures. He would suggest that possibly fibro-myoma of the broad and of the round ligament were genetically identical, and that both varieties of growth might originate from accessory Fallopian tubes. Kossmann had shown how frequently these accessory tubes were present, and it was now known that certain broad ligament cysts arose from them. He had himself proved the presence of plicæ in such cysts. Since fibro-myoma was known occasionally to arise from the muscle of the normal Fallopian tube, it seemed probable that accessory tubes might give rise not only to broad ligament cysts, but to fibro-myoma of the broad and round ligaments.

Dr. Herbert Spencer, in reply, said he had been particularly interested in the remarks of Mr. Alban Doran, who had done so much valuable work on fibroids of the uterus and broad ligaments. He thought there was much to be said for the teratological origin of these tumours, especially as they sometimes contained adenomatous tissue as in Cullen's and Bluhm's cases. The enlargement of the round ligament in unicornuate uteri mentioned by Mr. Alban Doran he had not previously been

aware of. With regard to Mr. Handley's suggestion it had not been proved to his (Dr. Spencer's) satisfaction that accessory Fallopian tubes existed, and, when it had been proved, he could see no reason why they should be brought in to explain a simple fibro-myoma occurring in a fibro-myomatous structure like the round ligament.

FEBRUARY 3RD, 1904.

EDWARD MALINS, M.D., President, in the Chair.

Present—55 Fellows and 3 visitors.

Books were presented by Drs. Galabin and Cullingworth, The Johns Hopkins Hospital Staff, and the New York Academy of Medicine.

Ethel May Vaughan, M.D., B.S.Lond, and Walter H. Swaffield, M.D., were admitted Fellows of the Society.

A. Macgregor Rose, M.B. (Aberdeen), William H. Whitehouse, M.D. (Birmingham), and Arthur Holbrook Nott, M.B.Durh., Major, I.M.S. (Calcutta) were declared admitted.

The following candidates were proposed for election: —James Marr Brydone, M.B., B.C.Camb.; Kedarnath Das, L.M.S. and M.B.(Cal.), and M.D.Madras; Edmund Moritz Illington, Capt., I.M.S., M.R.C.S., L.R.C.P.; Herbert John Paterson, M.A., M.B., B.C.Cantab, F.R.C.S. Eng.

UNRUPTURED TUBAL GESTATION.

Shown by Mrs. Scharlieb, M.D.

(With Plate IV.)

The specimen was removed from a 6-para aged 30, who was quite well and regular up to July, 1903. At that time, during what appeared to be a normal period, she had an attack of severe pain, which lasted three or four hours. During the next three days the patient felt ill and vomited frequently. From July to October there was constant but not profuse hæmorrhage, unaccompanied by pain.

Examination.—A smooth, globular tumour, of about the size of a billiard ball, close to the uterus but separate from it. Diagnosis lay between a tubal gestation and a small ovarian cyst.

Operation.—October 29th, 1903.

A spherical dilatation of the inner third of the right Fallopian tube. The bladder was adherent to its anterior surface and coils of intestine to the posterior. There was no paratubal hæmorrhage.

The specimen consisted of the right Fallopian tube and ovary. The outer two thirds of the tube were normal, with a patent ostium abdominale. A probe could be passed through it down the tube, but did not enter the swelling.

The globular portion consisted of the dilated tube containing blood-clot permeated by degenerated chorionic villi. In the centre was a smooth cavity lined by the amnion and containing a perfect embryo of twenty-four to twenty-eight days' development. The umbilical vesicle was a prominent object.

It is probable that the hæmorrhage occurred when the patient experienced the severe pain in July. No decidua was expelled from the uterus before or after operation.

DESCRIPTION OF PLATE IV,

Illustrating Mrs. Scharlieb's specimen of "Unruptured Tubal Gestation."

A. Ovary.
B. Ostium abdominale.
C. Infundibulo-pelvic ligament.
D. Right Fallopian tube (outer two thirds).
E. Blood-clot containing chorionic villi.
F. Inner third of Fallopian tube.
G. Abdominal pedicle.
H. Embryo (fourth week).
I. Umbilical vesicle.
K. Amniotic cavity.
L. Amnion.
M. Lumen of tube not communicating with amniotic cavity.
N. Uterine end of tube.

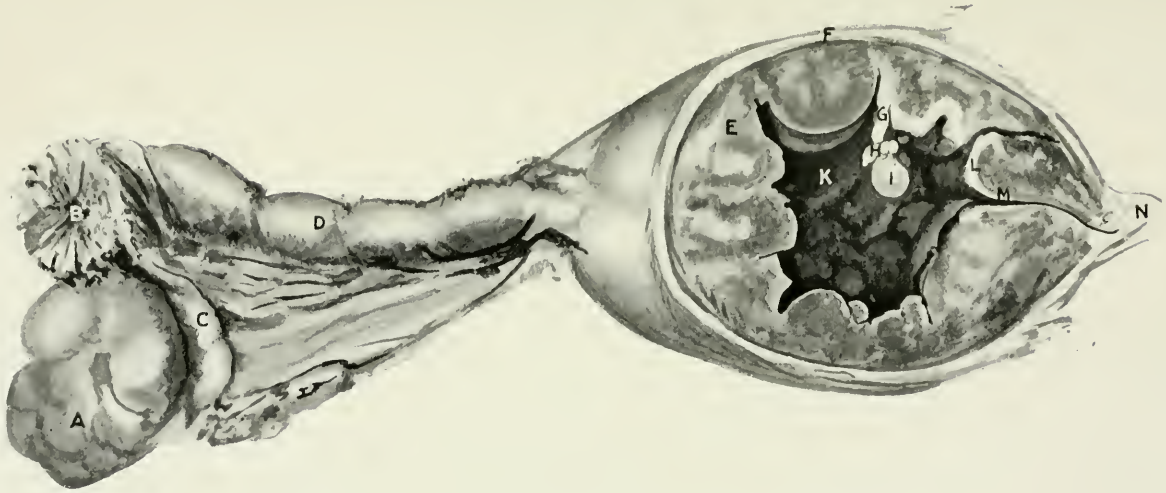

Illustrating Mrs. SCHARLIEB's Specimen of Unruptured Tubal Gestation.

Bale & Danielsson, Ltd.

Dr. Cullingworth said that the number of cases of tubal gestation operated upon before rupture, though increasing, was still so small that it was most desirable that every case should be placed on record. Mrs. Scharlieb's specimen was very beautifully preserved and mounted. Under any circumstances the diagnosis of unruptured tubal pregnancy is attended with much difficulty, but the difficulty is much increased when, as in the present case, the gestation was too early for there to be a history of missed menstruation. Under such circumstances a certain diagnosis must be almost impossible. He understood Mrs. Scharlieb to describe an outer peritoneal covering of the affected portion of the tube, and beneath that the muscular layer of the tube wall, covering a quantity of blood-clot, with which damaged chorionic villi were irregularly mixed up. He wished to ask Mrs. Scharlieb whether there was any evidence of the chorionic villi having invaded the muscular coat, and also whether her examination of the specimen could throw any light upon the question as to whether the ovum in tubal gestation is or is not outside the lumen of the tube?

Mr. Alban Doran believed that, as a large number of tubal abortions were known to occur about the second month, it was highly probable that a still larger proportion of tubal pregnancies terminated even earlier and without symptoms. Perhaps, however, this was not the case, the tube being competent to bear an ovum until it attained a certain size. Much was known about the early stages of tubal gestation, but its clinical features required more study. The discharge of dark blood, known to older writers but not accurately interpreted by them, had been correctly indicated as a cardinal symptom by Dr. Cullingworth. Pain associated with a pelvic swelling and disturbance of the catamenia was sometimes absent, hæmorrhages probably never.

CHORIONEPITHELIOMA OF THE UTERUS, WITH SECONDARY GROWTHS IN THE VAGINA, THE LUNGS, AND THE LIVER.

Shown by G. F. Blacker, M.D.

(With Plate V.)

F. T—, a single woman aged 29 years, was admitted into the Great Northern Hospital June 27th, 1903. She had had one child four years ago. She denied having

been pregnant since, but her friends thought her pregnant in January, 1903, and at that time she was taking large quantities of medicine to bring on her periods. In February a severe loss of blood occurred from the vagina, and these hæmorrhages continued during the four months preceding her admission to the hospital. At the same time, viz. in February, the appearances suggestive of pregnancy disappeared, and it was thought that she had had a miscarriage. The patient complained of marked loss of flesh and extreme weakness, and said that for fourteen days preceding admission to the hospital she had noticed a swelling in the vulva, which had recently burst. On examination she looked very ill, sallow, and emaciated, her temperature was 102·2°, and the pulse rate 104. The tongue was dry, cracked, and coated. The abdomen was distended, and there was some pain over the pubes.

A gangrenous ulcerating patch occupied the right side of the vulva, and extended some little way up the vagina. Hæmorrhage was occurring from the uterus, and the cervical canal admitted one finger. The body of the uterus was ill-defined and enlarged, but no other swelling could be detected in the pelvis. Fine *râles* could be heard all over the right side of the chest, otherwise the heart and lungs were normal.

There was marked anæmia present, and extreme weakness and any radical operation appeared out of the question.

Ten days after her admission a mass developed in the abdomen, and the temperature now varied between 100° and 104°. On July 10th Mr. Stabb, under whose care the patient at this time was, opened the abdomen and evacuated a large abscess containing about two-thirds of a pint of pus, lying to the left of the uterus, and extending down into the pelvis. Numerous dense adhesions were present, and the exact anatomical relations of the abscess cavity could not be determined.

After the abscess had been opened the condition im-

proved somewhat, and the temperature remained about normal from July 17th to August 11th. The hæmorrhages from the uterus continued, and there were severe floodings from time to time.

On August 14th, when I saw the patient for the first time, the abdominal incision had healed. There was a large indurated tender and painful mass in the abdomen. The ulcer in the vulva had healed. On vaginal examination the uterus was fixed in the middle of the abdominal mass, the cervical canal admitted the finger, and a breaking-down growth could be felt in the interior of the uterus. A large ulcerating cavity could be felt in the right lateral wall, and a smaller one in the posterior wall of the vagina. Through the left lateral fornix a mass of about the size of a walnut could be detected, feeling like a collection of blood. Severe hæmorrhage occurred both from the interior of the uterus and from the ulcers in the vagina as the result of manipulation. The patient was coughing up a quantity of blood-stained sputum, and loud *râles* could be heard over both sides of the chest.

Her condition became very rapidly worse, repeated rigors occurred, a very severe hæmorrhage took place on the 25th of August, necessitating saline infusion, and she died on the 27th of August, about six months from the commencement of her illness.

The specimen consists of the uterus, the rectum, the vagina, and the appendages.

The uterus has been laid open by a sagittal section dividing the anterior wall. It measures 13 cm. from the fundus to the external os; of this the cavity of the cervix measures 4 cm., and that of the body 6·5 cm.

The greater part of the anterior wall of the uterus is occupied by a growth measuring 11 cm. by 7·5 cm. This, devoid of any capsule, is invading the muscular tissue of the uterus, and forms a projection, covered only by peritoneum at the fundus. Somewhat to the left of and below the level of the fundus there is an oval area 3 cm. in diameter, ragged on the surface, and of a reddish-grey

colour, where a portion of the growth projecting on the peritoneal aspect has sloughed through. This was no doubt the cause of the abdominal abscess. The lower extremity of the intra-uterine mass reaches to within 2 cm. of the internal os uteri. On its peritoneal surface the growth is somewhat nodular in character, while on section it presents in nearly the whole of its extent the appearance of breaking down blood-clot. There is no definite evidence of tumour as distinct from clot to be recognised anywhere by the naked eye.

The lower 5 cm. of the tumour forms a polypoid mass projecting into the interior of the uterus. The rest of the mucous membrane of the cavity of the body and that of the cervix appears normal.

The vaginal epithelium is wanting in places. In the middle of the posterior vaginal wall, at a distance of 5 cm. from the vulva, is a small breaking down growth measuring 2 cm. in diameter, and similar in appearance to that in the uterine wall.

Projecting into the right side of the vagina is a larger growth measuring 7 cm. by 5·5 cm., which has partly ulcerated through the mucous membrane, and which presents a similar appearance to those already described. Protruding into the left lateral fornix, covered by vaginal mucous membrane, is a mass measuring 6 cm. by 4·5 cm., a portion of a tumour situated mainly in the perivaginal cellular tissue, and presenting on section precisely the same kind of structure.

The ovaries and tubes are normal. No corpus luteum can be recognised. A section of the lung tissue shows it to be studded with numerous irregularly rounded, solid areas of secondary deposits. These measure about 8 mm. in diameter, and present a reddish, mottled appearance. They are readily recognisable on the external aspect of the organ. The rest of the lung has a normal appearance.

In the liver there are a few definite dark red nodules of secondary growth measuring on an average about 4 mm. across. Marked fatty degeneration is present.

DESCRIPTION OF PLATE V,

Illustrating Dr. G. F. Blacker's specimen of "Chorion-epithelioma of Uterus."

Fig. 1.—The uterus and vagina laid open along the primary tumour in the uterus and the secondary growths in the perivaginal connective tissue.

Fig. 2.—Microscopic section of the uterine tumour showing a syncytial mass and numerous large discrete cells.

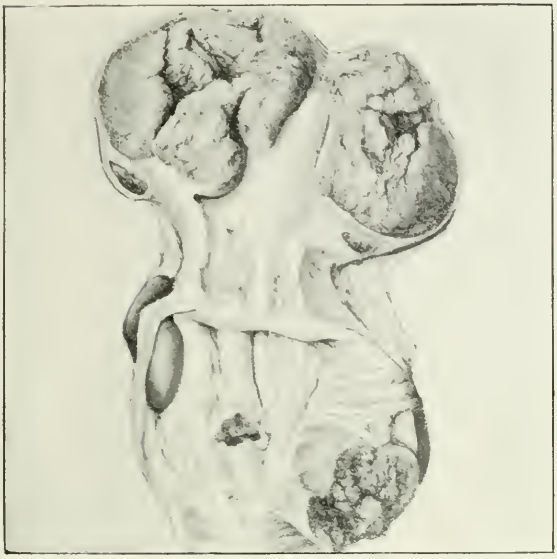

FIG. 1.

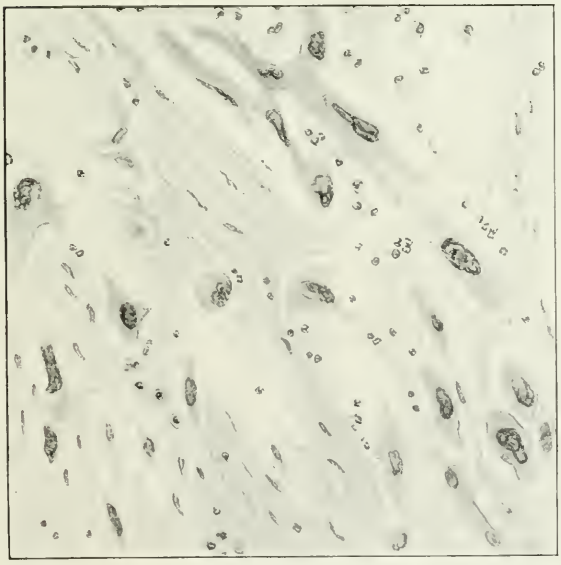

FIG. 2.

Illustrating Dr. G. F. BLACKER'S Specimen of Chorion Epithelioma of the Uterus.

Bale & Danielsson Ltd.

The spleen is more solid than normal, and a section presents a mottled greyish-red appearance with some darkish areas interspersed. These appear to be simply areas of hæmorrhage as there is no evidence of the presence of growth.

Microscopic section of tumour in body of uterus.—The greater part of the growth consists of disorganised blood clot. Towards the periphery there are a number of discrete irregularly polyhedral cells with large nuclei, partly collected into masses, partly scattered throughout the blood clot. The remains of a large number of similar cells which have undergone degeneration can be recognised. These cells are infiltrating the muscle-tissue of the wall of the uterus. In one or two places there are a few elongated branching masses of protoplasm with multiple nuclei, bearing a resemblance to syncytial masses. The main microscopic feature of the tumour is the almost complete absence of syncytium.

Secondary growths in vagina.—These present even a greater degree of degeneration. The main part of the tumour is made up of blood clot, and very few distinctive discrete cells are to be seen, although there is evidence of the presence of considerable numbers of such cells in various stages of degeneration. No syncytium is recognisable.

Secondary growths in lungs.—There are numerous areas of hæmorrhage present and amongst them are some discrete cells similar to those seen in the uterine growth. Around these hæmorrhagic areas there is some consolidation of the lung tissue.

Secondary growths in liver.—These consist almost entirely of blood with some discrete tumour cells situated at the periphery of the hæmorrhages, and no syncytium.

Spleen.—There are numerous hæmorrhagic and necrotic patches in the splenic pulp, but there are no tumour cells and no syncytium present.

The other organs were normal.

PRIMARY CANCER OF THE RIGHT FALLOPIAN TUBE; RIGHT OVARY NORMAL.

Shown by H. Briggs, M.B., F.R.C.S.Eng.

The right Fallopian tube was seven inches long and two and a half inches wide. There was papillary cancerous cystic growth of the left ovary (two inches in diameter). The left tube had malignant thickened walls. Cancerous secondary deposits existed on intestines, parietes, and omentum. The uterus was normal in size and apparently unaffected.

Abdominal section on November 27th, 1903; recovery; recurrence; ascites reported on January 21st, 1904.

M. M—, aged 50; married at the age of twenty-six; sterile. History of swelling of abdomen noticed two months previously; pains in lower abdomen soon after the swelling was first observed. Menstruation, seven days, every twenty-eight days, painless; sometimes there were clots and an occasional intermenstrual discharge. The patient had always suffered from indigestion, and twelve years ago she underwent with success the open-air treatment for the first stage of pulmonary consumption.

Physical signs on admission.—She looked ill. The breathing was 24 per minute. Her temperature was 100·4°. Her pulse 100, of low tension and poor volume. The abdominal walls were tightly distended; the skin glazed; the physical signs of ascites were present. *Per vaginam* the uterus was ascertained to lie forwards, was pushed downwards, the portio vaginalis elongated as in pseudo-prolapsus. There were two swellings, the right large cylinder-shaped heavy Fallopian tube, and the left irregularly outlined and adherent appendages, less enlarged than the right. The diagnosis of an inflammatory enlargement was made from the symptoms, but the physical

features of the right Fallopian tube denoted a lump, too large and too heavy for that of a tubercular salpingitis. There was ascites as in tubercular salpingitis, and there was also the pulmonary tubercular history of twelve years ago.

During the operation of abdominal section the separation of coils of intestine from over the pelvic brim occupied three quarters of an hour. Many secondary masses were peeled off the intestines. Then the appendages were removed with little difficulty. They were only slightly adherent. The uterus was carefully examined, and as it was not abnormal in size it was not removed.

Mr. Alban Doran was interested in learning that there was no sanious discharge from the uterus in this case. This symptom was the rule in primary cancer of the Fallopian tube, and there was evidence that the blood was derived from the tube itself,—in fact, it came from the cancer. On the other hand, the uterine hæmorrhages in tubal abortion came from the uterus, not (or certainly not as a rule) from the blood in the tube. Mr. Doran reminded the Society of a case of tubal mole which he had exhibited four years ago. There was free show of blood on the morning of the operation. He noticed when dividing the tube near the uterine cornu that there was no blood in its canal, nor did any run after removal out of the cut end from the blood in the mole. A few hours after the operation the bleeding from the uterus returned, and continued for four days (vol. xlii, p. 136). Mr. Doran considered that in Mr. Briggs's case, as was the rule, the cancer developed amidst products of old inflammation. He noted his own case of papilloma of the tube removed by Spencer Wells in 1879,—the patient was yet alive—and compared it with Kaltenbach's case, which was apparently just beginning to show malignant degeneration when the tube was removed, and Knowsley Thornton's case, which was entirely cancerous at the date of the operation, with a distinct history of old pelvic inflammation. Papilloma was considered by French authorities, on reasonable grounds, to be a form of salpingitis. In Mr. Briggs's case the inflammation seemed as though originally tubercular, quite unusual in the history of primary cancer of the tube.

Dr. Heywood Smith asked whether it would not have been more advisable, considering how much the right oviduct was involved in the disease, as well as the left adnexa, to have removed the whole uterus as well.

Annual Meeting.

The audited Report of the Treasurer (Dr. G. E. Herman) was read.

On the motion of Mr. H. W. Kiallmark, seconded by Dr. Henry Briggs, the Report of the Treasurer (Dr. G. E. Herman) was received and adopted.

Report of the Honorary Librarian.

I beg to report that the condition of the Library remains satisfactory.

The total number of volumes now in the Library amounts to 5922, of which 65 are periodicals. Of these 65 periodicals 21 are bound each year in 2 volumes.

During the year 121 volumes have been added. These comprise 76 separate books acquired by donation and 34 by purchase, together with 1 volume of tracts by donation and 13 by purchase.

The number of Fellows visiting the Library has increased. The visits paid amount to 775 for the year. The number of books borrowed remains about the same as in the previous year.

The aim of the Council, acting with regard to economy and dealing with limited book-space, has been to place upon the shelves of the Library all the best and most recent literature on midwifery and diseases of women, and to render the resources of the Library easily accessible to the general body of Fellows. Robert Boxall.

The Report of the Hon. Librarian, Dr. Boxall, was received, and its adoption was moved by Mr. Doran, seconded by Dr. G. F. Blacker, and carried.

OBSTETRICAL SOCIETY OF LONDON.

Abstract of Receipts and Payments for the year ending December 31st, 1903.

RECEIPTS.

1903.	£	s.	d.	£	s.	d.
To balance from 1902				87	10	11
On Deposit				350	0	0
„ (1) Annual Subscriptions, realising				460	19	6
„ (2) Composition Fees				26	5	0
„ (3) Midwives' Examination Fees				1560	4	0
„ (4) Sale of 'Transactions' (Longmans)	4	16	10			
Do. do. (Society)	10	14	9			
Do. Midwives' Questions	2	1	0			
Do. „ Regulations	0	5	8			
				17	18	3
„ (5) Interest on Debentures	80	5	0			
Ditto on Deposit	15	7	8			
Ditto on Consols	14	18	0			
				110	10	8

Audited and approved.

Newson-Smith, Mundy, and Co.

G. E. Herman, *Treasurer.*

26th January, 1904.

£2613 8 4

PAYMENTS.

1903.	£	s.	d.	£	s.	d.
By (1) 'Transactions,' Vol. XLIV, Printing, Paper, Binding, Delivery, and Illustrations				238	4	10
„ (2) Library:						
Books purchased	35	12	3			
Binding	12	17	3			
				48	9	6
„ (3) Museum and Library:						
Rent	200	0	0			
Librarian's Salary	175	0	0			
Repairs to Furniture, Cleaning, Coals, Lighting, and Furniture	52	12	10			
				427	12	10
„ (4) Expenses of Meetings				49	8	3
„ (5) Stationery, Stamps, and Printing				74	15	6
„ (6) Examination of Midwives:						
Fees paid to Examiners	741	7	6			
General Expenses	224	7	10			
				965	15	4
„ (7) Extraordinary Expenses				15	3	6
„ (8) Purchase of L.C.C. Stock				750	0	0
„ (9) Banking Expenses				0	12	3
„ Balance at Bank	116	12	3			
Less Cheque not presented	73	5	11			
				43	6	4
				£2613	8	4

Report of the Chairman of the Board for the Examination of Midwives.

I have the honour to report that during the past year there have been 1545 candidates at the Examinations for the Society's Certificate. Of these 1221 passed, 298 failed, and 26 were absent from the Examination.

The number at the November Examination was the largest on record. There were 479 candidates, of whom 365 passed, 108 failed, and 6 were absent.

The total number of candidates who have applied to be examined since 1872 are 10,270, of whom 8515 have passed.

It has been found necessary, in view of the large number of candidates for the next examination, to engage the Examination Hall, and this will be again required in May. W. R. Dakin.

The Report of the Chairman of the Board for the Examination of Midwives was adopted on the motion of Dr. C. J. Cullingworth, who said there were one or two noticeable features in the Report. One of these was the exceptional number of candidates that had presented themselves. This was no doubt owing to the impending institution of a State Examination. Candidates fearing the unknown were hastening to avail themselves of the Society's Examination, which, for some months to come, would qualify for enrolment. The motion was seconded by Mrs. Scharlieb.

The following alterations in the Laws were carried :

Present Laws.	*Proposed Laws.*
Chap. I.	Chap. I.
5. The Officers of the Society shall be elected from the Fellows, and shall consist of a President, four Vice-Presidents, three Trustees, a Treasurer, a Chairman of the Midwifery Board, an Honorary Librarian, and two Honorary	5. The Officers of the Society shall be elected from the Fellows, and shall consist of a President, four Vice-Presidents, three Trustees, a Treasurer, a Chairman of the Midwifery Board, *an Editor of the 'Transactions,'* an Honorary

Present Laws.	*Proposed Laws.*
CHAP. I—*continued.*	CHAP. I—*continued.*
Secretaries. The affairs of the Society shall be managed by a Council composed of the above-named Officers, five of the past Presidents nominated in the order of their seniority, the retiring President *ex officio*, and of eighteen other Fellows elected annually by the Society.	Librarian, and two Honorary Secretaries. The affairs of the Society shall be managed by a Council composed of the above-named Officers, five of the past Presidents nominated in the order of their seniority, the retiring President *ex officio*, and of eighteen other Fellows elected annually by the Society.
CHAP. V.	CHAP. V.
3. Fellows wishing to compound for their Annual Subscriptions may pay—On admission a Composition Fee of Fifteen Guineas; after Ten Annual Payments, Ten Guineas; after Twenty or more Annual Payments, Five Guineas.	3. Fellows wishing to compound for their Annual Subscriptions may pay—On admission a Composition Fee of Fifteen Guineas; after Ten Annual Payments. Ten Guineas; after Twenty or more Annual Payments, Five Guineas; *provided always that no Fellow may compound for future contributions from whom an annual contribution is at the time due.*
CHAP. XVI.	CHAP. XVI.
7. All papers read before the Society shall be considered the property of the Society; but authors of papers accepted for reading before the Society are at liberty to publish them in any scientific periodical after they have been read, provided that acknowledgment of the fact of their having been read before the Society is made in such other periodical.	7. All papers read *and communications made* before the Society shall be considered the property of the Society; but authors of papers accepted for reading before the Society are at liberty to publish them in any scientific periodical after they have been read, provided that acknowledgment of the fact of their having been read before the Society is made in such other periodical.

N.B.—The proposed alterations are in *italics*.

The following gentlemen were elected Honorary Fellows of the Society:—Samuel Pozzi, M.D., and Sir John Williams, Bart., K.C.V.O., M.D., F.R.C.P.

The following gentlemen were declared elected to serve on the Council of the Society for the Session 1904–5:

President.—Edward Malins, M.D.

Vice-Presidents.—A. H. Freeland Barbour, M.D. (Edinburgh); Amand Routh, M.D., B.S.; William Japp Sinclair, M.D. (Manchester); Herbert R. Spencer, M.D.

Treasurer.—George Ernest Herman, M.D.

Chairman of the Board for the Examination of Midwives.—W. R. Dakin, M.D.

Editor of the 'Transactions.'—Herbert R. Spencer, M.D.

Honorary Secretaries.—Montagu Handfield-Jones, M.D.; Robert Boxall, M.D.

Honorary Librarian.—Arthur H. N. Lewers, M.D.

Other Members of Council.—Sydney Beauchamp, M.B., B.C.; John M. Biggs; Albert Charles Butler-Smythe; Murdoch Cameron, M.D. (Glasgow); Charles James Cullingworth, M.D.; Ernest Rumley Dawson; John Henry Ewart (Eastbourne); John Shields Fairbairn, M.D., B.Ch.; Charles Arthur Goullet; David Berry Hart, M.D. (Edinburgh); Arthur Corrie Keep, M.D., C.M.Edin; Arnold W. W. Lea, M.D. (Manchester); Cuthbert Lockyer, M.D., B.S.; William Rivers Pollock, M.B., B.C.; Harry Campbell Pope, M.D.; Edward Reynolds Ray; Walter C. Swayne, M.D. (Bristol); Charles J. Wright (Leeds).

Dr. Heywood Smith proposed, and Dr. H. Russell Andrews seconded, a vote of thanks to the retiring Vice-President, Dr. John Phillips, and to the other retiring members of Council, Dr. Comyns Berkeley, Dr. Briggs, Dr. Fowler, Dr. Griffith, Dr. Lewers, Dr. Stevens, and Dr. Tayler.

Dr. F. H. Champneys moved, and Dr. Herbert R. Spencer seconded, a vote of thanks to the retiring Hon. Secretary, Dr. Amand Routh, and to the retiring Hon. Librarian, Dr. Boxall, and Dr. Amand Routh briefly replied.

The President then delivered the Annual Address.

ANNUAL ADDRESS.

It is an old observation that the present joys of life we doubly taste by looking back with pleasure on the past. If this be true we have reason to congratulate ourselves upon the progress of our Society during the year just gone, and to find satisfaction in our continued prosperity. It has been customary for the President to give at the Annual Meeting a brief *résumé* of the work which has been accomplished during the session among its Fellows. I do not wish to deviate from this time-honoured plan, for it has some advantages. To those who have not been able to attend the meetings with regularity the narration may serve as a stimulus for them to emulate, or to add to the value of, our proceedings. It may appear somewhat desultory to others who are conversant with the details and have shared in making the history by which our position is maintained.

A retrospect is not always one so happy as this. In some instances care sits behind the horseman, and he who would ride in security must not too often look back upon her face. Fortunately I have been exempt from that necessity, for the course before me is marked out by content in the present, and indicated by hope for the future.

To begin with our roll-call. On the 1st of January, 1903, the Society numbered 607 Ordinary and 12 Honorary Fellows = 619. Death has laid his hand on seven of these. There have been 14 resignations and 9 erasures, leaving 590. Thirty new Fellows have been elected during the year, bringing the total up to 621. Among the latter have been five ladies; a small proportion in comparison with the number outside, some of whom, I

think would do wisely in giving us the benefit of their talents. We welcome this addition to our ranks as an earnest of our desire to obliterate the past prejudices and passions which have been associated with the endeavour of women to gain a footing on level ground with men in the medical profession. We may regard it, also, as a proof of enlightenment in modern times, which has allowed—among us at least—liberty, equality, and fraternity to all animated by the beneficent objects for which our Society was founded.

The past year's work of the Society has been a remarkably prolific one, productive of substantial and valuable additions to our knowledge. It is not easy to classify the material given, but I will endeavour to group it together as far as possible, taking the papers as a guide. The papers—the larger planets—have satellites euphemistically spoken of as "short communications," a distinction often without a difference.

The specimens constitute the constellations; their name is legion, for they are many; it is impossible in the space at my disposal to do them justice, though they fill an important place in the Society's orb. Eleven meetings have been held, ten ordinary and one extra, at which have been included an Inaugural Address, an Annual Address, and six papers. The remainder were devoted to "short communications;" description of cases; exhibition of specimens, and discussion; in all a full session.

In January a paper by Dr. Robert Jones (introduced by Dr. W. S. A. Griffith) was read on "Puerperal Insanity." The paper was based upon a personal experience of 259 cases, of which 120 occurred during the actual puerperal period, 83 during lactation, and 56 during pregnancy. Puerperal insanity was stated to be of a characteristic form after confinement, to quote the words of the author, amounting almost to a nosological entity, though this is not the case during pregnancy nor during lactation, there being no definite type of insanity occurring in connection with these two stages. Certain propositions were enunciated by Dr.

Jones with regard to the mental condition, symptoms, ætiology, pathology, and treatment; a form of statement which cleared the ground materially, and greatly facilitated the discussion. The speakers were authoritative and numerous, representing experts in insanity and in obstetrics; while the outcome was essentially of a practical character. The trend of the discussion was mainly directed to the pathology and treatment. With regard to the origin, heredity and stress were considered the main factors, nearly 50 per cent. of the cases having some hereditary predisposition. How far the stress was due to a toxin was debated, and the relations of septic infection duly weighed, Dr. Percy White being of opinion that the worst cases were of septic origin; the frequency of puerperal insanity was given as 1 in every 700 labours.

This frequency is variously stated by others. I notice that Dr. Whitridge Williams gives it as 1 in every 616 labours, and considers it to be much less frequent than formerly. As bearing upon the septic origin, "It would seem," he writes, "that the introduction of aseptic methods into midwifery is responsible for a reduction by one half of its incidence." If this is correct, then another leaf may be added to the laurels many years ago so hardly earned by Semmelweiss, and so justly awarded to him by posterity. Dr. Jones touched a sensitive point in speaking of the home treatment, and considered it to be an intense relief to the family to avoid the stigma of an asylum when possible. This expression of opinion was not endorsed by subsequent speakers. Dr. Charles Mercier protested strongly against the suggestion that cases of puerperal mania could be treated satisfactorily at home, while Dr. Seymour Tuke gave three cogent reasons for treatment in a well-ordered asylum. Individual experiences were related; there was a general agreement as to the value of food and sleep in such cases, and also in the opinion that, generally speaking, a favourable prognosis may be given.

"On the Anatomy of the Pregnant Tube" was the

subject of a valuable paper read by Dr. H. Russell Andrews on May 6th.

A description of the histological appearances of the tube and ovum in early tubal pregnancy was given, and the question of tubal decidua fully discussed. Dr. Andrews believes that decidual changes are to be found in the tube, but that a compact decidua comparable to that formed in the uterus is not present. The difference of structure in the mucous membrane of the folds and that of the intervals between them was pointed out. The ovum was stated to lie outside the lumen of the tube, in the tubal muscle. This was explained as being due to the eroding action of the trophoblast, which also is responsible for the opening of vessels, and mainly for the production of rupture and abortion.

Taken in conjunction with the communication by Dr. Lockyer, at the same meeting, on "A Case of Incomplete Tubal Abortion showing Intra-mural Imbedding of the Placenta," the Society had an important demonstration presented. Many of the facts described by Webster, by Hart and Gulland, the researches in comparative anatomy of Hubrecht, and the descriptions of Peters's ovum, admit of Dr. Andrews's work being regarded with much interest and value.

One of the most important contributions of modern times was a paper read by Dr. J. H. Teacher (introduced by Dr. Eden) on June 4th entitled "On Chorionepithelioma (the so-called Deciduoma Malignum) and the occurrence of Chorionepitheliomatous and Hydatidiform Mole-like Structures in Tumours of the Testis." Round this subject considerable, and even enthusiastic, interest was gathered, an adjourned meeting for further discussion being held on June 16th.

Dr. Teacher's paper was an elaborate exposition, collated with much care, and infinite attention to details; it was illustrated by drawings, photographs, and microscopical preparations as to the nature and origin of chorionepithelioma, and its relations to the placenta.

Probably Dr. Teacher laid too much emphasis upon the result of the now historic discussion held at the Obstetrical Society in 1896. The report of that Committee (vol. xxxviii, p. 183), consisting of exceptionally able pathologists, states: "We are of opinion that these cases are sarcomata, and therefore of connective-tissue origin, and they contain plasmodia identical in character with the 'so-called' syncytial masses described by writers as deciduoma malignum, and the presumption is that they have arisen in maternal, not in fœtal tissues; but there is no definite evidence before us on this point." Again—"We are of opinion that there is nothing in the histological characters of these specimens to justify the supposition that they are of decidual origin, and the term deciduoma malignum is therefore an inappropriate one." At this meeting also, May 6th, the President, Dr. Champneys, reiterated the opinion of previous speakers when he remarked "the conclusion of the debate seemed to be that the question is far from being settled." The views of the Committee as a whole represented the views held by the majority of its component members. It must be borne in mind that there is no finality in knowledge, nor must it be supposed that among the individual members of the Committee the last word on the subject was assumed to have been spoken. Further, Dr. Teacher's narration of the views held by so great an authority as Veit gives testimony that there was fair ground at least for the conclusions then reached by the Committee as to the resemblance of these conditions to sarcomata.

It is in accordance with the true spirit of scientific research that progress is made by accretion, by the comparison and verification of the work of others, as well as by patient and persistent observation on the part of all searchers for truth. Dr. Eden frankly admitted in the discussion on Dr. Teacher's paper that subsequent consideration of Marchand's views, together with continued study of the subject, had led to altered opinions as to the origin and nature of the subject under debate, while the

contributions of Dr. Lockyer and others give proof that the Society had neither slumbered nor slept in its efforts to solve the problems which had arisen.

The conclusions which Dr. Teacher in his paper considered as proved were that (1) the so-called deciduoma malignum is a tumour arising in connection with pregnancy, and originating from the epithelium of the chorionic villi (or its forerunner, the trophoblast) which is of fœtal ectoblastic origin. The malignant hydatidiform moles may be treated as a variety of chorionepithelioma. (2) That the chorionepithelioma and malignant hydatidiform mole form quite a characteristic group of tumours clinically and pathologically, and that they should be classified neither as sarcomata nor carcinomata, but as a distinct class *sui generis*. (3) That in addition to the common tumours developing from a pregnancy, there are tumours containing precisely similar structures which are not connected with a pregnancy, and may occur in other parts of the body than the uterus, and in either sex. These, he concludes, are most probably teratomata, originating from some structure which has the morphological value of an included, matured, and fertilised ovum; and the chorion-epitheliomatous tissues represent the actual trophoblast (chorionic epithelium of the included ovum).

The title was somewhat varied at the following meeting —"Chorionepithelioma and the occurrence of Chorion-epitheliomatous and Hydatidiform Mole-like Structures in Teratomata."

Dr. Galabin opened the discussion at the adjourned meeting, stating that it had been his belief from the first that the so-called deciduoma malignum was the result of pregnancy, and that it was a fœtal epithelioma implanted upon the mother. Dr. Spencer affirmed that at the time mentioned he had opposed the view of Dr. Kanthack and Dr. Eden, and had brought forward evidence to show that the disease originated in the products of conception.

A great number of specimens have been shown tending to confirm the deductions of Dr. Teacher's paper. Evi-

dence has even been evoked from the spirits of the deep —specimens long dormant in jars have been minutely examined, and by the interpretation of modern views have been rehabilitated and labelled afresh. Clinical descriptions have also been numerous in lending adhesion to support the pathological alliance. The consensus of opinion revealed that the position so clearly expounded by Dr. Teacher represents the most advanced knowledge of the subject at the present time.

There still remain questions of much interest to be elucidated in connection with certain points brought out in the course of the discussion, notably, among others, the explanation of such cases as that brought forward by Dr. Ritchie, "Embryoma in the Anterior Mediastinum of a Male Adult," the occurrence of secondary growths, and the remarkable disappearance of secondary growths after removal of primary growths.

An interesting corollary to the paper and the specimens shown was a communication by Mr. J. D. Malcolm and Dr. R. Hamilton Bell on "A Case of Hydatidiform Mole with Bilateral Cystic Disease of the Ovaries and Invasion of the Muscular Wall of the Uterus, the patient being quite well two years after removal of the parts." From the condition of the patient delivery of the uterine contents was necessitated. The uterus was emptied and curetted on May 8th, a large quantity of hydatidiform material evacuated which it was impossible to remove with the finger. On the 12th the uterus was again curetted. The condition of the patient not being satisfactory the abdomen was opened and two ovarian tumours removed, the right one having a twisted pedicle; the whole uterus was also taken away. Other instances of the occurrence of vesicular mole and chorionepithelioma have been recorded as associated with bilateral, or single, or ovarian cysts. Mrs. Scharlieb gave an account of one happening in her own practice.

It was mentioned that while any association between cystic ovarian degeneration and vesicular mole has been

denied, there appears from high authorities a strong presumption that some such relation is not uncommonly observed.

On July 1st a paper was read by Mr. Sydney Stephenson (introduced by Dr. W. S. A. Griffith) on "Ophthalmia Neonatorum, its Etiology and Prevention." Beginning with the statement that ophthalmia neonatorum is the cause of more blindness than any other disease of the eyes, except atrophy of the optic nerves, Mr. Stephenson remarked that it accounted for 10 per cent. of the cases of blindness, and that of 1498 instances of this disease gonococci were demonstrated in 60·17 per cent. He therefore laid considerable stress upon the bacteriological examination of pus from the conjunctiva. The most practical and by far the best means of prevention Mr. Stephenson strongly insisted was the method of Credé—the application of a single drop of a 2 per cent. solution of silver nitrate dropped into the baby's eyes as soon as possible after birth. The objection to this is that it sometimes produces a trifling amount of conjunctivitis. This Dr. Herman remarked was a point of importance in the practice of young medical men. Failing to find any evidence of specific infection he advocated the use of a 1 in 2000 sublimate solution. It was urged that in the training of midwives a knowledge of the use of appropriate remedies in these cases should be included. But it was pointed out that regulations already exist as to the use of a 1 in 4000 sublimate solution by midwives for this purpose. The objection to a multiplicity of details in the conduct of their duties was clearly shown by Dr. Cullingworth. Dr. Horrocks adverted to the non-necessity of routine treatment in all cases, the inference being that in about 90 per cent. of the cases there is no occasion for it. Difference of opinion was expressed upon this point, and also upon the value of various solutions recommended.

Mr. Stephenson, in reply, was firmly convinced that Credé's method was the best available plan of prophylaxis, and he appealed to the Society to endorse its general use.

The discussion left on one's mind an impression suggested by the lines of Pope :

> "'Tis with our judgments as our watches—none
> Go just alike, yet each believes his own."

On November 4th Dr. George J. Maguire read a paper on "Acute Contagious Pemphigus in the Newborn." Apart from syphilitic origin this condition is rare; eighteen cases with eight deaths were recorded as having happened in twenty deliveries in the Richmond Lying-in Charity.

The contagion was traced to the practice of a certain midwife. It was considered by Dr. Maguire to be of septic origin, gaining entrance through the unhealed umbilicus, the pathogenic germs being the *Staphylococcus pyogenes aureus*. Details were given of the clinical history and appearances of the eruption, and it was stated that no treatment was of any avail in the course or the result of the disease. One peculiarity of the epidemic was mentioned—that in some instances it was communicated to older children and to adults. All the mothers, with one slight exception, were healthy, and all the children were breast-fed. Some doubt was subsequently manifested in the discussion as to the form of the specific micro-organism and as to the place of its entrance.

Dr. T. Vincent Dickinson alluded to a similar epidemic occurring at Parma in 1901–2, and gave some details connected with it.

"On the Fate of the Ovum and Graafian Follicle in Pre-menstrual Ages." In this paper read by Dr. T. G. Stevens the author states that the object is to try and determine to what degree the Graafian follicle matures in pre-menstrual life, and if possible to show the retrograde stages until a scar is formed; and also to know what becomes of the ovum during these retrograde stages. Upwards of seventy pairs of ovaries of children under ten years of age were examined by serial sections, a task evidently entailing an enormous amount of labour.

Dr. Stevens found that no rupture of the follicle takes

place, and that nothing like a corpus luteum is ever formed. The follicle and contained ovum matures up to a certain point, then a kind of phagocytic action takes place—the agent being the cells of the membrana granulosa,—by which the ovum is removed, though it may undergo simple necrobiosis; finally the contents of the follicle are absorbed, it contracts, by means of a granulation tissue, which forms in its wall, which eventually absorbs the remains of the membrana granulosa and the liquor folliculi.

In the criticisms following this paper it was suggested that the destructive cells mentioned might be leucocytes, and not those of the membrana granulosa, and that the destructive functions said to be due to them were contrary to known physiological processes. The investigations were rendered less reliable by the fact that the observations were all made post-mortem. The chief point of interest seemed to be the retrogression of the membrana granulosa cells in pre-menstrual life, while, when sexual life begins they continue to grow after the dehiscence of the follicle and form the corpus luteum. Thus the corpus luteum, with its ascribed function of forming the internal secretion of the ovary, marks the difference which characterises puberty from the changes which are presented in earlier periods of life.

Gentlemen, there is a shade which passes before us in a review such as we are engaged upon this evening; a dimness which always causes some trepidation and even difficulty in penetrating—that is in the chronicling of our Obituary notices.

The commemorative instinct is strong within us; we seek to keep alive the names of those who have dwelt in our midst, who have strengthened our counsels and shared our deliberations. We desire to cherish in our Register the achievements of those who have shed lustre upon our Society, and, as far as possible, to call to mind all our departed Fellows, for here there is no distinction.

"Pallida mors æquo pulsat pede."

Alike those who enter, or occupy, the palaces of kings, or those who toil among the dwellers of more humble homes, all equally submit to the inevitable and irresistible stroke of death. It is said that it is not easy to write a suitable epitaph ; it is less so to write with propriety and impartiality what we would wish to say of those who have passed away. There have been instances where we might have been relieved from the task by the complacency and self-satisfaction of those who have anticipated beyond the grave. Peter Chamberlen—a name familiar to us,—whose aggressiveness and dominant self-confidence led him to appraise his own powers for posterity, thus wrote the inscription for his own tomb :

> "To tell his learning and his life to men
> Enough is said, by there lyes Chamberlen."

This pride of exultation is sometimes also met with in men of genius sensible of their own merits, and fearful lest they should not be duly recognised :—"When I am dead," said the great Anatomist, "you will not meet with another John Hunter." If it is embarrassing to record the attributes of the dead on monuments of stone it is more difficult to do full justice to their memory on occasions like the present, yet it is fitting that we should give an account of the vacancies in our ranks, and bear testimony to the ties which have hitherto bound the deceased in association with our proceedings.

Thomas Gaillard Thomas, M.D., was an Honorary Fellow of this Society. He was born in South Carolina, November 31st, 1832, and died suddenly of heart disease in New York on the 28th of February, 1903.

Thirty years ago Dr. Gaillard Thomas occupied a distinguished position of world-wide fame. He filled in succession the Chairs of Obstetrics and Gynæcology at the College of Physicians and Surgeons of New York.

In 1868 he published a work on diseases of women, which passed through nine editions, and was translated into five languages. As an operator his reputation was

widespread; one of his methods of opening the abdomen he described as gastroelytrotomy. He endeavoured to substitute the term of areolar hyperplasia for that of chronic metritis. He was a frequent contributor to obstetric and gynæcological literature, a well-known speaker in discussions, and a man of refinement and culture. Dr. Thomas was looked upon as one of the best teachers and lecturers in America on the subjects with which he was associated in his profession. He was elected to the highest distinction of this Society in 1872.

R. J. Wallace, M.D., Calcutta. Of him I have not been able to get any account beyond the mention that he died on September 27th, 1903, at Calcutta, where he had been in practice.

The same with regard to Edward W. Jenks, M.D., Detroit, from whose son a letter was received in July, 1903, saying that his father died of pneumonia on March 19th, on his way home from a pleasure trip in Mexico.

Edward Wilmshurst Tait, M.R.C.S., died on March 31st, 1903, at his residence at Hampstead. He was born at Heytesbury, Wiltshire, in 1829. His father being a Congregational Minister, Mr. Tait was educated at St. Bartholomew's Hospital, and ever gratefully acknowledged the influence of Sir James Paget's teaching upon his life and career. He was a highly respected practitioner at Highbury Park, and retired from active work some ten years before his death. Mr. Tait was a staunch Non-conformist, a man of innate courtesy and consideration, regarded with much affection by all who knew him and who were acquainted with high principles which actuated his life.

Edward William Flemyng Stiven, M.D.Ed., came of a Sutherlandshire family. His father was a Surgeon in the Indian Army. His grandfather also a Surgeon under the Old John Company. Dr. Stiven was born in India in 1851. He was educated at Madras College, St. Andrews, entering at Edinburgh for Medicine, at which University

he took the degrees of M.B. and C.M. in 1874. He afterwards studied at Berlin and Vienna. While at the latter place the Servian war broke out, and Dr. Stiven took service with the Servian Army. As the Russo-Turkish war developed he joined the Turkish troops under the employment of the Stafford House Committee, and rendered much valuable aid to the wounded. His name is associated with a memorable march to Erzeroum amid great difficulties of climate and marauding villains of every description. After a severe attack of fever he returned to England, entered into practice for a time at South Shields, and settled finally at Harrow in 1881. Here he soon associated himself with the public work of the town, becoming Chairman, first of the Local Board, and, after the new Act, of the District Council in 1898. His technical knowledge, his vigorous mind, and love of active work enabled him to effect many reforms, and to afford great help in the administration of local affairs. Dr. Stiven died of pneumonia, after an illness of five days, on July 21st, 1903. He was buried in the churchyard of Roxeth amid manifestations of universal regret. He left a wife and five children.

William Henry Kempster, M.D.St. Andrews, of Clapham Common, was 69 years of age at the time of his death in December last. He was trained at the Westminster Hospital Medical School, where he gained the Chadwick Medal and Prize, and was a prosector of the Royal College of Surgeons. He took the M.R.C.S. in 1862, and in 1868 the L.R.C.P.Edin., and fourteen years later the M.D.St. Andrews. He was Medical Officer of Health for Battersea for more than thirty years, and also held the appointments of Divisional Surgeon of Police and Public Vaccinator. He was Treasurer and an ex-President of the Society of Medical Officers of Health. Outside medical work he was interested in Freemasonry, and was a Past Grand Master. In his last few years he was confined to the house with the illness which eventually caused his death.

John Griffiths Swayne, M.D.Lond., was at one time a

Vice-President of this Society. Born in 1819, Dr. Swayne reached a ripe old age, passing away at Clifton on August 1st, 1903, in his 85th year.

He was the son of a Clifton practitioner, and began his studies at the Bristol Medical School, continuing them at Guy's Hospital and in Paris. He obtained the degree of M.B. at the University of London in 1842 with the Gold Medal in Medicine and Midwifery, the M.D. three years later. Soon afterwards he commenced practice in Bristol, taking part in the teaching school of that city.

In 1853 he was elected the first Physician Accoucheur to the Bristol General Hospital, a post he retained for twenty-two years. Part of this period he was Professor of Midwifery at University College, Bristol.

Dr. Swayne was well known as the writer of a small book entitled 'Obstetric Aphorisms,' a work which he stated as being "merely intended to serve the temporary purpose of a guide to beginners in the Obstetric art." However, it became very popular, passed through ten editions, and was translated into eight foreign languages, including Japanese and Hindustani. He also contributed several interesting papers to our 'Transactions,' as well as to other journals on obstetric subjects. For fifty years Dr. Swayne was actively engaged as a teacher in the Bristol Medical School. He long held a prominent and honourable position as an expert obstetrician throughout the west of England. Dr. Swayne possessed considerable literary and artistic ability. He was reserved in manner, benevolent in disposition, a devoted son of the church, to which he was much attached and a valuable supporter. He was also highly esteemed as a citizen. He lived long, but he realised the highest consummation of life, for as he drifted into the sere and yellow leaf he had all "that which should accompany old age, as honour, love, obedience, troops of friends."

William Smoult Playfair, M.D.Ed. Dr. Playfair was for many years a distinguished Fellow among us, a frequent contributor to the 'Transactions,' a facile writer, a

lucid speaker, and an effective debater at our meetings. He was admitted Fellow on January 6th, 1864, and soon identified himself with the work of the Society, becoming Hon. Librarian 1868–9, Hon. Secretary 1870–2, Vice-President 1873–5, and President 1879–80.

Dr. Playfair came of a stock which had done much service to the state and to the community, his grandfather, Dr. James Playfair, being Principal of St. Andrews University for nineteen years. His brother, Lord Playfair, was for some years Professor of Chemistry at the University of Edinburgh, and afterwards the representative in Parliament of the Universities of Edinburgh and St. Andrews. Another brother was Sir Robert Lambert Playfair, British Consul at Algiers. His father, George Playfair, was Inspector-General of Hospitals in Bengal. The subject of this memoir, Dr. William S. Playfair, was born at St. Andrews in 1836. He received his earliest training in his native city, and after graduating in medicine at Edinburgh in 1856, completed his medical education in Paris.

Aspiring to follow the steps of his father, he entered the Indian Medical Service in 1857, serving in the Bengal army as assistant surgeon in Oude during the Mutiny. Upon the more settled state of that province he obtained the post of Professor of Surgery at Calcutta Medical College in the years 1859—60. Finding the climate affecting his health after some years' residence in India, he resolved to leave that country and begin afresh. It is singular to relate that he went to the opposite extreme and chose to establish himself at St. Petersburg; in fact, he commenced practice in that city, remaining there six months without realising his expectations as to health or progress.

He returned to London in 1863 with no settled or definite plans in his mind, intending to seize the opportunity which presented itself to him as a suitable opening, conscious of his own powers, and relying upon his determination to succeed in his profession. At this time Dr.

Arthur Farre resigned his position as Professor of Obstetrics at King's College and as Physician Accoucheur to King's College Hospital. Dr. Priestley succeeded him after a contest, owing to which Dr. Tanner and Dr. Meadows gave up their appointments. Then came Playfair's opportunity. He applied himself to obtain it with an alertness and vigour which presaged his fixed idea of success in what he undertook. He gained what he sought, and was elected Assistant Physician for the Diseases of Women and Children to King's College Hospital, and, on the retirement of Dr. Priestley in 1872, Dr. Playfair was appointed Professor of Obstetric Medicine at King's College and Obstetric Physician to King's College Hospital. These appointments he held for twenty-five years, resigning in 1898, not from any age limit or inability, but in accordance with his conviction that this period of time was sufficient length of service on individual and on public grounds.

On vacating these posts he was entertained at dinner by a large and enthusiastic gathering of his friends, presided over by Lord Lister, who acknowledged his acquaintance during forty-four years with Dr. Playfair, and expressed in graceful terms the high appreciation of his undiminished honour and probity of purpose in public and in private life.

It is characteristic of Dr. Playfair's energy and will power that when, almost by accident, he took up the subject of obstetrics and gynæcology as his future pursuit in life on obtaining his appointment in 1863, he developed so rapidly into an advanced position in these arts; indeed, he admitted that at this particular juncture of his life he knew no more about obstetrics than he did about astronomy. He was the first to protest against and to decline to hand over his patients to the general surgeon for operation, and asserted his surgical instincts by setting the example of obstetricians operating upon their own patients in the diseases pertaining to their own department.

Honours came quickly upon him. He became Physician-Accoucheur to Her Imperial and Royal Highness the Duchess of Edinburgh; Grand Officer of the Crown of Roumania. The Universities of Edinburgh, and of St. Andrews, conferred upon him the honorary degree of LL.D. He was made an Honorary Fellow of the American and of the Boston Gynæcological Societies, of the Obstetrical Society of Edinburgh, and of King's College, Consulting Physician to the General Lying-in Hospital, and to the Evelina Hospital for Children, and lastly Emeritus Professor of Obstetrics at King's College, and Consulting Physician for Diseases of Women to King's College Hospital.

Dr. Playfair's contributions to the distinctive literature of his profession were numerous. In 1865 he published a hand-book of obstetric operations, which became gradually disused after the published lectures of Dr. Barnes on the same subject in 1870. In the volume of the 'Transactions' for 1867 there are valuable papers from his pen on the treatment of labour complicated by ovarian tumours, and in the 'Lancet' for the same year on thrombosis and embolism of the pulmonary artery as a cause of death in the puerperal state. In 1874 there appeared in the same paper lectures on chronic uterine catarrh which were read and referred to with a widespread interest. He there pointed out that applications to the interior of the uterus could be facilitated by the use of a particular form of instrument now familiarly known as Playfair's probe. In 1876 he published his treatise on the 'Science and Practice of Midwifery,' a book which subsequently reached the ninth edition. This was based upon the teaching of the Edinburgh School as enunciated by Professor Simpson, and prior to him by Dr. Hamilton. Indeed a very close resemblance is exhibited in the text to the lectures delivered by Simpson, under whom Playfair had been a student. But the popularity of this work, which was great, consists chiefly in the charm of the style in

which it was written, a style which makes the subject appear easy, and pleasant even, to read.

In 1881 he published 'Notes on the Systematic Treatment of Nerve Prostration and Hysteria connected with Uterine Disease.' It is this subject with which his name has been most closely associated. Indeed, I doubt if any name in our profession was more widely known outside professional circles, or any treatment more talked of or criticised, when he first brought it under the notice of the medical profession in this country. In writing these notes he announced that he had no original contribution to make to the profession, and that he was led to review the subject by the study of Dr. Weir Mitchell's "remarkable work"—'Fat and Blood, and how to make them.' The obscurity surrounding this class of cases, the protean symptoms connected with them, the difficulty of amelioration and treatment has been—and I'm afraid still is—often embarrassing, calculated sorely to try the patience, and to vex the skill of the medical attendant. Dr. Playfair called especial attention to the fact that while in a large number of these cases there is, or has been, very real uterine mischief, many of them have drifted beyond the point at which local treatment, however judicious, is capable of effecting a cure. I need hardly say to you that the essentials of the treatment are comprised under the heads of (1) seclusion; (2) massage; (3) electricity; (4) diet and regimen. Dr. Playfair adopted this method of treatment with much enthusiasm in spite of some expressed misgivings and free criticism. At any rate he thoroughly believed in it himself and advocated it with a persistence and intensity which seldom failed to carry conviction. He was wont to exhibit illustrations of cures effected by these means, and to exclaim with a laudable pride as he displayed the photographs of patients before and after treatment, "Look upon this picture, and upon that!" The comparison appealed at once, and certainly appeared to justify both the premises and the conclusions.

Soon after, or indeed for years before his retirement,

he was troubled with some enlargement of his prostate gland. For this trouble he underwent an operation in August, 1902, with much benefit. On his recovery he went to Rome, and for a time enjoyed good health. Writing to me from that place in a letter dated March 3rd, 1903, he said "I have been very reluctantly compelled by the bad health I have had for some years past to retire from practice, which has been a great distress to me, as I had hoped to have died in harness. Happily this rest and change has made a new man of me, and I am thoroughly enjoying my stay in this most interesting of all places; and I now realise for the first time how I have been struggling unwisely for some years not to throw up the sponge." The activity of mind he had always possessed gave him interests for the time being in fresh subjects. He designed to write, along with Mr. Rushworth, the President of the Archæological Society of Rome, a "History of the English Church in Rome." This happy object did not come within his realisation, for on the 24th of March he was seized with an attack of apoplexy at Florence. There, under the assiduous attention of Dr. Coldstream and of my friend and former colleague Sir Willoughby Wade, he gradually rallied. His main desire was to return to his native town of St. Andrews. His natural hopefulness helped him, and to that place he was brought by easy stages. There sat the "shadow feared of man" waiting to claim his companionship. The symptoms of old-standing kidney mischief here supervened, to which he slowly succumbed, and died on August 3rd, 1903. For some days before his death he suffered from distressing sickness; even then his vitality and cheerfulness of spirits did not desert him. He met the sympathy expressed to him with a smile, and with an effort of his former self remarked that "People are sometimes sick on crossing the bar." The force of the allusion gave ominous reference to his approaching end. Shortly he was carried over the bar, and passed calmly through less troubled

waters to that distant bourne from which there is no return.

He was buried in the cemetery of St. Andrews with the rites of the Episcopal church. This Society was represented at the funeral by Dr. John Phillips who happened to be near the locality at the time, and who kindly bore our tribute to the long association of Dr. Playfair among us, and the loss sustained by his death.

Dr. Playfair married in 1864, Emily, daughter of Mr. James Kitson, of Leeds, by whom he had one son and three daughters, who survive him.

I cannot allow the opportunity to pass without expressing my thanks to the officers of the Society for the valuable support I have received during the first term of my lease as President; to Miss Hannam for ever ready help and information always cheerfully given, to the Hon. Secretaries, Dr. Amand Routh, and Dr. Handfield Jones, for willing assistance on all occasions. My duties having brought me more closely in association with Dr. Amand Routh I refer to him with profound appreciation of his service to the Society: the intimate knowledge of details, the sound judgment, and the unfailing loyalty he has displayed to the interests of the Society during a period of four years will leave his name conspicuous in our annals among those who have done so much to add to its character and progress.

On the motion of Dr. C. H. F. Routh, seconded by Dr. Herman, a vote of thanks to the President for his address was passed by acclamation.

MARCH 2ND, 1904.

EDWARD MALINS, M.D., President, in the Chair.

Present—46 Fellows and 6 Visitors.

Books were presented by the St. Bartholomew's Hospital Staff, the Radcliffe Librarian, and the Select Committee on Ventilation appointed by the House of Commons.

Florence Elizabeth Willey, M.B., B.S.Lond., was admitted a Fellow.

Richard T. Worthington, M.B., B.C.Cantab., was declared admitted.

The following candidates were proposed for election: —R. Drummond Maxwell, M.B.Lond.; Asa Claude Van Buren, M.B., B.S.Lond.

The following gentlemen were elected Fellows of the Society:—James Marr Brydone, M.B., B.C.Cantab.; Kedarnath Das, L.M.S. and M.B.Cal. and M.D.Madras; Edmund Moritz Illington, Capt. I.M.S., M.R.C.S., and L.R.C.P.; Herbert John Paterson, M.A., M.B., B.C.Cantab., F.R.C.S.Eng.

The PRESIDENT announced that it had been found advisable to make a slight change in the rules with regard to

the sending in of the MS. of remarks made and specimens shown at the Meetings—viz. that the speakers and exhibitors must send to the Secretaries *before the Saturday morning following the meeting* an account of the same in writing.

TWO SPECIMENS OF EXTRA-UTERINE FŒTATION.

Shown by Dr. Handfield-Jones.

Dr. Handfield-Jones showed two specimens of extra-uterine fœtation. In both cases the pregnancy occurred in the right Fallopian tube, and was advanced to about the seventh week, and in both cases there was no rupture of the tube.

In one case death had occurred owing to the severe hæmorrhage, which poured out from the open end of the tube. In the other case only a couple of drachms of blood had escaped into the peritoneal cavity, but in both cases a large amount of blood-clot was found in the distended tube surrounding the ovum.

Operation was easy and the result satisfactory in the second case, while in the first patient death occurred from hæmorrhage before surgical interference was possible.

The cases would seem to emphasise the desirability and advantage of early operation in these cases of unruptured tubal gestation.

Dr. Cullingworth asked if the death had occurred *before* the contemplated examination under anæsthesia, as, if so, it could not of course be ascribed to injury during manipulation, a point which it seemed important to make perfectly clear.

TWO CASES INVOLVING THE QUESTION OF THE SITE OF IMPREGNATION.*

By Harrison Cripps,
SURGEON TO ST. BARTHOLOMEW'S HOSPITAL;
AND
Herbert Williamson,
DEMONSTRATOR OF PRACTICAL OBSTETRICS AT ST. BARTHOLOMEW'S HOSPITAL.

(Received October 27th, 1903.)

(*Abstract.*)

Case 1.—Tubal Gestation after Complete Removal of the Ovary on the same Side.

A case is recorded in which, after complete removal of the right ovary, gestation subsequently occurred in the right tube.

There are two possible explanations of this phenomenon:

(1) The presence of an accessory ovary on the right side.

(2) External migration of the ovum.

These two possibilities are discussed in some detail, and the conclusion arrived at is that external migration of the ovum is the more probable.

Two similar cases recorded in the literature are quoted.

Case 2.—Pregnancy after Removal of a Portion of both Tubes.

A case is recorded in which a patient became pregnant after both Fallopian tubes had been ligatured; to prevent subsequent conception the abdomen was reopened and a portion of each tube excised. In spite of this the patient again became pregnant.

* The authors are indebted to Dr. Champneys for permission to use his notes upon these two cases.

Similar cases from the literature are quoted, and the manner in which the ovum traversed the obstructed tube is discussed.

The bearing of these two cases upon the ætiology of tubal gestation is briefly indicated.

In spite of the careful and valuable work which in recent years has been done upon the early history and development of the fertilised ovum, and in spite of the light which Peters's observations have thrown upon many previously obscure pathological conditions, we are still in ignorance of the site at which impregnation normally occurs and of all details of the journey of the ovum from the ovary to the uterus. The following two cases which have occurred in the practice of St. Bartholomew's Hospital have some bearing upon these points and are therefore placed on record.

Case 1.—Tubal Gestation after Complete Removal of the Ovary on the same Side.

B. D— was admitted into St. Bartholomew's Hospital on January 10th, 1903, under the care of Dr. Champneys, complaining of pain in the lower part of the abdomen, and hæmorrhage from the vagina.

She had had previously five pregnancies, four children (the last of whom was born in January, 1902), and one miscarriage in 1898.

Menstruation had always been regular; the periods commenced when she was 14 years of age, they recurred every twenty-eight days, lasted four days, and the amount lost was not excessive. The last period ceased on November 9th, 1902.

The patient stated that she underwent an operation in 1899, when Mrs. Scharlieb removed an ovarian tumour.

History of the present condition.—After the cessation of the menstrual period in November, 1902, there followed six weeks' amenorrhœa. In Christmas week of that year the patient commenced to suffer from pain situated chiefly

in the right iliac fossa; this pain came on suddenly, but without any symptoms of collapse, at the same time she noticed hæmorrhage from the vagina. The pain and hæmorrhage have persisted since that date, the hæmorrhage being sufficient to necessitate the use of six diapers per day.

On examination per hypogastrium a scar was seen reaching from the pubes to the umbilicus; and on the right side of the hypogastrium, situated two and a half inches above the pubes was a fixed indurated mass of the size of an orange.

Per vaginam the cervix was displaced downwards, forwards, and to the right, so as to lie a finger's breadth behind the right pubic ramus; behind this, and occupying the rest of the pelvis, was a fixed tumour partly solid, partly fluid, and elastic.

Bimanually the uterus could be felt lying behind the right Poupart's ligament, and not appreciably enlarged. The tumour itself reached to a point midway between the pubes and umbilicus.

Per rectum the tumour lay entirely in front of the bowel. The uterine sound passed, with its concavity forwards, for a distance of four inches in front of the tumour.

On January 21st abdominal section was performed by Mr. Harrison Cripps. An incision five inches in length was made, nearly in the middle line and just to the right of the scar of the previous incision. A quantity of old blood-clot was found in Douglas's pouch, and the right Fallopian tube was expanded and ruptured. The tube was drawn up into the wound (after separating adhesions) and the broad ligament transfixed and secured as a pedicle. The distended tube was then cut away. Nearly a pint of old blood-clot was removed from Douglas's pouch. Careful search failed to reveal any trace of a right ovary. The patient made an uninterrupted recovery and was discharged on February 21st, 1903.

Sections of the tube wall and of portions of the clot

found in the tube show the presence of numerous well-formed chorionic villi, so that there can be no doubt whatever that the case was one of tubal gestation.

Mrs. Scharlieb writes as follows: "I removed from Mrs. D— a right-sided ovarian tumour on May 9th, 1899. It contained much grumous material and a little coiled-up hair. It was the size of a fœtal head at full term. The uterus and appendages of the left side were healthy. The patient made a good recovery and went home on the 2nd of June."

The chief interest in this case centres in the fact that it affords clear proof of the possibility of gestation in a Fallopian tube, after the ovary of the same side has been removed.

At the operation described above, a careful search was made but no trace of the organ could be discovered; further the condition found at the previous operation, a dermoid cyst, renders it very improbable that any portion of the oöphoron could have been left behind. What was the source, then, of the ovum which gave rise to the tubal gestation?

Was there an accessory ovary on the right side? This is improbable—the presence of a third ovary is one of the rarest abnormalities met with in the human body, if indeed it ever occurs. Cases have been recorded from time to time, but of those which have been subjected to thorough examination, very few have stood the test. Small pedunculated tumours attached to the surface of the ovary, small fibro-myomata of the ovarian ligament, and corpora fibrosa have all been described as accessory ovaries, until submitted to microscopical examination, when their real nature became revealed.

A very interesting case has been recently reported by Baldwin (1). On July 15th, 1893, he removed by abdominal section both ovaries and tubes from a woman aged 32. She had for some years suffered from menorrhagia, but the reasons which led him to perform this operation are not very clearly given. He states, how-

ever, that no adhesions were encountered, and that the recovery from the operation was uneventful.

In spite of this treatment the menorrhagia persisted, and eleven months later the patient was curetted but without benefit. "In November, 1894, careful examination revealed a small mass of tissue to the left of the uterus. When this was pressed upon a sensation was experienced similar to that caused by pressure upon an ovary." The abdomen was again opened, and "this mass of tissue, which was between the layers of left broad ligament and apparently just below the remains of the ovarian ligament, was identified and removed. It was about the size and shape of a small Lima bean and presented all the characteristics of ordinary ovarian tissue."

The situation of this structure, "just below the remains of the ovarian ligament," suggests very strongly that the ovary was not completely removed at the first operation. Doran has pointed out that this is precisely the spot at which removal is likely to be incomplete.

Thumin (2) has recently fully reviewed and criticised the recorded cases of third or accessory ovaries, and he gives instances which apparently must be admitted; but in these cases there has been present a third Fallopian tube in communication with the uterus.

Doran (3) has examined a number of instances in which pregnancy had occurred after double ovariotomy. In all the cases he has investigated, the operation was undertaken either for cystic disease or for inflammatory conditions of the ovary; and under circumstances which rendered it extremely probable that portions of ovarian tissue had been left behind. This could be demonstrated in some instances by examination of the specimens, whilst in others the description of the operation indicates the impossibility of absolute certainty of the removal of the whole organ. Where, however, we have to deal with a dermoid, a clearly circumscribed and pedunculated tumour, its complete removal is a much easier matter, and it seems improbable that any oöphoritic tissue would

be left. We are, therefore, driven to the conclusion that the ovum was derived from the ovary of the opposite side.

It is not easy to understand how the ovum after its escape from the Graafian follicle finds its way into the tube.

The fimbria ovarica is the only portion of the abdominal ostium which is in close anatomical relation with the ovary, and it is impossible to imagine that it can apply itself to each successive portion of the surface which presents a ripe follicle. It seems that the discharged ovum must pass directly into the peritoneal cavity, and subsequently, through some agency imperfectly understood as yet, be directed into the tube. There is experimental evidence in support of the theory that the active agents are the cilia of the epithelium upon the abdominal ostium, that by their action they give rise to currents in the capillary layer of fluid between the pelvic viscera, and that by these currents the ova are wafted towards one or other tube. Lode (4) injected the ova of ascarides into the peritoneal cavity of animals; he found that they made their way to the pelvis, entered the tubes, traversed the uterus, and eventually appeared in the vagina. Williams (5) states that this experimental evidence is reinforced by the fact that in certain amphibians large tracts of the peritoneum become covered by ciliated epithelium shortly before the time of ovulation.

The possibility that an ovum may enter the Fallopian tube of the side opposite to the ovary from which it was shed was long ago suggested; and to this journey of the ovum across the peritoneal cavity the term "external migration" has been applied. The case we have just recorded appears to be of this nature.

Two similar cases are on record. One is reported by Küstner (6), the other by Howard Kelly (7).

Küstner operated upon a woman for tubal gestation on the right side and, after he had removed the tube, finding that the left ovary was cystic he removed that organ

also; two years later the patient again became pregnant: the pregnancy on this occasion was intra-uterine. Küstner subsequently performed the same operation upon several rabbits, removing the ovary on one side and the tube upon the other; these animals repeatedly became pregnant after the operation, but the pregnancy was always intra-uterine.

Kelly's case was very similar: he found it necessary on one occasion to remove a diseased left ovary and a diseased right tube. Six months afterwards the woman became pregnant, and was delivered at term of a healthy child. Seventeen months later pregnancy occurred in the left tube, and rupture necessitated its removal by abdominal section.

Further proof of the external migration of the ovum is furnished by the study of the situation of the corpus luteum of pregnancy. Whitridge Williams (8) has examined six cases in which the corpus luteum was found in one ovary, and the pregnancy in the opposite tube, and Opitz (9) in eighteen cases of tubal pregnancy found the corpus luteum in the opposite ovary in three. We have ourselves found this condition in one out of the three last cases operated upon at St. Bartholomew's Hospital.

Although the matter does not admit of positive proof there can be little doubt that we have here an instance of external migration of the ovum, but in what part of its course the ovum became impregnated we cannot say; possibly as suggested by Sippel (10) impregnation occurred in the abdominal cavity and the subsequent gestation was tubal because the development of the trophoblast reached such a stage that the ovum was able to bore its way into the tubal mucosa and gain an implantation before it reached the uterine cavity.

Case 2.—Case of Pregnancy after Removal of a Portion of both Tubes.

In 1884, being then 24 years of age, the patient commenced to suffer from palpitation of the heart, and from

attacks of breathlessness. She noticed that these symptoms were always worse at the time of her monthly periods, indeed not infrequently on the first day of the flow she was obliged to keep her bed on account of the violent beating of the heart.

In 1888 she became pregnant: for the first part of the pregnancy she remained in her usual health, but towards the end of the fourth month the palpitation and breathlessness became much more marked; in due course she was delivered, and after the birth of the child the symptoms rapidly abated.

Between 1889 and 1893 she became pregnant three times; in each of these pregnancies the same course of events occurred, but with each succeeding gestation the exacerbation of the symptoms appeared earlier and was more severe.

In 1893 enlargement of the neck and prominence of the eyeballs were noticed, and the patient came to St. Bartholomew's Hospital.

In 1895 she again became pregnant, and on October 9th of that year was admitted as an in-patient under the care of Dr. Champneys. Previous to this there had occurred four months' amenorrhœa. On admission her pulse rate was 120, the cardiac impulse and pulsation of the carotids were very forcible, the eyes were prominent, and the thyroid was markedly enlarged. The hands were tremulous, but neither Von Graafe's nor Stellwag's sign was present. There was marked dyspnœa, so much so that at first it was difficult for the patient to lie down in bed. The physical characters of the uterus corresponded with a four months' gestation.

After ten days' complete rest in bed she showed a decided improvement, and left the hospital much better in every way.

On February 5th, 1896 (in the eighth month of her pregnancy) she returned, and her condition at this time was so grave that labour was at once induced. This procedure was followed by immediate recovery, the

improvement being marked within twenty-four hours. At the end of a fortnight she left the hospital, only to return again in November, 1897, this time two and a half months pregnant. The symptoms were so severe as to call for the immediate emptying of the uterus, and therefore a tent was put into the cervix and abortion induced. The same rapid improvement followed.

In July, 1898, she was again admitted, six weeks pregnant; at this time in a state of very great distress, quite unable to lie down and suffering intensely from the beating of the heart and throbbing of the arteries. The uterus was again emptied, and Dr. Champneys expressed the opinion that steps should be taken to prevent further pregnancies.

Mr. Harrison Cripps ligatured the Fallopian tubes on September 7th, 1898. The abdomen was opened in the middle line by an incision 1½ inches in length situated midway between the symphysis pubis and the umbilicus. The left tube and broad ligament were then drawn up into the wound, a silk ligature passed, by means of a pedicle needle through the two layers of the broad ligament, immediately beneath the tube, and the tube ligatured near its fimbriated end. The right tube was then dealt with in a similar manner, excepting that the ligature was passed nearer to its uterine extremity. The patient made an uninterrupted recovery, and left the hospital on September 24th.

She was readmitted on June 25th, 1899, and stated that after leaving the hospital she was in good health and her menstruation was perfectly regular until April, 1899. Since that time the catamenia had been absent, and the train of symptoms from which she had suffered in her former pregnancies had returned. On examination she was found to be two months pregnant; abortion was again induced.

On October 6th (in the absence of Mr. Cripps) a second operation was performed by Mr. Bruce Clark. The abdomen was re-opened in the middle line, and the left tube

drawn up into the wound; at the site where it had previously been ligatured the tube was completely divided and the two ends separated by a distance of about a quarter of an inch. No trace of a ligature could be seen. The right tube was then drawn into the wound; it appeared in every way natural, there was no solution of continuity and no trace of the ligature. A loop of each tube, in turn, was drawn up into the wound, a ligature passed through the mesosalpinx between the two sides of the loop, and the whole tied as a pedicle with a Staffordshire knot. The knuckle of the tube on the distal side of the ligature was cut away. The abdominal wound was then closed. The recovery was uninterrupted.

In January, 1901, the patient was again admitted, suffering from an incomplete abortion. The cervix was dilated and the uterine cavity explored with the finger. Portions of placenta were removed.

Cases of pregnancy after ligature of the Fallopian tubes have been from time to time reported, and the following instances throw some light upon the method of passage of the ova along tubes whose lumena have been apparently occluded.

A case is reported by Horrocks (11) "in which a patient had been sterilised after Cæsarean section by ligaturing the Fallopian tubes. In spite of this she became pregnant again, and the uterus ruptured along the line of incision when near full term, the child and a portion of the placenta escaping into the abdomen. Dr. Galabin removed the uterus, and the specimen is now in the Guy's Hospital Museum. The ligature on one side had cut through the tube, and the severed ends lay about half an inch apart. On the other side the tube and ligature looked as if the tying had only just been done, but on experimenting it was impossible to force a coloured liquid through the tube. Still it was thought that in all probability the ovum which had become impregnated had got past the constriction produced by the ligature and had so entered the uterus."

Galabin (12) reports a case in which after performing Cæsarean section he tied the tubes with kangaroo tendon, and the patient became pregnant again within a year or so. "Taught by the experience of these cases," he continues, "I have since then adopted the plan of cutting a piece out of the tube between the two ligatures, then pulling out the stump on each side as far as possible and cutting it off, so that the open lumen was left at the bottom of an inverted case of cellular tissue. None of the patients so treated have become pregnant again, and I am inclined to regard this as a reliable method."

That removal of portions of the tube wall, however, is not a reliable method is shown by the case we have just recorded.

In discussing Galabin's case Bland-Sutton spoke as follows (13):—"It is now quite certain that when a Fallopian tube is ligatured in its continuity it does not necessarily permanently obliterate the tubal lumen. In a case of Cæsarean section for pelvic contraction in 1891 I tied the Fallopian tube with thin silk within an inch of the uterus. This patient has remained sterile. On a subsequent occasion when it was deemed prudent to induce labour for uncontrollable vomiting and epileptic seizures, an attempt was made to sterilise the patient by drawing out each tube and transfixing the mesosalpinx with a needle armed with thin silk and then tightly tying the tube near its middle.

This failed, for the patient conceived again, and has re-conceived many times, though her constitutional condition has never allowed a pregnancy to go to term. Since this experience, I have always tied the tubes in two places and exsected a piece of the tube when it was desirable to sterilise a patient."

Doran has suggested that the ligature may perhaps ulcerate through the tube, which then heals behind it without causing stricture of its canal. It is well-known that sometimes a ligature which has been applied to the cut end of the ureter after nephrectomy, may subsequently

be passed from the bladder, and the following case shows that the same thing is possible in a Fallopian tube.

In 1898 Bland-Sutton removed an ovarian cyst, its slender pedicle was tied with thin silk; the recovery was uneventful, but for many weeks afterwards the patient complained of cramp-like pains on the side from which the cyst had been removed. The pain gradually passed away and ten months later, during menstruation, the patient accidentally noticed on her napkin a tiny loop of silk. This proved to be the loop of silk used to secure the Fallopian tube; it had ulcerated into the tube, and had been very slowly conducted into the uterus and so escaped.

The occurrence of pregnancy after removal of portions of the tubes is more difficult to understand. It can hardly be that the severed ends of the tubes have become reunited, and the canal again patent; but it is possible that a process of absorption may have occurred in the walls of those parts of the tube which were in contact with one another, the process ultimately leading to the formation of a fistula between the two portions, so that the continuity of the canal once again becomes established.

There is another point of both clinical and pathological importance to be noticed: in all the cases quoted the lumen was either completely obstructed or narrowed; in Horrocks's case coloured fluid could not be made to pass the obstruction, yet in none of them was the subsequent pregnancy a tubal one.

These two cases taken together may perhaps add something to our knowledge of the causation of tubal gestation. In Case 1 we have an instance of tubal gestation with external migration of the ovum, but with no occlusion of the lumen of the tube; in Case 2 the lumen of the tube on one side was completely obliterated, and on the other must have been considerably narrowed, but the pregnancy was uterine.

Literature.

1. Baldwin.—Amer. Journ. Obstet., December, 1902.
2. Ueberzählige Eierstöcke Archiv für Gyn., 1898.
3. Obst. Soc. Trans., 1902, p. 231 *et seq.*
4. Wiener Klin. Wochenschr., 1891.
5. Obstetrics, p. 79.
6. "Ueber Extra-uterinschwangerschaft," Volkmann's Sammlung Klin. Vorträg., N.F., 1899, Nos. 244, 245.
7. Operative Gynæcology, vol. ii, 189.
8. Obstetrics, p. 80.
9. "Ueber die Ursachen der Ansiedelung des Eies im Eileiter," Zeitschr. für Geb. and Gyn., 1890.
10. Zur Kenntniss und Behandlung der Tuberschwangerschaften, Monatsschr. für Geb. and Gyn., 1897.
11. Obst. Soc. Trans., 1900, p. 243.
12. Obst. Soc. Trans., 1902, p. 246.
13. Obst. Soc. Trans., 1902, p. 244.

Mr. Alban Doran laid great stress on the subject of pregnancy after the removal of both ovaries as bearing on the question of the site of impregnation. In respect to Case 1, he considered that the existence of ovarian tissue on the same side as the Fallopian tube satisfactorily explained the subsequent tubal pregnancy. External migration seemed to him less probable. In regard to Case 2, it was not necessary to assume that the continuity of the entire canal of the partially excised tube from the abdominal ostium to the uterus must be restored before the tube could resume its functions. Patency of the proximal end was quite sufficient. Mr. Doran briefly analysed published instances of pregnancy after extirpation of both ovaries, claiming that they justified his views on the authors' two cases. Taking double ovariotomy for cystic tumours first, he observed that Schatz designedly saved a small piece of the right ovary and the entire right tube. In Mr. Doran's case Dr. Robert Barnes removed the left ovary and tube, and fourteen years later he himself took away the right ovary, enucleating the base from the broad ligament, and leaving more or less of

the right tube. He noted during the operation that the pedicle on the left side was completely atrophied, not a trace of tube or ovarian ligament remaining. Stansbury-Sutton and Baldwin each removed a pair of ovarian cysts with long pedicles easily divided below the limits of the ovaries; the tubes were amputated. Turning next to oöphorectomy for inflammatory disease of both ovaries, Lapthorn Smith's and Stansbury-Sutton's cases must be rejected, as delivery occurred about nine months after the operation, so that there might have been a very early ovum already in the uterus when the appendages were removed. Gordon, Morris, and Anderson Robertson reported very authentic instances of pregnancy taking place some time after double oöphorectomy. The tubes were amputated, but it was highly probable that the ovaries were not entirely removed. In none of these cases of double ovariotomy or oöphorectomy was the external migration theory so probable as the alternative explanation; in Mr. Doran's case it was impossible. Ligatures do not readily obliterate mucous canals, hence in all the cases where the Fallopian tube was divided, its stump regained its patency, and was then enabled to take up an ovum from a fragment of the ovary on its own side, or from a piece of ovarian tissue in the stump of the corresponding ovarian ligament. The latter condition was most probable in Stansbury-Sutton's and Baldwin's patients, where the cysts were removed with ease owing to the length of the pedicles. When the tube was not removed at all, as in Schatz's case, and in another reported by Engelmann, and in another oöphorectomy by Kossmann, it was still easier to understand how it could receive an ovum developed in ovarian tissue on its own side. Mr. Doran had more than once detected ovarian tissue in the ovarian ligament close to the uterus and far from the anatomical ovary.

Dr. Williamson said that he appreciated the justice of Mr. Doran's criticism: it was truly impossible to be absolutely certain that no ovarian tissue remained in the pedicle; this fact had been fully borne in mind, but the balance of evidence in this particular case was still in favour of external migration of the ovum. Here we were not dealing with an ovarian cystoma nor with inflamed appendages. A smooth, rounded, pedunculated dermoid tumour was discovered at the first operation; there was no difficulty in removing it, and it was improbable on the face of it that the removal was incomplete; moreover, the possibility of such a condition was discussed at the second operation, and a careful search failed to reveal anything like the remains of an ovary; further, a very thorough examination was made of the specimen after removal, again with a negative result. Mr. Doran very rightly distinguished between ovary and ovarian tissue, but in this case neither ovary nor ovarian

tissue could be found. The migration of the ovum may be regarded as an established fact—the evidence already quoted must surely be taken as proof—and since this is so it is only reasonable to believe that such is the explanation of the pregnancy in this case.

Dr. Eden said that he agreed in the main with the views advanced by Mr. Alban Doran. He thought it was impossible by any clinical examination, however careful, to exclude the presence of small portions of ovarian tissue in the ovarian pedicle or between the layers of the broad ligament. Only by an exhaustive examination made at an autopsy could this exclusion be satisfactorily accomplished. He therefore regarded the first case recorded by the authors as affording no support to the theory of internal migration of the ovum. With regard to the second case he thought the method employed by the authors was faulty. Ligature of the base of a loop of the tube left the divided ends in juxtaposition, and when the ligatures had been absorbed the lumen might easily be restored. He had twice sterilised a patient with a satisfactory result by the following method: Two silk ligatures were applied to the tube about one and a half inches apart, the intermediate portion was then cut away and each end closed over with peritoneum in the way surgeons closed over the stump of the vermiform appendix. He did not think it was possible for the lumen of the tube to be restored after this operation.

Dr. Herman thought there was abundant evidence that the ovum might traverse the peritoneum from one ovary to the opposite tube. There was also some evidence that an ovum might traverse the uterus and get from one tube into the other.* Knowing that ligature of the tube did not ensure sterility he had endeavoured to sterilise patients after Cæsarean section by removing the tubes altogether, tying the stumps close to the uterine cornu, and so far he had not heard of any patient so treated becoming pregnant.

The President said that his experience in some cases of Cæsarean section and myomata had shown the difficulty of efficient sterilisation by ligaturing the Fallopian tubes. Simple ligation, and even cutting out a piece of the tube had been proved to have failed in the object sought. It had been shown that the best method is to excise a wedge-shaped piece of the broad ligament, including the tube, near to the cornua of the uterus. In cases of Cæsarean section this plan has been more readily carried out when the incision has been made transversely in the fundus instead of the usual longitudinal one.

* See Hassfurther, quoted by Leopold, 'Arch. für Gyn.,' Band xvi, s. 27; and Schaeffer, 'Zeitsch. für Geb. and Gyn.,' Band xvii, s. 13.

Dr. Galabin said that he was interested in the demonstration given in the paper that the method of excising a portion of each tube was not an absolutely certain one of preventing future pregnancy. In future he should add to his plan of excising in conical shape the mucous membrane of the end of the tube left attached to the uterus the application of a stitch to close the opening. But he had not yet met with any case of pregnancy in patients whom he had treated in this way. He thought with the authors of the paper that external migration of the ovum was much the more probable explanation of their first case. He thought that this view was really supported by the cases quoted by Mr. Doran, in which pregnancy had occurred after removal of all the tubes except the small stump left attached to the uterus. If such a stump without any fimbriated extremity could produce enough ciliary current in its neighbourhood to pick up the ovum it seemed still more likely that when the fimbriated extremity was intact it might readily attract an ovum of the opposite side which had escaped just beyond the range of the ciliary current of the tube of its own side. Such an occurrence was probably not uncommon.

Dr. Boxall said that even in healthy conditions of the pelvic organs he found no difficulty in accepting the possibility of transmigration of the ovum in the abdominal cavity from the ovary on one side to the tube on the other. The relation of the parts *in situ*, with the abdomen unopened, is very different to what is observed either on the *post-mortem* table or at an operation. With the pelvic organs and intestines closely applied in what is, under ordinary circumstances during life, a potential cavity only, it is quite easy to imagine how the ovum, floating about like a drop of oil, might readily find its way from one ovary to the abdominal ostium of the Fallopian tube of the opposite side, and so be swallowed; or, for the matter of that, find its way into an opening in the tube which has resulted from its severance.

Dr. Cullingworth said he was about to make a very similar remark to that made by Dr. Boxall as to there being no great difficulty in accepting the theory of external migration of the ovum. In view of the numerous cases in which, when operating for inflammatory disease of the uterine appendages, the appendages of the two sides are found firmly united to each other behind the uterus, he would go even further than Dr. Boxall, and say that the ovaries and abdominal ostea of the Fallopian tubes not only lie within a much more contracted area than appears to be generally supposed, but are not unfrequently in actual contact. If it be said that, in the operation cases alluded to, the conditions are those of disease, he would reply that the *position* of the parts was not likely to have been altered by the

disease, and that there had probably already been contact where there was now actual adhesion. Writers spoke of the ovum travelling across the peritoneal cavity, and conveyed the impression of a long and almost inconceivable journey, whereas the ovum might merely have to step in next door.

Mr. Harrison Cripps replied.

TWO CASES OF ABDOMINAL HYSTERECTOMY FOR FIBROIDS, COMPLICATED BY PREGNANCY; WITH SPECIMENS.

By Florence N. Boyd, M.D.,
SENIOR SURGEON TO THE NEW HOSPITAL FOR WOMEN.

(Received November 21st, 1903.)

(*Abstract.*)

Case 1.—A woman of forty-two was first seen by the writer when two and a half months pregnant. There was a mass in the abdomen reaching up to the umbilicus on the left (pregnant fundus), and out to the iliac fossa on the right (hard fibroids); the cervix was thrust to the front by a hard fibroid in Douglas's pouch, almost filling the pelvis. This pelvic fibroid was pushed up, and a ring inserted. The tumour tended to fall back, and at the end of pregnancy was found to be no longer replaceable and very tender, and to obstruct the entry of the presenting vertex into the brim. After consultation, a Porro-Cæsarean section was decided on, and presented no difficulty. After delivery of a living child the pelvic fibroid was found to be pedunculated and fixed by adhesions, which were separated, and the uterus and fibroids removed by supra-vaginal amputation; the stump was treated retro-peritoneally by suture. The patient, who did well for two days, died on the third day, with great acceleration of pulse and marked distension of the abdomen.

The *post-mortem* showed local peritonitis at the site of adhesion, to which a coil of bowel was attached; cultures from the blood and peritoneal fluid proved sterile. It is suggested that death was due to hampering of a weakened heart by over-distension of intestine above the adherent coil, and that con-

sequently an earlier myomectomy before the tumour became adherent might have given a better result.

Case 2.—A I gravida of forty-one, with multiple fibroids before marriage, came again under care when three months pregnant. The uterus, beset with fibroids, reached above the umbilicus, and from the pelvis a right-sided intra-ligamentous fibroid could be felt displacing the cervix. Five weeks later development of the uterus was noted to be proceeding towards the posterior wall. Owing to the obstruction of the intra-ligamentous fibroid, and the doubtful possibility of development of a living and undeformed child, the question of operation at this stage or at term was discussed, and decided in favour of the former as involving less risk for the mother. The uterus was removed entire by supra-vaginal amputation, and the patient recovered well.

The specimen shows thinning of the posterior uterine wall, suggesting the possibility of rupture had development proceeded, and a low implantation of the placenta on an intra-mural fibroid, which must have led to hæmorrhage in the course of spontaneous labour.

Case 1.—Mrs. P—, aged 42, was admitted to the New Hospital for Women, January 28th, 1902. Her history in brief was as follows: Married four years; no children; one supposed early miscarriage in May, 1901. Before, and since, the periods had been regular and profuse, with rather less than three weeks' interval until October 18th, 1901; from that time amenorrhœa. Up to six years ago she had suffered from dysmenorrhœa, but that symptom had declined. For some months she had had a sense of pressure in the rectum and some irritability of the bladder. She was sent into the hospital for an opinion as to treatment by Miss Aldrich-Blake, M.S., under whose care she had been for the previous six months. Miss Aldrich-Blake first saw her after the supposed miscarriage, when the patient was losing freely, and noted then the presence of a couple of fibroids in front, and one, pedunculated, occupying Douglas's pouch and retroverting the uterus. She noted a faint systolic murmur at the cardiac apex but no albuminuria. She had suggested myomec-

tomy, owing to the trouble experienced from pressure on the rectum and bladder. This the patient declined. In January, 1902, she found her two and a half months pregnant, and the pelvic fibroid, as well as the whole mass of the uterus, markedly increased in size. She then recommended her to come into hospital for consultation as to treatment. The patient's friends, wishing for an independent opinion, took her to see Dr. Amand Routh, who kindly wrote to Miss Aldrich-Blake his opinion of the case, which was, that she was certainly pregnant, and that an attempt should be made to push up the fibroid. Should that fail, he thought Cæsarean section at term might be necessary.

On admission.—The abdomen was prominent, and the lower part occupied by a tumour reaching on the left side up to the umbilicus, and on the right side out into the iliac fossa, irregular and bossy on the surface. Consistence on the left semi-cystic and elastic, while the bosses and portion in the right iliac fossa were hard. The left round ligament could be traced on to the main tumour, the right round ligament could be felt crossing the tumour in the right iliac fossa.

The cervix was thrust to the front and high up by a hard tumour almost filling the pelvis. Under anæsthesia this tumour was pushed up out of the pelvis to within four fingers' breadths of the umbilicus and a ring pessary inserted. The patient was told to adopt the knee-elbow position frequently. It was hoped that as the uterus increased in size the tumour would be drawn up out of the pelvis and that spontaneous delivery might be possible. The prospect of Cæsarean section with removal of the fibroid uterus at term, should reduction not occur, was explained to the patient, who agreed to keep herself under Miss Aldrich-Blake's observation.

Even before leaving hospital, the tumour tended to return into the pelvis, and Miss Aldrich-Blake reported from time to time that the position of the tumour was not satisfactory in spite of regular increase in the size of the

uterus. The patient was re-admitted on June 30th, 1902, three weeks before labour was due. General condition good, some signs of venous congestion about the face and legs, which had occasionally been swollen. Pulse good. Systolic murmur at base of heart, and cardiac area increased. Trace of albumen in the urine. The uterus filled the abdomen, and the head was found presenting, lying centrally above the pubes. The boggy mass of the placenta was felt to the left and fœtal parts on the right.

Per vaginam the softened cervix lay centrally, and less anterior in position than on the previous occasion; behind it, in Douglas's pouch, was a flattened firm tumour, very distinctly tender. The head lay entirely above the brim and could not in any way be pressed into it, owing to the presence of the tumour. In consultation with Mrs. Scharlieb and Miss Aldrich-Blake the advisability and possibility of pushing up the tumour were discussed and tried, care being taken not to use undue force, owing to the tenderness. These efforts were quite unsuccessful. It was thought that some inflammatory change had taken place in the tumour, and that forcible attempts at reposition might lead to serious injury or rupture of a softened portion. With this danger in view, Cæsarean section was decided on as involving less risk.

At the operation on July 19th the child was delivered alive by central incision of the uterus in the usual way, no amniotic fluid escaping into the peritoneal cavity. The uterus was then at once drawn outside the abdomen, and the placental edge was seen to bulge out at the left side of the incision, which had only just missed it. No attempt was made to separate it, but the uterine walls were well squeezed together; they contracted down on the placenta and no bleeding occurred. The main tumour was found to be a pedunculated fibroid of the posterior wall, the size of a large Jaffa orange, adherent to the lateral and posterior walls of the true pelvis. Close to it was a second fibroid the size of a large walnut, and the uterus was beset throughout with smaller fibroid nodules.

Consequently, all thought of myomectomy was abandoned, and the uterus, containing the placenta, with the fibroids was removed by the ordinary supra-vaginal amputation. A small piece of membrane occupying the cervix was dissected away, the cervical canal was disinfected with pure carbolic acid and closed in by suture, the cervix was dropped, and the peritoneum was closed over it with catgut suture. Both ovaries were left. The child, a male, was well-formed and weighed 9 lbs.

The pulse immediately after operation was 102 and rather feeble, but the patient rallied and did fairly well for the first two days, giving no real ground for anxiety, although the pulse remained over 100 and feeble, and there was a good deal of sickness for the first twelve hours. On the morning of the 21st, forty-eight hours after operation, the pulse failed markedly, and ran up from 130 to 160 and the patient complained of breathlessness. By noon the abdomen was much distended though moving well on respiration, the pulse feeble and irregular. Examination of the wound showed healing. A few stitches were removed and the peritoneal cavity opened, when a little clear orange-coloured fluid welled up; a rubber drainage tube was passed into the pelvis. There was no improvement in pulse or respiration after this, and there was still complaint of pain and discomfort at the chest; she died the same evening, fifty-eight hours after operation.

The *post-mortem* was unsatisfactory and inconclusive. There was no general peritonitis, but where the tumour was originally adherent a patch of localised peritonitis existed in the pelvis, and here a collapsed coil of small bowel was adherent. The lines of peritoneal suture were healthy. There was hardly any fluid in the pelvis, but cultures from it and from the blood proved sterile. There was nothing special in the heart or lungs to account for death, though both pleurae contained a small amount of blood-stained serum. What was the cause of death? Sepsis is always the first thing in one's mind in such a

case, and it was that suspicion on the third day that led me to establish drainage of the peritoneum, but the absence of general peritonitis and the result of the cultures negatived this. There was marked distension of intestine, due probably to the adherence of a coil in the pelvis, and I am inclined to think that this so hampered a feebly acting heart as to turn the scale against the patient. If so, she died indirectly as a result of the injury to the tumour from long-continued pressure during the later months of pregnancy. I note that in one of the cases reported by Dr. Amand Routh to the British Medical Association Meeting at Swansea adhesions were present, but the patient made a good recovery, and Hofmeier refers to two cases of Porro-Cæsarean section at term for adherent fibroids (one his own, one Schröder's) which both recovered well. Probably in my case there was some special weakness of the heart muscle leading to dilatation, as shown by physical signs before operation, and this may have been the determining factor in the fatal issue. I think that earlier operation (in this case myomectomy) would have given the mother a better chance, and the child at least a fair one. Since this paper was written, such a case has been reported by Dr. Maclaren in the 'British Medical Journal' of January 9th. I should be very glad to hear the views of other Fellows as to the cause of death in this case. It is the only death I have myself had in thirty-one abdominal hysterectomies for fibroids, and I do not remember to have seen an exactly similar case. Hofmeier, writing in the 'Zeits. für Geburts. und Gynäkol.,' in 1894, mentions a case of death from sudden heart failure seventeen days after delivery in a case of pregnancy complicated by fibroids, and notes that during the whole period of labour and of the puerperium there had been a very small and frequent pulse without other symptoms. This he thought might have been due to heart changes connected with the presence of fibroids.

The specimen, which has shrunk considerably in

preservation, shows a pedunculated fibroid springing from the posterior wall of the uterus low down, flattened by pressure, and rough and irregular from tags of adhesions. The right half of the anterior wall has been cut away to show the placenta *in situ* which is attached to the left anterior and lateral aspects of the uterus. The wall of the uterus is of about normal thickness at term, and is beset with numerous small fibroids.

Case 2.—Miss P—, giving her age as 29, consulted me first in January, 1901, for a lump in the abdomen and menorrhagia. Under an anæsthetic, the uterus was found to lie retroverted between two fibroids, one sessile at the anterior aspect of the left cornu, of the size of a small apple, while on the right side was felt another fibroid of the size of a Jaffa orange, which, though occupying the right and posterior aspects of the pelvis, could be pushed up out of it and the uterus restored to anteversion.

Under treatment (ergot, hamamelis, and bromides) the periods lessened and the uterus remained in anteversion. A year later menorrhagia recurred; there was some increase in the right-sided tumour, and the whole uterus was higher, giving reason to think that with further increase the whole mass would rise out of the pelvis and grow towards the abdomen. She consulted me about marriage. I thought that with severe menorrhagia and a growing tumour at the age of 29, operation would ultimately become necessary, while the dangers attending pregnancy would be great. Neither she nor her intended husband would give up the engagement. Consequently, following the lines indicated by Dr. Cullingworth in his paper "On Fibroids complicating Pregnancy" ('St. Thomas's Hospital Reports,' 1899, p. 395), I advised operation before marriage with a view to myomectomy or possibly hysterectomy, but I placed before her the alternative, in case of pregnancy occurring, of Cæsarean section and hysterectomy or myomectomy at term. She chose marriage with the attendant risks, chiefly because

she was really 10 years older than she told me, viz. 40, and she thought that pregnancy was out of the question.

Eighteen months later she was sent to me again by Dr. Lydia Leney, being, as she thought, three months pregnant. She was married in July, 1902, and the last period was March 21st—28th, 1903. There was marked irritability of the bladder and constipation, but her condition was otherwise good, for the menorrhagia had lessened after her marriage. A mass was found in the abdomen reaching to two fingers' breadth above the umbilicus and out to the line of the anterior superior spine on the left side. To the right of the umbilicus and two fingers' breadths below was a second rounded mass, the size of half an orange, below which the hand could be well pressed in.

The cervix lay far back and much displaced to the left by a third rounded firm mass occupying the right and anterior fornices; the upper limit of this mass could be felt bimanually above Poupart's ligament and below the upper right-sided tumour. All the tumours were fairly soft, but where they met in the hypogastrium was a softer and more elastic portion taken to indicate the position of the pregnant body of the uterus. Five weeks later the whole abdomen was more prominent, though the tumour was not higher—a condition evidently due to posterior development of the pregnant fundus, the anterior wall being blocked by fibroids. It was impossible to push the pelvic mass up out of the pelvis. I thought it was intra-ligamentous and would prove an absolute obstacle to spontaneous delivery. The question was one of operation now or at term. It was doubtful whether there was room for a living child to develop, and there was danger of injury to the growing pelvic fibroid from impaction. Under these circumstances I thought that a hysterectomy at the fourth month involved less risk to the mother than a Porro-Cæsarean at term. (In this opinion I was no doubt influenced by the fatal issue in the previous case.) The question of least risk to the mother was pressed upon

me very strongly by the husband, and seeing that this would involve the sacrifice of the child, I induced her to take a second opinion. She elected, fortunately, to see so eminent an authority as Dr. Cullingworth. He also doubted the possibility of her carrying a living child to term, and agreed that immediate operation involved less risk for the patient herself. Consequently, he suggested an exploratory operation, and recommended that should it prove possible to draw the tumour up out of the pelvis, the case should be allowed to go to term.

At the operation on July 29th, I found the pelvic tumour to be intra-ligamentous and immovable, and decided to remove the uterus by supra-vaginal amputation. The operation was quick and easy, the intra-ligamentous fibroid shelling out without difficulty after incision of the reflection of peritoneum over its upper part. The patient made an excellent recovery.

An examination of the specimen justifies, I think, the treatment adopted. It shows that spontaneous delivery at term would have been out of the question, owing to the situation and immobility of the lower fibroid; that the uterine cavity is limited and encroached upon by two of the fibroids, the lower one forming the floor of the uterine cavity; that the only portion of uterine wall free from fibroids is the posterior, towards which the fœtal sac is developing, thus giving rise already at the fourth month to marked thinning of this wall. Might this not have gone on to rupture? This is a possible though rare accident which was not alluded to by Dr. Amand Routh in the exhaustive account of the dangers of the complication of pregnancy with fibroids with which he opened the discussion at Swansea. One such case of rupture at the fourth month with the *post-mortem* specimen was recorded by Dr. Hogan ('American Journal of Obstetrics,' 1893, p. 305), at the fifth annual meeting of the Southern Surgical and Gynæcological Association. More recently, and since this paper was written, Ekstein has published a case of rupture in the

course of forcible delivery at term, but the condition of the uterine wall at the seat of rupture is not mentioned ('Monats. für Geburts. und Gynäkol.,' Bd. xviii, Ht. 5).

Finally, the specimen shows a dangerous implantation of the placenta in the lower uterine zone and over the area of an intra-mural fibroid, so that had the case passed into labour, hæmorrhage must have occurred early, from marginal separation of the placenta as the cervix expanded, and later, from the impossibility of retraction of the placental site. From all these considerations it is evident that operation would ultimately have been necessary on behalf of the mother. What is the probability of a fœtus developing to term and without deformity in such a case?

In this case I operated in contravention of the recognised rule, clearly stated by Landau (amongst others) in his paper on the treatment of this complication in 'Volkmann's Sammlung' (Gynæcol. Series, No. 9) and re-stated by Dr. Amand Routh in the paper above referred to—the rule that no operative interference should be undertaken during pregnancy unless urgent symptoms arise. My patient had certain pressure symptoms, frequency of micturition and obstinate constipation, but they did not in themselves call for operation. The grounds on which I acted were the comparative risk to the mother, and the improbability of a healthy fœtus developing to term. It seems to me, that Landau's statement that the prognosis for the mother is more favourable the later in the course of pregnancy a hystero-myomotomy is undertaken, is a little too sweeping, in view of the possible effects of pressure on the fibroid itself and on the uterus by distension of its cavity. And it is the question of risk for the mother that will frequently, where family is not strongly desired, guide the parents in the choice of operation, however it may be presented to them by the medical attendant. The possibility of development for the fœtus, too, is an important point, for it would be a sorry thing to persuade a patient to wait till term for an

operation which the position of the fibroid made inevitable, and go through months of anxiety and hope, only to deliver her in the end of a deformed or macerated fœtus.

Dr. Herbert Spencer had no doubt that both the cases shown by Mrs. Boyd required operation, but thought that in the second case it would have been better to wait and see whether the pregnancy could not be allowed to continue until the child was viable or even developed to term. Whether the uterus should have been removed in that case was perhaps doubtful; but in the case of a pedunculated tumour, such as one of Mr. Doran's cases, he thought the conservative operation of myomectomy was preferable.

Dr. Amand Routh congratulated Mrs. Boyd upon her paper, and thought that the main interest circled round the second case, where hysterectomy had been done in the fifth month of pregnancy. He had no doubt that the condition of the patient at the time justified the early operation, though he had never seen a case which could not wait for operation till the contained fœtus was viable. Before deciding to operate one must recall two facts, first that two lives were involved; and secondly, that any interference must be of a severe surgical nature, induction of abortion being nowadays advocated by none. If abortion were induced for an obstructing fibroid, it was probably impossible to efficiently empty the uterus, and it was entirely unjustifiable to induce abortion if the fibroid were not obstructive. He thought there were three groups of conditions in the early months of gestation in which surgical interference was practised, but they were rarely good reasons for such operations. The first group were those where obstruction was considered certain to be present at full term. The fallacy here was that a certain prognosis could not be made, for the vast majority of such fibroids were drawn up in late pregnancy or in labour itself. Moreover, if obstruction were certain, operation at term was just as easy and safe, and secured a living child. The second group was that in which cases were met with severe pressure symptoms, but Lewers and others had shown that pain in these cases was often tractable, and that such symptoms were often temporary. There should, therefore, always be reasonable delay before operating early. The third group comprised those where dangers threatened, and Kelly's dictum "That two lives are involved, and operating during pregnancy where there are no urgent symptoms, on account of dangers which may arise, has no field here" is true. The dangers usually feared are rupture of the uterus, hæmorrhage from the placental site, and deformity of the child. He had found no recorded instance of a spontaneous ruptured uterus, and Dr.

Hogan's case alluded to by the author was open to grave doubt, and might well have been one of secondary abdominal pregnancy after a ruptured tubal gestation. The hæmorrhage from the placental site was *post-partum* and not *ante-partum*, and, therefore, need not be considered, and he had not been able to find any case of fœtal deformity in these fibroid pregnancies. There was, further, no evidence in favour of a lower mortality in the earlier operation, the mortality of even myomectomy being 25 per cent. against 16·6 per cent. for supra-vaginal hysterectomy at full term. He, therefore, speaking generally, strongly advised waiting till full term unless very urgent symptoms were actually present.

Dr. Cullingworth said the decision in the second of Mrs. Boyd's cases had been arrived at only after the most careful consideration. There was room, of course, in such a case for difference of opinion, but he could not help thinking that objectors to the course adopted might have taken a different view had they had the opportunity of seeing and examining the patient. As his paper on the subject showed, he was strongly of opinion that interference with the course of pregnancy in these cases was seldom justifiable, and it was, therefore, with reluctance that he came to the conclusion that he did. He did not think, in spite of the statistics quoted by Dr. Routh, that it could reasonably be maintained that operation at term was safer than an earlier operation.

Dr. Lewers said that as regards the two cases of Cæsarean section he had performed for obstruction due to pelvic fibroids, he had seen both cases comparatively early in the pregnancy. Both cases had rather severe pain at that period, but it gradually passed off, and during the latter half of the pregnancy the patients were very fairly comfortable. He thought it only rarely justifiable in such cases to perform an abdominal hysterectomy in the earlier months of the pregnancy. By that treatment the child was of course lost, and the patient had to undergo a severe operation. He thought it much better when at all possible to let the patient go to full term, and then perform Cæsarean section. In that way the child was almost certainly saved, and the mother underwent no greater risk than if hysterectomy had been performed during the earlier months. He would go further and say that, when the fibroids were wholly or chiefly pelvic, and there was an otherwise fairly normal uterus, the operator should be content with performing a conservative Cæsarean section, leaving the pelvic fibroid, or fibroids, untouched. In his two cases the fibroids had given rise to no symptoms prior to the pregnancy, and he thought, therefore, that there was a very fair probability that afterwards they would cause no symptoms. He had, therefore, performed a conservative Cæsarean section in both cases, and left the fibroids

alone. So far in these two cases a year and a half, and sixteen months respectively, had elapsed since the operations, and he had not heard of the fibroids causing any trouble. In both his cases the children were well-developed and perfectly normal, and had thriven well up to the present.

Mrs. Boyd replied.

PREGNANT FIBROID UTERI REMOVED BY OPERATION.

Shown by Mr. Alban Doran.

These three specimens of uteri which Mr. Doran had removed for fibroid disease involving the posterior aspect of the lower segment in early pregnancy were exhibited in relation to Dr. Stanley Boyd's paper. In all, it would have been dangerous to push the lower part of the tumour above the pelvic brim, and in all the operation proved successful, and saved the patient from possible complications later in pregnancy.

He first referred to a specimen of pregnant fibroid uterus removed at the fifth month, which he exhibited before the Society in June, 1901,* in association with Dr. Archibald Donald's paper on "Fibroid Tumours complicating Pregnancy and Labour." The patient was a primipara, aged 40. The uterus lay between two large pedunculated fibroids, one obstructing the pelvis. The latter, as in all the specimens exhibited on this occasion, arose from the posterior part of the lower segment of the uterus. Pushing up this outgrowth would probably have caused rupture of the uterus, like a soft fruit pressed between two stones.

The patient was in good health last November, three years after the operation.

The specimens illustrating the second and third cases to which Mr. Doran desired to refer to-night had not been exhibited before the Society, but a full clinical report, with drawings, would be found in the 'Lancet.'†

The specimen, from the second case, showed a large

* 'Trans. Obst. Soc.,' vol. xliii, 1901, p. 178, and pl. xii; also "A Case of Hysterectomy for Uterine Fibroid in the Fifth Month of Pregnancy; Recovery," 'Lancet,' vol. i, 1901, p. 621. The specimen is preserved in the Museum of St. Bartholomew's Hospital, series xlvi, 3090 *c*.

† "Hysterectomy for Uterine Fibroid Disease in Early Pregnancy," 'Lancet,' vol. ii, 1902, p. 1451.

fibroid in the posterior part of the inferior segment of the uterus involving the cervix. Thus it was a true "cervical fibroid," as in the case* recently exhibited by Mr. Meredith, and not a fibroid in the parametrium behind the cervix, often incorrectly called "cervical." The patient was 39, married seventeen years. After nine abortions she bore a child to term, now living. Nearly six years later she again became pregnant. Severe attacks of pain set in, and the health deteriorated rapidly. Mr. Doran therefore removed the uterus above the cervix. The patient gained flesh during convalescence, and was in excellent health last January, two years after the operation.

The third case was illustrated by a specimen which Mr. Doran presented to the Museum of the Royal College of Surgeons (Path. Ser. A, 4724 *d*). There was a large fibroid in the lower segment posteriorly involving the cervix and opening up the broad ligament. There was also a subserous fibroid with a very distinct, narrow pedicle; it moved freely in the abdomen and was a feature which aided in correct diagnosis. The patient, aged 30, had been married but four months. In the earliest stages of this, her first pregnancy, there were severe attacks of hypogastric pain. Pushing up the mass was out of the question. Mr. Doran amputated the uterus in the fourth month. The fœtus was in poor condition, as Dr. F. N. Stanley Boyd remarked to be often the case; its nutrition seemed much prejudiced by the pressure of interstitial growths, which would have contra-indicated conservative Cæsarean section.

The patient was in good health nearly two years after the operation when Mr. Doran last saw her.

The fourth and last case was of special interest owing to two features, discussed in full elsewhere,† which caused

* Not gravid.

† "Hysterectomy for Fibroid Disease in Pregnancy: the Souffle and Muscular Contractions in Relation to Diagnosis," 'Edinb. Med. Journ.,' September 1903, p. 246.

difficulty in diagnosis. The patient was 30, married nine years; her two previous pregnancies had ended at the third month. On the third occasion a bilobed abdominal tumour developed. The right lobe was evidently a pregnant uterus, the souffle was distinct. The nature of the left lobe was uncertain before operation; a second souffle, quite distinct from the first, was audible almost in the middle line. The left lobe seemed to undergo contractions. Mr. Doran made an exploratory incision, and then discovered that the left lobe was a fibroid with a broad pedicle attached to the left side of the supra-vaginal portion of the cervix and lower uterine segment behind the left ovary and tube. The second souffle was caused by the left ovarian vessels rotated forwards by the growth so that they lay behind the linea alba, on the left border of the uterus. The sensation simulating contraction, on palpation of the left lobe, that is to say the tumour, must have been caused by contractions of the normal gravid uterine wall dragging on the pedicle of the tumour. Perhaps the fœtus might have been saved by delay to term, but the precise nature of the case was difficult to determine even during the operation, and altogether the operator thought that removal of the uterus and tumour was the safer course.

The patient was in good health fifteen months after the operation.

As the management of the ovaries was a much disputed question, it was noted that in the first case (exhibited in 1901) both ovaries were removed, in the second both were sacrificed as they showed marked signs of cystic degeneration, in the third both were saved, whilst in the fourth both were removed. In the three cases where both ovaries were removed (ages 40, 39, 30), the suppression of the catamenia was immediate, yet in no case did troublesome menopause symptoms ensue. In the third case (aged 30), where both ovaries were saved, the period became irregular and disappeared altogether, after an attack of menorrhagia, in about fifteen months.

The patient for some time afterwards complained that she often felt "queer all over."

In conclusion, it seemed clear from the relations of tumour and uterine cavity in these specimens, that when a large fibroid developing in the posterior part of the lower segment was detected in early pregnancy, as in Dr. Stanley Boyd's case, hysterectomy was the best treatment.

DEGENERATED FIBRO-MYOMA WEIGHING OVER SEVENTEEN POUNDS ENUCLEATED FROM THE BROAD LIGAMENT NINE HOURS BEFORE DELIVERY AT TERM.

(With Plate VI.)

Shown by Dr. Herbert R. Spencer.

Dr. Herbert Spencer showed a degenerated fibro-myoma, the solid part of which weighed 17 lbs. 14 oz., which he had removed nine hours before delivery from a patient who was pregnant at (or a few days beyond) full time. Although he had seen a considerable number of pregnancies complicating uterine fibroids, this was the only case but one in which he had found it necessary to operate during pregnancy. The other case (treated by Cæsarean section) had been already published in the 'Transactions' (vol. xxxviii, p. 390). Tumours which encroached on the pelvis in the early months were often drawn up at the end of pregnancy or in labour. He was of opinion that operations in the early months and mutilating operations were by far too frequently performed in cases of fibroids complicating pregnancy.

The specimen showed that even at full term a very large tumour might be successfully removed by the operation of myomectomy.

DESCRIPTION OF PLATE VI,

Illustrating Dr. Herbert Spencer's specimen of Fibromyoma weighing over 17 lbs., removed by myomectomy at term.

The section measures 1 foot in diameter; before removal it was much larger, several pints of fluid and jelly having escaped on incision at the operation. Degenerated areas are shown by the grey shading, and many slit-like and irregular cavities are seen, some filled with coagulated fluid. A large cavity at the upper part is indicated by the wrinkled surface. Hæmorrhage into the degenerated tissue has occurred at one spot in the centre of the left half of the tumour. Microscopically the tumour is a fibromyoma which has undergone myxomatous degeneration. The cavities have no epithelial lining.

Illustrating Dr. HERBERT SPENCER's specimen of Fibro-myoma, weighing over 17 lbs., removed by myomectomy at term.

Bale & Danielsson, Ltd.

The tumour measured 12 inches by 12 inches by 4 inches, and the solid part of the tumour weighed 17 lbs. 14 oz., but in its recent state it was much larger, several pints of straw-coloured fluid and jelly-like material having escaped on incision at the operation. It was a fibro-myoma which distended the left broad ligament, but probably originated in the left wall of the uterus. It had undergone myxomatous degeneration, and in one spot slight hæmorrhage had occurred into the degenerated tissues. Microscopic examination of the cavities resulting from the degeneration showed that they had no epithelial lining. The left ovary, which was also removed, was somewhat enlarged and stretched but distinct from the tumour.

The history of the case is as follows :

E. B—, aged 41, the mother of four children, was admitted to University College Hospital on May 4th, 1901, complaining of enormous swelling of the abdomen ; she was also pregnant at full term. She had had four children ; at the last labour twins, six years ago. The labours were all normal, and the patient had never aborted.

She began to menstruate at 14, was fairly regular, bled for four to five days, using four diapers. Menstruation was accompanied by a feeling of fulness in the lower part of the abdomen, but no pain. She last menstruated on July 29th, 1900.

She first noticed considerable enlargement of the abdomen two years ago ; this gradually increased and was accompanied by a feeling of weight. She had had no pain. The bowels had been confined, micturition and the urine were normal. She had been very healthy all her life. She says she always noticed that her abdomen did not go flat after her labours.

On admission the patient was enormously stout, the tongue clean, pulse 80, breasts typical of advanced pregnancy, the heart-sounds strong, the breath-sounds normal. The abdomen was enormously distended, the girth at the umbilicus being 54 inches (27 inches on each side). From the ensiform cartilage to the pubes measured

26 inches. From the umbilicus to the anterior superior iliac spine measured on the left side 10 inches, on the right side 11½ inches. The abdomen was dull to percussion except in the epigastrium and far back in the left flank.

The great distension of the abdomen was due to two tumours, of which the right (the pregnant uterus at term) was rather firmer than the normal uterus at term; in it the fœtus and contractions could be felt with some difficulty, but neither uterine souffle nor fœtal heart-sounds were heard. The tumour on the left side of the abdomen was about twice as big as the uterus and clearly fluctuated. It was thought to be an ovarian tumour.

The vagina was of a blue colour, the cervix soft and patulous, and through it the fœtus could be felt. The tumour could be felt on the left side of the cervix and encroached upon the pelvic brim, but did not descend into the small pelvis.

On May 9th, as the patient had gone over term (284 days) and the heart-sounds could not be heard, abdominal section was performed and the tumour removed from the left broad ligament through a long median incision. The veins between the tumour and the uterus were very large, several as thick as a forefinger. After tying the ovarian vessels the broad ligament was split and the tumour easily enucleated; afterwards several veins were tied with fine silk. The cavity, which still oozed a little, was packed with iodoform gauze, which was brought out through the lower inch of the wound. The rest of the wound was closed with silkworm gut through stitches, silk fascial sutures, and horsehair sutures for the skin. The operation lasted sixty-three minutes, and was followed by some shock. Eight and a half hours afterwards the patient had not noticed labour pains, but on attempting to pass a catheter the assistant found the child's head in the vagina, and the child was born shortly afterwards. It was dead but seemed fresh. It was 21 inches long and weighed 6 lbs. 2 oz.

The gauze was removed next day and replaced by a tube. The patient made a good recovery. The wound healed by first intention except where the tube had been. On May 27th she had pains in the left leg, and a thrombus formed in one of the veins. On June 18th the wound was soundly healed except a granulating spot as big as a pea where the tube had been.

After the operation the temperature did not reach 100° till May 27th, when it reached 101°; it was below 100° after May 31st, and only twice reached 98·8° after June 6th. She was discharged quite well on July 5th, the left leg being still a little swollen.

APRIL 6TH, 1904.

EDWARD MALINS, M.D., President, in the Chair.

Present—48 Fellows and 6 visitors.

Books were presented by Guy's Hospital Staff, the Société de Médecine de Rouen, Dr. Bernhard S. Schultze, and Dr. J. Whitridge Williams.

The following candidate was proposed for election:—Harry Oliphant Nicholson, M.D.Ed., M.R.C.P.Ed.

The following gentlemen were elected Fellows of the Society:—R. Drummond Maxwell, M.B.Lond.; Asa Claude Van Buren, M.B., B.S.Lond.

FORTY-ONE CASES OF PUERPERAL ECLAMPSIA TREATED BY THYROID EXTRACT.

By Lieut.-Col. A. J. STURMER, I.M.S.

MY attention was first drawn to the treatment of puerperal eclampsia by thyroid extract, in an article in the 'Journal of Obstetrics and Gynæcology of the British Empire' for July, 1902, by Dr. H. O. Nicholson, and as our mortality in this disease has always been high, I

determined to try it. I commenced the treatment in September, 1902, and continued it throughout 1903. To all cases of eclampsia the extract was given; there has been no picking of cases.

I may state that no fair comparison can be made between patients in the United Kingdom suffering from eclampsia and those in India; the balance is always greatly in favour of the former. In India, patients come from long distances, being transported in springless carts over bad roads, or those living in towns are first treated by ignorant quacks—they are made to sit over hot ashes, or pungent aromatics or peppers are burnt under their noses, or they are cauterised. So, if our results are good (and I think it will be admitted they are), a stronger term should be applied when comparing the results in the East and in the West.

On looking back at the results of treatment and the mortality, I find—In 1871: No. of cases, 16; recoveries, 9; deaths, 7, or 44·4 per cent. In 1881: No. of cases, 15; recoveries, 8; deaths, 7, or 46·6 per cent. In 1891: No. of cases, 23; recoveries, 21; deaths, 3, or 13 per cent. In 1901: No. of cases, 25; recoveries, 14; deaths, 11, or 44 per cent.

In 1871 tinct. veratrum was given in fifteen minim doses every quarter of an hour for nine doses. Potassium bromide was also given, grains 15, repeated every second hour. When the pulse fell to 60 the former was omitted, but administered again if it rose to 100.

In 1881 veratrum was given in large doses by the mouth, or if the patient could not swallow, by the rectum. It was administered in sixty minim doses twice, at intervals of two hours; then, if required, ten minims in a diaphoretic mixture were given every third or fourth hour.

In 1891 reliance was placed on chloral and bromide, and, as in former years, chloroform was given to mitigate the spasms.

In 1901 the treatment consisted in the injection of morphia, grain one-half, at intervals, and in those cases in

which the secretion of urine was deficient saline injections were resorted to. No chloral or bromide were given, and chloroform was inhaled only when something had to be done for the patient, *e.g.*, passing a catheter.

It must also be remembered that a certain number of the patients are admitted annually in a moribund condition, for whom no treatment is of any use; there may be more one year than the next, but in the percentages I have counted all cases, whether moribund on admission or not.

Under the thyroid treatment, a patient on admission suffering from eclampsia is given ten grains, and five grains are administered every four hours afterwards. Should the urine be scanty, a saline injection of one or two pints is given under the breast or into the axilla, and a hypodermic injection of morphia, half a grain, is also administered, and repeated if necessary in two hours. Some of the cases, with a history of fits on the road or at home, who come walking into the labour ward, are only given thyroid and watched; the urine is either drawn or passed, and should it be full of albumen or very scanty, a saline injection is also given—on the least sign of restlessness a hypodermic injection of morphia is given. Should, however, a patient show signs of great œdema of the lungs, or should the urine be free from albumen and passed in large quantities, the saline is omitted.

From 1870 to 1903 there have been three hundred and sixty-nine cases of eclampsia treated, and of these one hundred and six have died or been removed by their friends in a dying condition; this gives a mortality of 28·7 per cent. One year, 1890, is omitted, as I can find no records.

When I first joined the Service in 1875 I was ordered to do duty under Dr. W. H. Harris, who was at the time in charge of the Lying-in Hospital. Dr. Harris was of opinion that eclampsia was due to the condition of pregnancy, and that the sooner this was ended the better for the patient. The line of treatment adopted, therefore, was to hasten delivery, if labour had commenced—if not,

to induce labour by rupturing the membranes, and dilating the cervix by Barnes' bags. How antagonistic this was to the teaching of the day and for long afterwards will be seen from the extracts given below, which have been extracted from the text-books. Opinion seems to have changed, for now it is urged that the cervix should be dilated, and delivery accomplished as soon as possible. The practice of Dr. Harris was carried on by Col. Branfoot, during his tenure of office, and has been steadily persevered in since I have been in charge. We have, moreover, taught our students that in eclampsia labour should either be induced, or the forceps, version or cephalotripsy should be employed to expedite delivery. Looking at the results of this line of treatment, either with veratrum, or with chloral and bromide, with or without chloroform, I cannot say that the results have been very good—except in 1891, when the mortality was 13 per cent.—whereas, since the thyroid treatment has been adopted, in addition to morphia and saline injection, the mortality has only been 12·2 per cent. Forty-one cases are very few, I acknowledge, on which to base a line of treatment, but I am continuing this treatment, and shall have probably by the end of the year another twenty or more cases to add to the list.

Under morphia and saline infusion the mortality decreased, but it was not wholly satisfactory. The injection of saline did not cause any great increase to the flow of urine until after twenty-four hours had elapsed, whereas we have found that with 30 to 40 grains of thyroid given in the twenty-four hours, the urine after the first two or three doses has showed a considerable increase, and by the end of twenty-four hours, a very large increase has been noticed.

The hypodermic injection of morphia, it has been noted, has a considerable effect on the child—I allude, of course, to those cases which are some time in an eclamptic state before delivery, and to whom more than one injection of morphia has been given—the child is very somnolent, it breathes

badly, and it is often born in an asphyxiated condition, and considerable time has to be spent before it can be made to breathe sufficiently well to dilate the air-sacs; and not all such children are premature.

We admit cases of diseases of pregnancy, and to those suffering from anasarca with albumen in the urine, thyroid has been given. It has certainly had a great effect on the secretion of urine. The symptoms of giddiness, and disordered vision, and vomiting, have passed away under its use, and in one case the urine increased from a few ounces to a hundred and twenty in the twenty-four hours.

Whether it should be given to every case will have to be proved by experience, for it seems hardly likely that a patient who passes large quantities of urine which contain no albumen can be suffering from the same type of disorder as the patient who passes only a few ounces, black with blood, and loaded with albumen. The type of convulsion also varies very considerably: one patient may have only one or two fits, she then becomes comatose, and never regains consciousness and dies, whereas another may have forty, and become conscious after each, and recover without a bad symptom. A great deal has yet to be learnt about this disorder, but I only wish to give my experience—so far as it has gone—with the treatment with the extract of the thyroid gland. Extracts from various authorities:

'Meadows's Midwifery,' 4th edit., 1882.—"Not until labour has begun and advanced to full dilatation of the os should any attempt be made to expedite delivery. The whole practice of forcibly dilating the os for the purpose of effecting speedy delivery is now happily exploded, for the consequences of such a proceeding could not be otherwise than mischievous." But he says later, if the parts are undilated and unyielding, the measures for securing dilatation should be had recourse to, as in the case of rigidity of the os uteri, and no attempt at delivery should be made until the parts are sufficiently dilated to admit of it.

Galabin, edit. 1886.—"Accelerate labour, puncture the membranes, if the patient is seen when in labour use bags, apply forceps or turn, or craniotomy if the child is dead."

Galabin, 5th edit., 1900.—"Patient not in labour, in a mild case give purgatives, etc. If severe, lose no time in inducing labour. If in labour, accelerate."

Playfair, 1876.—"If therefore the os be undilated and labour have not begun, no active means to induce it should be adopted, although the membranes may be ruptured with advantage, since the proceeding tends to no irritation. Forcible dilatation of the os, and especially turning, are strongly contra-indicated."

Playfair, 9th edit., 1898, affirms what he has already said in former editions.

Lusk, 1884.—"After the advent of labour pains, catheterisation of the uterus. Water bags if necessary. Incisions and accouchement forcé are unnecessary. After the first stage, forceps, but obstetrical aid is only warrantable where it can be employed without detriment to the mother."

Jardine, 'International Clinics,' vol. ii for 1901, gives the practice of the Glasgow Maternity Hospital. He states that each case must be judged on its own merits, but broadly speaking the less interference with the uterus the better, in the case of convulsions which occur before labour sets in. If the fits cannot be controlled, the uterus should be emptied by rapid dilatation, the cervix may be incised; where the os is quite dilatable enough, delivery should be expedited.

Dakin, edit. of 1897, in his epitome of treatment, recommends the rupture of the membranes followed by dilatation of the cervix, and assisting labour by forceps, etc.

From the above it will be seen that Dr. Dakin is the only one who advocates immediate action, and this agrees with our practice; all the others appear to be rather undecided in the line of treatment to be adopted, and thus valuable time may be lost.

From the tabular statement appended it will be seen

Forty-one Cases of Puerperal Eclampsia Treated with

Number.	Number of pregnancy.	Duration of pregnancy.	Number of fits before delivery.	Number of fits after delivery.	Urine. Quantity.	Albumen.	Injection of morphia.	Injection of saline.
1	2nd	Full term	2	1	Scanty	Loaded	Yes	Yes
2	1st	Full term	1	—	Scanty	Loaded	Yes	Yes
3	1st	8 months	3	—	—	$\frac{1}{2}$	Yes	Yes
4	1st	Full term	2	3	Free	Present	Yes	—
5	1st	7 months	3	—	—	Loaded	Yes	Yes
6	1st	8 months	4	1	Free	$\frac{1}{2}$	Yes	—
7	1st	Full term	5	—	—	None	Yes	Yes
8	1st	6 months	6	—	—	Solid	Yes	Yes
9	12th	Full term	3	2	—	None	Yes	—
10	1st	Full term	—	8	Average	None	Yes	—
11	1st	Full term	6	—	Very scanty	Solid	Yes	Yes
12	2nd	Full term	—	4	Average	?	Yes	—
13	10th	7 months	6	—	Scanty	Loaded	Yes	Yes
14	1st	7 months	4	—	Scanty	$\frac{1}{2}$	Yes	Yes
15	1st	Full term	—	1	Scanty	$\frac{1}{3}$	Yes	—
16	2nd	Full term	3	—	Scanty	$\frac{2}{3}$	Yes	Yes
17	1st	Full term	9	—	Scanty	Trace	Yes	Yes
18	1st	Full term	3	5	Free	$\frac{1}{2}$	Yes	Yes
19	1st	Full term	—	5	Free	None	Yes	—
20	1st	8 months	8	3	Scanty	$\frac{1}{8}$	Yes	Yes
21	1st	8 months	6	—	Very scanty; like porter	Loaded	—	Yes
22	1st	Full term	1	—	Scanty	Trace	Yes	—
23	1st	Full term	5	3	Scanty	$\frac{1}{8}$	Yes	—
24	1st	Full term	—	1	—	$\frac{1}{8}$	Yes	—
25	1st	Full term	1	1	Free	$\frac{1}{8}$	Yes	—
26	1st	8 months	2	14	Very scanty	$\frac{1}{8}$	Yes	Yes
27	1st	Full term	11	7	Free	None	Yes	—
28	1st	Full term	1	—	Scanty	$\frac{1}{4}$	Yes	—
29	4th	Full term	3	—	Very scanty: black	Solid	Yes	Yes
30	1st	Full term	Many at home, 10 in hospital	—	Very scanty; like porter	Nearly solid	Yes	Yes
31	1st	Full term	1	3	Free	None	Yes	—
32	1st	Full term	6	9	Scanty	Trace	Yes	—
33	1st	Full term	2	2	Scanty	Trace	Yes	—
34	6th	Full term	7	2	Scanty	Loaded	Yes	—
35	1st	Full term	1	—	Free	None	Yes	—
36	1st	Full term	Several at home, 1 in hospital	—	Average	None	Yes	—
37	1st	Full term	8	5	Free	$\frac{1}{2}$	Yes	—
38	1st	8 months	8	1	Very scanty	Solid	Yes	—
39	1st	8 months	11	—	Very scanty	$\frac{1}{2}$	Yes	Yes
40	1st	8 months	15	9	Very scanty	$\frac{3}{4}$	Yes	—
41	2nd	Full term	1	—	Very scanty; bloody	$\frac{1}{2}$	Yes	Yes

Thyroid Extract, with the Subsidiary Treatment.

Delivery.				Stay in hospital.	Result mother.	Result child.	Remarks.
N. P.	Rupture of membranes.	Barnes' bags.	Forceps, etc.				
Yes	Vagina packed with gauze	—	—	17 days	R.	Alive	Child died on 2nd day.
—	Yes	—	Forceps	25 days	R.	Alive.	
—	—	Yes	Forceps	40 days	R.	Alive.	
—	—	—	Forceps	14 days	R.	Alive.	
—	—	Yes	—	26 days	R.	Macerated.	
Yes	—	—	—	19 days	R.	Alive	Child died on 2nd day: was premature.
—	Yes	—	Forceps	25 days	R.	Alive.	
—	Yes	—	—	17 days	R.	Still	Premature.
Yes	—	—	—	10 days	R.	Alive	Child died on 3rd day.
Yes	—	—	—	11 days	R.	Alive.	
—	—	—	Forceps	13 hrs.	D.	Still	Moribund on admission.
Yes	—	—	—	12 days	R.	Alive.	
—	—	—	Forceps	24 days	R.	Macerated.	
—	Yes	—	—	17 days	R.	Still	Child premature.
Yes	—	—	—	11 days	R.	Alive.	
—	—	—	Forceps	28 days	R.	Macerated.	
—	Yes	—	Cephalotripsy	16 days	R.	Still.	
—	—	—	Forceps	13 days	R.	Still.	
Yes	—	—	—	14 days	R.	Alive.	
—	—	Yes	Forceps	17 days	R.	Alive	Asphyxiated; died on 2nd day.
—	—	—	Cephalotripsy	18 hrs.	D.	Still.	
—	—	—	Forceps	17 days	R.	Alive.	
Yes	—	—	—	16 days	R.	Alive	Child died 2nd day.
Yes	—	—	—	14 days	R.	Alive.	
Yes	—	—	—	14 days	R.	Still.	
Yes	—	—	—	15 days	R.	Alive	Premature; died 2nd day.
Yes	—	—	—	15 days	R.	Alive.	
Yes	—	—	—	12 days	R.	Alive.	
Yes	—	—	—	2 days	D.	Still.	
—	—	Yes	Cephalotripsy	6½ hrs.	D.	Still.	Moribund on admission.
—	—	—	Forceps	16 days	R.	Alive.	
—	—	Yes	—	13 days	R.	Alive.	
—	—	—	Forceps	27 days	R.	Alive	Mother unconscious for 3 days.
Yes	—	—	—	14 days	R.	Alive.	
—	—	—	Forceps	29 days	R.	Alive.	
—	—	—	Forceps	23 days	R.	Alive.	
—	—	—	Forceps	24 days	R.	Alive.	
—	—	—	Forceps	23 days	R.	Still.	
—	Yes	Yes	—	23 days	R.	Alive	Premature; died on 2nd day.
—	—	Yes	Forceps	14 days	R.	Alive	Died 2nd day.
—	—	—	Forceps	5 days	D.	Still.	

that twenty-seven of the children were born alive, and of these eight died within three days after birth. Fourteen children were born "still," and of these three were macerated. It is curious that in the list there is no case of twin-birth. Of the classes of patients, two were Eurasians, one was a Mahomedan, and thirty-eight were Hindus; under this last term are included native Christians, Pariahs, and caste people. Probably fewer Mahomedans resort to the hospital as it is not a "Gosha" one, for I do not believe they are any the less prone to this disorder than the rest of womankind. Thirty-three out of the forty-one cases occurred among women for the first time pregnant, or 80·5 per cent.

The following are the notes of the fatal cases:

1. A caste woman, aged 20, admitted at 5.50 a.m., full term, history of three fits at home, swelling of the hands and feet for the past two months. Temp. 97°. Cervix admits a finger, membranes absent, half drachm of urine drawn, loaded with albumen, abdomen distended, the whole body swollen. 12.30: Dilatation complete, forceps applied, still child delivered, breathing very bad, respiration stopping every ten seconds, cyanosis, great œdema of lungs. Died at 7 p.m.

2. A caste woman, aged 18, admitted 7.50 p.m., unconscious, history of six fits at home. Temp. 104°, breathing stertorous, urine drawn four ounces, bloody. External os admits two fingers, membranes separated all round. Next morning patient delivered by cephalotripsy, premature child. Died at 2 p.m. Had no fit after admission, and never regained consciousness. Urine the colour of porter.

3. A caste woman, aged 26, fourth pregnancy, admitted at 11.30 a.m., full term, os admits two fingers. While asleep at 2.30 seized with an eclamptic fit; urine solid with albumen. At 6.30 a fit lasting a minute, at 10.20 child born, preceded by a fit. No fit after confinement. Only five ounces of urine drawn. Patient never regained consciousness, and died next day at 10.30 a.m.

4. A caste woman, aged 18, admitted at 4.20 p.m.,

semi-conscious, said to have had several fits at home. Feet swollen since her fifth month, is now at full term. Six ounces of urine drawn, very dark, full of albumen. Fits frequent. Barnes's bags under chloroform 9.30 p.m., no urine in bladder, cephalotripsy performed, delivery effected, but patient expired at 11 p.m.

5. Pariah, aged 22, semi-conscious on admission, œdema of feet and vulva, membranes ruptured at 4 a.m. Admitted at 11.30 a.m., in labour since 11 a.m. yesterday. One ounce of urine withdrawn, coloured with blood. No history of fits at home, but one soon after admission. Head in the cavity, forceps applied and delivery easily effected. She had no fit after delivery and became quite conscious, but albumen was present in her urine until the end. She had been freely handled outside before admission, and really died on the fifth day of septicæmia; her death ought not to be put down to eclampsia, but as she was admitted for this complaint, her death in the records comes under this head.

It has been remarked that most of the cases occur on dull and cloudy days; the reason of this is probably that as the day is cooler the skin does not act so well, and the eclamptic seizure is anticipated. We are always on the look-out on a cloudy day for a case. It would be interesting to know whether on a more than usually damp and wet day these seizures are more common at home.

Dr. Herman said that Lieut.-Colonel Sturmer had shown that among the cases treated with thyroid extract the mortality was less than among the cases treated in a different manner in former years. But the treatment had not been with thyroid extract alone; morphia had also been given. This made it difficult to be certain that the good result was due to the thyroid. There was one feature of these cases that pointed in this direction, viz. the rapid restoration of the urinary excretion which followed the giving of thyroid. When in eclampsia the urinary excretion began to increase it was one of the most trustworthy indications that the patient was going to recover; and the fact that when thyroid was given the quantity of urine became quickly augmented was a reason for thinking that this preparation was beneficial.

Dr. Boxall said that he had found eclampsia very prevalent in the West Indian Islands and one of the chief causes of death in connection with child-birth. This undue prevalence was unhesitatingly attributed by the doctors on the spot to malarial influence.

Dr. Oliphant Nicholson wished first of all to thank the Society for giving him the opportunity of being present and of taking part in the discussion. The use of thyroid extract in the treatment of eclampsia had been so limited that one could not yet form any very definite conclusions about its value. There was a good deal of evidence—both clinical and experimental—in support of the view that a thyroid insufficiency might be responsible for the appearance of certain acute symptoms during the course of pregnancy. Richon and Jeandelize in a recent communication had described the case of a rabbit where they removed the whole thyroid and two of the parathyroids during gestation. Labour came on prematurely and lasted about three days, four dead fœtuses being born. During the course of labour the animal was in a semi-comatose condition, and afterwards it became quite comatose and died. There was a remarkable lowering of the temperature with the onset of labour, and the scanty urine contained traces of albumen. The authors were greatly impressed by the analogy of the symptoms to those of eclamptic coma, and to uræmia without albuminuria. As regards the prophylaxis of eclampsia one of the most striking things, in his opinion, was the remarkably beneficial results obtained when the patient could be kept on an exclusive milk diet. The relationship of nitrogenous food to the thyroid secretion had been pretty fully investigated, and some of the results were highly suggestive. Thus a thyroidectomised dog very readily developed acute toxic symptoms when fed on meat, which symptoms disappeared when it was fed entirely on milk, and Horsley had noted that patients suffering from a hypothyroidism got on best upon a milk diet. In such cases it would appear that proteid food used up too much of the scanty supply of thyroid secretion, and that this form of diet likewise yielded very little iodine, which substance had been shown to be necessary to the gland for the elaboration of the active principle in its secretion. Dr. Nicholson had treated a number of cases of eclampsia or impending eclampsia by thyroid extract, and the results had been very encouraging; in all the severe cases, however, he always used morphia in addition, and used it with a very free hand. He thought the combination of these two remedies provided the best means of medical treatment in eclampsia. In the case of the thyroidectomised rabbit above described it was a noteworthy point that the temperature became greatly lowered. He thought that was suggestive in view of the condition of the circulation which seemed to develop in women

who became eclamptic. There was a marked contraction of the smaller blood-vessels, and as this got more pronounced the secretion of urine ceased. In these cases, at an early stage, the quantity of urine might be largely increased, but later on, when the constriction affected the renal arteries, and thus virtually shut off the blood supply to the glomeruli of the kidney, urine could not be secreted. Whether a deficient thyroid secretion was responsible for this or not he could not say, but he had no doubt whatever about the action of very large doses of thyroid extract in bringing about a complete vascular dilatation. Thus the full force of the circulation became again turned on to the glomeruli, and the secretion of urine recommenced. He entirely agreed with Dr. Herman that if renal activity could be established early enough, and if, coincidently, there was a rise in the excretion of urea, the prognosis was very favourable. He wished to congratulate Dr. Sturmer on the brilliant results obtained in his last series of cases, since he had added thyroid extract to the other means of treatment previously employed.

The PRESIDENT remarked that from the paper of Lieut.-Col. Sturmer it was difficult to come to an accurate conclusion as to the value of thyroid extract treatment in the cases mentioned; for they were associated with other remedies such as the hypodermic injections of morphia and saline infusions. The record was therefore the description of an empirical treatment which invalidated precise deductions as to the use of thyroid extract from a scientific point of view. Still, it was interesting from the observations so fully recorded from a clinical aspect, and from the success attained in so large a number of cases. With regard to predisposing influences in puerperal eclampsia some singular results have been noticed. Dr. Fordyce Barker mentions that in one day in a certain winter he saw three cases in consultation and two in the service of the hospital, while on another day of the same week three more cases in consultation. He was of opinion that atmospheric influences were largely concerned in the production of such an exceptional number. These facts accord with the experience of others in this country who may go for a lengthy interval and not see a single case, and then have several in succession. The question of malarial influence, as remarked by Lieut.-Col. Sturmer, had evidently some bearing of a similar kind in some of the cases he had narrated. While it is unusual in this country for so large a number of such cases to come within the scope of one practitioner the paper indicates the lines upon which the generally adopted treatment is based; it leaves at present much to be ascertained about many points in connection with the subject

TUBERCULOUS DISEASE OF CERVIX AND FALLOPIAN TUBES.

Shown by Dr. Walter Tate.

A. C—, aged 36, married, was admitted to St. Thomas's Hospital on November 28th, 1903. Catamenia began at age of 16, occurred every five weeks, and lasted seven to eight days. Patient has never been pregnant. Six years ago patient had two operations for removal of tuberculous glands in neck. Three years ago she was in bed for three weeks with an attack of pelvic peritonitis. For the last year she has suffered from dysmenorrhœa, and the periods occurred every three weeks. On examination the uterus was enlarged and retroverted; the cervix was greatly enlarged, and the canal was expanded into a large cavity, full of soft, friable growth. A portion of this growth was removed with the finger, and was found to be tuberculous on microscopic examination. On the right side of the uterus some thickening was felt in the situation of the appendages, and on the left side a soft swelling as large as a hen's egg, fixed to the pelvic wall. The uterus and uterine appendages were removed by a combined vaginal and abdominal operation, without any special difficulty. The abdominal wound was closed without drainage, and a gauze plug was placed in the vagina.

Parts removed.—On opening the uterus by longitudinal incision, the cervix is found to be considerably enlarged, the cervical canal excavated, and its walls lined by a soft, pulpy growth, hæmorrhagic on the surface. The growth is limited above by the internal os. The vaginal portion is healthy. The left tube and ovary form a swelling as large as a Tangerine orange. The tube is as thick as the little finger. The fimbriated end is closed, and on incising the walls, thick brown pus escaped; the mucous membrane of the tube is much thickened. The right tube is also slightly thickened. Portions of the tube and of the

cervix were examined by Mr. Shattock, who reported the disease to be tuberculous.

The patient ultimately made a good recovery, but convalescence was delayed owing to suppuration occurring in the wound.

FIBRO-MYOMA OF UTERUS WITH EXTENSIVE CARCINOMA OF BODY OF UTERUS, AND FIBROMA OF OVARY.

Shown by Dr. Walter Tate.

E. V—, single woman, aged 65, was admitted to St. Thomas's Hospital on March 10th, 1903. Catamenia began at 13, always regular; duration seven to eight days. Twenty-five years ago suffered from increased loss at the periods with metrorrhagia and a good deal of pain. She consulted a doctor, who is said to have told her she had a tumour, which would cause no further trouble after the menopause. The symptoms gradually improved, the pain was relieved, and the patient remained regular in her periods up to the age of 55. From that time up to the present the regular periods have ceased, but there has been almost continuous irregular hæmorrhage, with some pain of a shooting character in the hypogastric region. No increase in the size of the tumour has been noticed by the patient for many years past.

On examination a large irregular mass of fibroids is felt in the lower part of the abdomen reaching up to the level of the umbilicus. One well-marked freely mobile swelling is felt in the left iliac and lumbar region. *Per vaginam* the cervix is atrophic, and no part of the tumour is felt encroaching on the true pelvis.

The patient was rather a feeble subject and nearly blind, and as the symptoms were not very urgent, it was

not thought advisable to recommend abdominal hysterectomy. Moreover, it was not suspected that the disease was malignant owing to the long duration of the symptoms. She left the hospital on March 24th. After her return home the hæmorrhage continued and became much more profuse, causing great loss of strength. She was readmitted on November 23rd, and was anxious to have the tumour removed, even though the risk was very great.

On examining the patient again a hard tumour of the size of a large potato could be felt filling up the posterior part of the pelvis behind the cervix. This was not present at the first examination, and was probably the movable lump which had previously been felt in the left iliac region. Abdominal section was performed on November 20th. After drawing the uterine tumour out of the wound a second tumour was found occupying the pelvis, which proved to be a fibroid tumour of the left ovary. The uterus and its appendages were removed and the wound closed without drainage.

The uterine tumour removed weighed 5 lbs. 2 oz. It consists of a large mass of fibroids varying in size from a fœtal head down to a pea. Most of the fibroids are interstitial, but some are subperitoneal, and one is submucous. The largest fibroid on section is softened, and shows a large patch of necrotic tissue. The cavity of the uterus is much distended, and contains a large mass of new growth, which is sloughing. The malignant growth invades the muscular wall of the uterus, but does not involve the submucous fibroid. Microscopically the growth is a columnar-celled carcinoma. The fibroid tumour of the left ovary weighed 1 lb. 4 oz. It is very hard and white on section, and shows patches of calcareous degeneration. The right ovary removed was atrophic.

The case is of interest owing to the association of fibroid tumour of the uterus with fibroid tumour of ovary. It further illustrates the importance of exploring the uterus in cases of hæmorrhage persisting for years at about the time of the menopause and later, as in these cases malig-

nant disease of the body is a very probable cause of the symptoms.

Dr. Boxall had removed a myomatous uterus and its appendages for troubles due to the burrowing of the fibroids in the pelvis. On subsequent investigation he found a small carcinomatous mass not larger than a castor-oil bean at the fimbriated end of one tube, and on further investigation the ovary of the opposite side was found to be similarly affected. There was nothing in the clinical history of the case to suggest malignant growth. The specimen was shown before the Society two or three years ago.

Dr. Peter Horrocks called attention to the fact that bleeding from the uterus after the climacteric in a woman known to have a fibroid tumour did not necessarily indicate malignant disease of the uterus, as in this case, or malignant degeneration of the fibroid. Some authorities disputed the possibility of the latter, but Mr. Alban Doran and he himself had shown specimens illustrating sarcomatous changes in fibroid tumours.

TWO CASES OF DIFFUSE ADENO-MYOMA OF UTERUS.

Shown by Dr. Walter Tate.

Case 1.—Patient aged 46. She was married at the age of twenty-three, and had no children. She had been a widow for eleven years. Patient has always suffered severely from dysmenorrhœa; the periods only continue for three days or so, and are of the twenty-one day type. Since the death of her husband the dysmenorrhœa has been much more severe, and she often has to keep in bed for three days on account of pain and sickness. Two and a half years ago the patient consulted Dr. Cullingworth on account of the dysmenorrhœa, and was anxious to have something done. Nothing, however, was advised owing to the patient's age. The uterus at that time was bulky. The periods remained quite regular till October,

1902 ; she then saw nothing for seven weeks, after which she had continuous loss for four weeks.

In January, 1903, she saw a doctor in Rome on account of the hæmorrhage, but no special treatment was advised. After this the periods became regular, but were accompanied by very severe pain. In October, 1903, she again had continuous hæmorrhage for a fortnight ; then she saw nothing for seven weeks, after which she had continuous loss till January 16th, 1904. At this time she was examined by Dr. Cullingworth and Dr. Tate, and the uterus was found to form a tumour in the hypogastric region. *Per vaginam* the cervix was healthy, non-patulous, and the uterus was enlarged to the size of a three months' gestation. As it was thought possible that it might contain a fibroid polyp, and it was uncertain whether the enlargement of the uterus was due to a malignant growth, the interior of the uterus was explored under an anæsthetic. A good deal of soft, apparently adenomatous growth was removed with the curette, but as the interior of the uterus felt very irregular and the uterine wall felt greatly thickened and very hard, the patient was advised to have the uterus removed.

On January 19th, 1904, the uterus was removed by the combined vaginal and abdominal operation. The ovaries were left *in situ*. The patient made an excellent recovery.

Parts removed.—The uterus is found to be much enlarged owing to great increase in the thickness of the uterine wall. It is symmetrical in shape, and measures 5 inches from fundus to the external os. The broadest transverse measurement of the uterus is 3½ inches.

There is a diffuse fibro-myomatous growth in the posterior wall of the uterus extending from the mucous membrane outwards towards the peritoneal coat. There is no clearly defined edge to the tumour, but there is a thin layer of normal uterine muscle just below the peritoneum.

Pathological report by Dr. Dudgeon.—An examination of sections, including the entire thickness of the uterine

wall, shows the extension of glandular tissue from the mucous membranes to the peritoneum. In some places the glands are almost circular and quite small; in other places large and convoluted processes extend in all directions into the muscular tissue. The epithelium lining these glands is columnar and sometimes almost cubical. There is complete absence of ciliated epithelium throughout the various sections. The epithelium rests on a highly cellular (both round and spindle-shaped cells) submucosa, which gives quite a characteristic feature to this pathological condition.

The muscular coat, beyond the hypertrophy to which attention has been drawn, appears to be normal. There is no evidence of fibrosis.

Case 2.—Patient was a single woman aged 46. Catamenia began at 15, usually copious, lasting for seven days. During the last seven years menstruation has been excessive, and has been accompanied by a considerable amount of pain. There has been some leucorrhœal discharge for the past four years. Two years ago patient noticed a lump in the lower part of the abdomen. This has gradually increased in size, and during the last year the periods have been very excessive. She was admitted to St. Thomas's Hospital on December 9th, 1903. At this time she was remarkably anæmic. A tumour could be felt in the lower abdomen reaching up to within a handsbreadth of the umbilicus. The cervix was high up and far back. The anterior vaginal wall was depressed by a hard, round, solid tumour, which was continuous with the abdominal swelling. There is some mobility of the whole mass, which appears to be as large as a cricket ball.

On December 18th abdominal hysterectomy was performed. The right ovary was cystic and removed with the uterus. The left ovary was not interfered with.

Patient made fair progress during the first week after the operation, although there was some trouble with the

bowels. On the eighth day after operation she began to complain of pain in the left side, in the iliac region, and on the ninth day she began to be sick, and other signs of obstruction developed. The abdomen was re-opened on December 28th, and several coils of intestine were found adherent to the upper surface of the uterine stump. There was also a good deal of serous exudation and lymph in the pelvis and extending along intestines towards the left iliac region. The abdomen was thoroughly douched and drained, and the patient ultimately made an excellent recovery.

Parts removed.—The uterus is greatly enlarged. The anterior wall is $2\frac{1}{2}$ inches thick. The posterior wall is $1\frac{1}{4}$ inch thick. The length of the uterine cavity is $3\frac{1}{4}$ inches. The external surface of the uterus is quite smooth and very hard. On section the whole thickness of the cut surface presents a homogeneous appearance extending from the mucous membrane to the peritoneal coat, owing to the presence of a diffuse myomatous growth. There is no sign of any capsule separating the tumour from the rest of the uterine tissue. In the lower part of the uterus is a small encapsuled fibroid as large as a walnut.

Dr. Frank E. Taylor said his interest in this subject was aroused by two cases which had recently come under his observation, the specimens having been removed from patients in the Chelsea Hospital for Women by Mr. Bland-Sutton. The first case had already been recorded *in extenso* by Dr. Cameron and himself in the March number of the 'Journal of Obstetrics and Gynæcology of the British Empire,' and the second he hoped to lay before this Society at some no very distant meeting. The description, both macroscopic and microscopic, of the growths which he had examined and which was given in the paper already referred to, might be equally well applied to the specimens which Dr. Tate had shown us to-night. It was, he thought, somewhat unfortunate that the endometrium had been removed in Dr. Tate's case by a previous curettage, because the opportunity had been lost of ascertaining the exact relationship between the endometrium and the adeno-myomatous growths. In his own cases and many of the recorded ones, especially that of Cullen, there could not, he thought, be the slightest doubt that the endometrium stands in direct causative relationship to

neoplasms of this nature. Von Recklinghausen, however, although not denying this mode of origin, considers it to be an extremely rare one, and it is his opinion that they almost always take their origin in the Wolffian ducts or their remnants. He thought that adeno-myomata had probably often been overlooked hitherto, the growths having been considered to be malignant adenomata or adeno-carcinomata. They could probably, however, be readily distinguished by the fact that in the adeno-myomata the glandular elements were separated from the fibro-muscular by more or less highly cellular stroma, whereas in the case of malignant disease the epithelial and muscular elements were in direct contact with each other.

Dr. Blacker hoped that these two specimens would be referred to the Pathology Committee. They were the first examples of this kind of tumour to be shown before the Society, and appeared to resemble very closely the cases recorded by Cullen in his monograph on "Adeno-myome des Uterus," published in 1903. Further examination would no doubt show that the glandular downgrowths were in reality derived from the uterine mucous membrane, and an investigation of the cases by the Committee might help to solve the vexed question of the origin of these interesting tumours.

SOLID MESENTERIC TUMOUR (FIBRO-MYOMA) WEIGHING THIRTY POUNDS.

Shown by Mr. Alban Doran.

I exhibit this specimen to-night because it is too bulky for preservation. It was removed seven days ago, that is on March 31st, 1904, from a woman aged 34, married six years and never pregnant. For five months the abdomen had been swelling, and during the last six weeks with great rapidity. The girth at the umbilical level was $43\frac{1}{2}$ inches. There was very uniform distension and dulness on percussion; a distinct thrill could be obtained on percussing in any direction. The base of the tumour descended into the pelvic brim, the cervix uteri lay far back, and the sound passed four inches upwards and to the left behind the tumour, which appeared to be an enormous ovarian cyst.

At the operation I found that the tumour was entirely invested by the upper layer of the mesentery with the ascending colon on its right border, and the small intestines on its surface to the left. There was nothing in the contents sufficiently fluid to run through the trocar. I enucleated it and found that the right Fallopian tube and ovary were drawn up on the inner side of its capsule, quite unaltered, the mesosalpinx was intact, the uterus and left appendages healthy and not drawn up on the capsule. There was much trouble in checking hæmorrhage, and I plugged the great cavity whence the tumour had been enucleated with gauze, replaced by a rubber tube on the second day. The capsule, after careful trimming, was attached to the lower angle of the wound, the right appendages were amputated in order to secure by ligature the vessels which ran into the capsule from the pelvis. Large vessels from above had also to be carefully ligatured.

At 6 p.m. to-day, April 6th, the patient was in a very favourable condition. The bowels were opened freely without any trouble. (The patient recovered.)

A fuller account of the case will be published in due time. At present I only need dwell on the operative question about the surgical treatment of the capsule. In this instance my usual practice of packing it, when oozing is free, and fixing the cut edge to the lower angle of the wound, seemed to be the best way of concluding the operation. I have discussed the practice and the objections which have been raised against it at a meeting of this Society eight years ago.* As the capsule, though developed in peritoneum belonging to the upper layer of the mesentery, was very ample, there seemed little risk of causing obstruction, but great distension occurred by the end of the first day, completely relieved by removal of the gauze. Heidenhain† recently packed a mesenteric

* "On the Management of True and False Capsules in Ovariotomy," 'Trans. Obst. Soc.,' vol. xxxix, p. 265.

† "Enormgrosse Mesenterialbreicyste," 'Monatsschrift. für Geb. u. Gyn.,' March, 1904, p. 446.

cyst and did not remove the gauze for a week; twice during that week he had to puncture distended intestine to relieve acute distension, an eminent instance of abuse of packing. It was suggested that resection of a certain amount of gut is necessary in some cases where big retro-peritoneal tumours are enucleated.

AN OVARIAN DERMOID WITH A TWISTED PEDICLE SIX INCHES IN LENGTH.

By Mr. J. Bland-Sutton.

In January, 1904, Dr. R. Ironside asked me to see a middle-aged lady, mother of several children, on account of an excessively mobile tumour in the abdomen which had sometimes been regarded as a movable kidney when it occupied the lumbar region, and at others, when it fell into the pelvis, as an ovarian tumour. He examined the patient under ether, and came to the conclusion that it was an ovarian tumour, and recommended its removal. At the operation the tumour represented in the drawing was found, attached by a narrow twisted cord 15 cm. (6 inches) long to the rounded stump of the left Fallopian tube. The cyst-wall was extremely thin and free from adhesions.

The sac contains a mass of grease mixed with short light brown hairs.

It is needless to add that the operation was singularly easy and the convalescence free from anxiety.

It is well known that ovarian tumours, especially heavy dermoids, are occasionally furnished with unusually long pedicles, which allow them to float among the intestines and reach as high as the lumbar region. In this situation they are sometimes mistaken for a movable kidney, and even tumours of that organ. In one case Le Bec removed an ovarian tumour through an incision in the left loin under the impression that he was dealing with a renal

An ovarian dermoid containing light brown hair and grease; its twisted pedicle measured at the time of removal 15 cm. (6 inches).

tumour. In these cases the pedicle, though long, was not twisted.

In the specimen the subject of this paper, it is easy to see that a very little strain would have broken the slender stalk and left the dermoid free to tumble about the belly.

It is well to remember that Rokitansky, in his classical paper, pointed out that the lengthening of the pedicle and the spontaneous detachment of an abdominal tumour was in part due to the tension of the tumour on its pedicle, as well as to torsion. Probably both factors played a part in elongating the pedicle in my specimen.

ON A CASE OF ACUTE AXIAL ROTATION OF A CALCIFIED FIBROID OF THE UTERUS.

By Mr. J. Bland-Sutton.

Axial rotation of a pedunculated fibroid is a recognised accident; in the present case I am able to bring a specimen before the Society, in which the tumour is shown with its pedicle twisted and the deep plum colour, so characteristic of the engorgement of tumours in which acute axial rotation has happened, has been preserved.

The patient had reached her 53rd year, and had ceased to menstruate at fifty. For many years she had suffered from fibroids of the uterus, which had become so big that her belly was as protuberant as that of a pregnant woman at the eighth month. After the cessation of menstruation the tumour masses in the abdomen underwent a marked diminution, but coincident with this she began to suffer from frequent slight attacks of pyrexia, which were regarded as influenza.

In February, 1904, without any obvious reason, the patient was seized with violent pelvic pain, accompanied by

painful micturition and tenesmus ; the temperature rose to 102°, with a pulse-rate of 120 per minute.

On examination by the vagina a hard, rounded, tender mass, completely blocking the pelvis, could be felt behind the uterus.

These signs made it clear that some change had arisen in one of the fibroids, or that the pelvic mass was an inflamed ovarian cyst incarcerated by the weight of the fibroids in the abdomen.

The patient very readily assented to operation.

On opening the abdomen two large-stalked fibroids, each as big as a man's head, were exposed, reaching from the pelvis to the liver, and the surfaces, where they came into frictional contact with each other, were coated with a thick layer of white material resembling the cartilage-clad facets on the articular surface of a bone. The non-contact aspects of these tumours were everywhere adhered to omentum, the peritoneum on the posterior aspect of the belly, and especially to the sigmoid flexure of the colon. The vessels in these adhesions were very large, the arteries, veins, and lymphatics forming a rete mirabilis with vessels many of which exceeded in cross-section the radial artery. With patience these difficulties were overcome. The uterus was obscured by what may be termed a constellation of fibroids (about twenty) varying in size from a ripe cherry to a Tangerine orange. Standing out from these by a long stalk attached to the posterior wall of the uterus is a calcified fibroid as big as a fist. This has undergone one complete rotation and tightly twisted its stalk. The uterus was removed by the supra-vaginal method ; the broad ligaments had become converted by blood and lymph into thick succulent septa. The pelvic steps of the operation gave me no difficulty.

The operation was a tedious one on account of the great number of vessels and adhesions that required ligature, as well as the length of incision that required to be sutured in layers. It was the longest hysterectomy that I have performed, for the patient was under the anæs-

thetic one hour and ten minutes; but in spite of this she made a good recovery.

The operative aspect of the case is, of course, entirely secondary to the clinical, and I beg to offer the following opinion in regard to the rotation of the tumour:—

As long as the patient menstruated, and these large tumours were vigorously supplied with blood, they were in almost the same close contact as the bones of the carpus or the tarsus. On the cessation of menstruation the tumours began to shrink and their mobility markedly increased; as a result the calcified fibroid on the back of the uterus, which had been more or less incarcerated and rendered immovable in the pelvis by the close apposition of the two large abdominal tumours, had, in consequence of their shrinkage, more space, and became in itself movable in virtue of its pedicle. The exact cause of the rotation is pure conjecture, but I would submit that a rounded movable body with a definite pedicle, allowing of a fairly free excursion and lying beneath and in close juxtaposition to two masses ten times larger than itself, would, or rather could, be made to rotate on its own axis by the movements of the larger juxtaposed masses much in the manner of a cog-wheel. It is also conceivable that the tumour may have originally rested above the pelvic brim, and then as it shrunk, slipped, or was pushed into the pelvic cavity by the mere weight of the superimposed tumours; either of these movements could bring about axial rotation.

Whichever explanation may be advanced, it does not upset the fact that this tumour did rotate and twist its pedicle, causing the patient great pain and distress, as well as placing her life in great peril.

TORSION OF THE PEDICLE IN HYDROSALPINX, AND OTHER MORBID CONDITIONS OF THE FALLOPIAN TUBE.

By R. Hamilton Bell, M.A., M.B., B.C.(Cantab.).

(Received February 11th, 1904.)

(*Abstract.*)

Attention is first directed to the rarity of the accident, and particularly to the very few observations recorded in England. Various continental papers dealing with the subject are referred to, particularly one by Cathelin in the 'Revue de Chirurgie,' 1901, to which a table of forty-one observations is appended. The writer is able to add twelve further cases collected from the literature, which have been recorded since 1901, or had escaped Cathelin's notice.

A full account is then given of a case coming under the writer's own observation. The patient was under the care of Dr. Cullingworth in St. Thomas's Hospital, February, 1903. The symptoms and physical signs suggested the diagnosis of an ovarian cyst with torsion of the pedicle, rather of the chronic than of the acute variety. At the operation the condition found was that of bilateral disease of the tubes, a left hæmatosalpinx, converted into such from a previous hydrosalpinx by torsion of its pedicle, and a right hydrosalpinx. The twist consisted of one and three quarter turns in the inverse direction of the hands of a watch. The ovary was not involved. An account of the parts removed follows the clinical history of the case.

The author shortly discusses the general problem of torsion of the abdominal viscera, and points out the particular conditions

which must be satisfied before torsion can take place in hydrosalpinx and other morbid conditions of the Fallopian tube. A swelling situated in the ampulla, and not in the isthmus, sufficient growth of the tumour for it to obtain an abdominal rather than a pelvic situation, a long thin pedicle, and the absence of adhesions are the favouring conditions. These are satisfied much more frequently in cases of hydrosalpinx than in other forms of tubal disease.

Short notes follow on the two varieties of torsion, acute and chronic; the direction of rotation; and the results of the twist. The influence of age and pregnancy is also discussed.

The paper concludes with a consideration of the more clinical aspect of the cases. The close approximation of the symptoms to those of a twisted ovarian is recognised, and the fact is noted that a correct diagnosis previous to operation has never yet been made. But it should be at least suggested when the following conditions are present: a fluctuating abdominal tumour of irregular shape, not rising above the umbilicus, associated with paroxysmal attacks of pain, culminating in a very severe attack with vomiting and constipation, and if the tumour has been observed before, increase of size, tenderness, and some loss of mobility.

The treatment consists of removal of the twisted tube by abdominal section, and the writer thinks that the other tube should be dealt with conservately wherever possible.

Torsion of the pedicle in tumours of the Fallopian tube is a rare phenomenon. To Mr. Bland-Sutton we owe the first recorded observation. It was a hydrosalpinx with its pedicle twisted three and a half times, and was removed by Mr. Henry Morris, in 1891. The specimen is preserved in the Museum of the Royal College of Surgeons. Since that date very few cases have been observed in England, or at any rate published, and the subject has never aroused much interest or attention. The case is very different on the Continent. In France observations of the phenomenon are constantly being made, and at the Société d'Obstetrique de Paris are the subject of frequent discussion. In addition, Hartmann and Reymond,

Maillard, and Cathelin have written articles, with a record of all previously observed cases, and a full discussion of the clinical and pathological phenomena.

In Germany also numerous cases have been recorded, and Praeger, in the 'Archiv für Gynäkol.,' 1899, collected twenty cases from the literature, and added two of his own.

My attention was directed to the subject by the occurrence of a case under the care of Dr. Cullingworth in St. Thomas's Hospital. It was the first case of the kind which had come under his personal observation, and he suggested to me that it would be valuable to record it, and at the same time to look up the records of other published cases.

On searching the literature I soon found that the cases, though rare, were by no means so unique as was thought only a few years ago. Hartmann and Reymond, in 1898, collected eleven cases, Praeger in the following year reached twenty-two, and finally Cathelin, at the end of his article "La Torsion des Hydro-Salpinx," published in 1901, added a table of forty-one observations. A few of these might perhaps be disputed. He includes, for example, a specimen of axial rotation of a right-sided parovarial cyst with attached right ovary and Fallopian tube distended by hæmorrhage. This case was published by Napier in the 'Transactions of the Obstetrical Society,' 1892, vol. xxxiv. Clearly, though closely akin to the cases we are considering, it is only in a very loose classification included amongst them.

Hartmann and Reymond show the same laxity as Cathelin in this respect, and in their article headed "La Torsion des Salpingites" they include a case of twisting of a healthy tube, and another where the main cystic mass contained five hundred grammes of blood, and was very probably ovarian rather than tubal.

It has fallen to the lot of most men who have operated on a considerable number of ovarian tumours to come across an ovarian cyst with twisted pedicle associated with a hæmatosalpinx produced by the torsion of a hydrosalpinx

which was adherent to the ovarian cyst. One such case occurred in St. Thomas's Hospital in June, 1898. But here the main mass is ovarian, and the associated hæmatosalpinx is a mere accessory. Such cases should therefore not be classified with those we are considering here, in which the torsion occurs in connection with primary tumours of the Fallopian tube, and in which the ovary may, or may not, be involved in the twist. Praeger excludes all such cases from his list, and he also particularly excludes one published by Montgomery ('American Journal of Obstetrics and Gynæcology,' vol. ix) of a cyst in the broad ligament closely connected with the tube, a case similar to Napier's mentioned above, and included by Cathelin.

But even if we are careful to exclude these cases, the number of recorded observations has now reached fifty at the least. I had intended to draw up a table of all the cases, but abandoned this on discovering that it had already been done by Cathelin as recently as 1901. I will, however, before giving details of the case on which this paper is based, mention shortly those which I have discovered in the literature which have been recorded since 1901, or had escaped Cathelin's notice. These are twelve in number.

1. Praeger. 'Archiv. für Gynäkol.,' 1899, p. 583.

A married woman, aged 22, one child. Pelvic tumour, placed on the right side, and noticed nine months before operation. Severe abdominal pain, vomiting and constipation.

Diagnosis.—Tubal or ovarian tumour, either intra-ligamentary or adherent.

At operation tumour found arising not from *right* but left side. Tubal in origin, dark-red in colour, and adherent. Pedicle twisted twice in the direction of the hands of a watch. Pedicle 7½ cm. long; left ovary drawn into the twist. Below part of the tumour was a hæmatocele the size of a fist. Recovery.

2. Praeger. 'Archiv. für Gynäkol.,' 1899, p. 584.

A married woman, aged 35, one child. Tumour on left side of abdomen, first discovered one year before operation; later twelve weeks' amenorrhœa, with sickness, severe abdominal pains, retention of urine, constipation, etc. Tumour in left iliac fossa, tender, fluctuating. Below this four months' pregnant uterus.

Diagnosis.—Left-sided ovarian cyst with twisted pedicle, associated with four months' pregnancy. At operation, dark-red cystic swelling, which turned out to be a left-sided tubal swelling, with the pedicle twisted twice in the direction of the hands of a watch. Ovary not involved. Contents, fluid blood and detritus. Tube between twist and uterus very thin. Recovery. Pregnancy not interrupted.

3. Pozzi. 'Comptes Rendus de la Soc. d'Obstét. de Gynécol. et de Pædiat. de Paris,' April, 1900.

A right tubal pregnancy, three and a quarter months, with torsion of the pedicle; left hydrosalpinx. Married woman, aged 33, one previous pregnancy, seven years ago; last period January 4th, 1900. On January 19th, severe pains in lower abdomen, and slight hæmorrhage. This hæmorrhage continued daily till the operation, April 2nd. On February 23rd another severe attack of abdominal pain, with vomiting. Tenderness of the lower abdomen. *Per vaginam* a cystic tumour was felt on the left side, but at the operation this was found to be attached to the right cornu of the uterus by a pedicle which had one complete turn in the inverse direction of the hands of a watch. The twist was not very tight, so that the circulation had not been interrupted in the tube, and the ovum had continued to grow. Ovary not adherent to the tube, but involved in the torsion.

(This case is mentioned by Cathelin, but not included in his table, because it is a tubal pregnancy and not a hydrosalpinx. He however includes one clear case of

tubal pregnancy.—A. Martin, 'Centralbl. für Gynäkol,' 1893.)

4. Pinard and Paquy. 'Comptes Rendus de la Soc d'Obstét. de Gynécol. et de Pædiat. de Paris,' October, 1901.

Torsion of the pedicle of a right hydrosalpinx, coinciding with a four months' pregnancy. Married woman, aged 26, one previous pregnancy. Several severe attacks of abdominal pain in the course of the present gestation. Vomiting in the last attack. Tender cystic tumour to the right of the pregnant uterus.

Diagnosis.—Pregnancy, together with an ovarian cyst with twisted pedicle.

Operation, October 13th, 1900. Tumour greenish-brown in colour, tubal in origin, with pedicle twisted twice on itself, in the inverse direction of the hands of a watch. Some recent adhesions. Ovary enlarged, not participating in torsion. Recovery. Pregnancy not interrupted.

5. Pinard. 'Comptes Rendus de la Soc. d'Obstét. de Gynécol. et de Pædiat. de Paris,' 1902.

Torsion of a hydrosalpinx during pregnancy. Married woman, aged 36, one previous pregnancy. Patient came under Mons. Pinard's care June, 1902; last period September 5th to 13th, 1901. History of short attacks of pain in the right inguinal region for five years, worse since the pregnancy started. Admitted for severe pain, nausea, and frequent micturition; later vomiting, diarrhœa, and meteorism; slight icterus. It was decided to induce labour, and deliver as rapidly as possible. Delivery effected in 70 minutes. Temporary improvement, but abdominal section undertaken, as arranged before delivery. In the right iliac fossa tumour the size of an orange, a right hydrosalpinx, twisted twice on its pedicle in the inverse direction of the hands of a watch. Ovary normal. Removal of right appendages. Recovery.

6. Kleinhans. 'Veit's Handbuch,' p. 713. Illustrated.

No clinical details of case. Specially interesting from the presence of a hæmatocele due to a left tubal abortion, associated with an hæmatosalpinx on the right side, due to torsion and adhesions. Right tube shows a quite thin isthmic portion, and is then bent down and backwards, with one axial twist. Tube swollen beyond the twist. Contents, dark fluid blood. Wall infiltrated with blood.

7. Harpoth. 'Centralbl. für Gynäkol., 1900, p. 1399.

Left tube twisted two and a half times, "from left to right." Right tube untwisted. Sero-purulent contents of both, but contents sterile. Absence of adhesions, which rendered twist possible.

8. Waldo. 'American Journ. of Obstet.,' August, 1901.

Single woman, 17 years old. Abdominal pain, etc. No irregularity or change in menstruation.

Diagnosis.—? Appendicitis. At operation, right hæmatosalpinx, contents entirely fluid, dark in colour, no clots. Ovary drawn up by the tumour, but not involved in twist. Ligature on pedicle slipped, but there was no hæmorrhage; complete strangulation. Twist of pedicle described thus: "Several distinct and complete twists on its long axis." Direction not stated. Left tube and ovary normal. Recovery.

9. Waldo. 'American Journ. of Obstet.,' August, 1901.

Married woman, aged 26, no pregnancies. Abdominal pain and tenderness. Menstruation regular.

Diagnosis.—Inflamed and adherent ovarian cyst. At operation proved to be a left hæmatosalpinx with "several complete twists" of pedicle. Direction not stated. Ovary not involved and left *in situ*. Also right tube and ovary. Recovery.

10. Baldwin. 'American Journ. of Surg. and Gynæcol.,' 1900. St. Louis, 1900.

I obtained this reference, but have not been able to see the paper.

11. McCann. 'Lancet,' May 9th, 1903. Illustrated.

Married woman, aged 37, sterile, menstruation regular. Four attacks of acute abdominal pain, culminating in very severe attack a fortnight before operation. A swelling on the right side of the uterus, bluish-black in colour. Intestines adherent to it. When pedicle exposed three complete turns observed. Ovary not involved and left *in situ*. Appendages on opposite side normal. Dilated tube contained blood-clot and dark fluid blood. Tubal wall infiltrated with blood. Sections made from the wall showed chorionic villi, also infiltrated with blood. Recovery.

12. Lewers. 'Trans. Obstet. Soc. of London,' vol. xliv, p. 362.

A single woman, aged 37. First attack of abdominal pain and vomiting December, 1901. A similar attack May, 1902, then continuous pain till September, 1902, when she had a third acute attack. Menstruation normal. Physical signs suggesting the presence of two ovarian tumours. This consequently the diagnosis, "and that probably, judging from the history, one had a twisted pedicle." Operation October 9th, 1902. Condition found to be that of double pyosalpinx. The right pyosalpinx was firmly adherent to small intestine and omentum, and slightly adherent to the bladder. When freed from adhesions the dilated part of the tube was found to be attached to the broad ligament by a pedicle twisted several times, which consisted of the undilated inner part of the Fallopian tube. Direction of the twist not stated. The right ovary was not involved, and was not removed. The pedicle of the left pyosalpinx was not twisted. Bacteriological examination failed to demonstrate the tubercle bacillus, but Dr. Lewers states that "though no positive evidence of tubercle was found, he thought that most probably the salpingitis was tubercular." Sepsis and gonorrhœa were fairly excluded by the fact that the patient was a virgin. Uninterrupted recovery.

To proceed to the details of the case under my own observation :

P. A. C—, aged 45, was admitted to St. Thomas's Hospital, February 9th, 1903, under the care of Dr. Cullingworth. She had been a fairly healthy woman, but subject to severe and recurring attacks of bronchitis. There was a family history of tuberculosis, her father, sister, and two brothers having died of consumption. Catamenia began at thirteen, and till two years ago the periods had always been regular, of the twenty-eight day type, and lasting for three or four days. The patient was married at nineteen, and eighteen months later bore a healthy child, the labour and puerperium being normal. Since then she had never been pregnant.

In 1899 she was seized one evening with severe pain in the lower part of the abdomen. The pain was such as to cause faintness and vomiting, but it lasted only a few hours, and she did not see a doctor. So far as the patient can remember no headache or fever, diarrhœa, or constipation accompanied the attack of pain. For two years she was free, and then, in 1901, the attacks returned, but though sharp while they lasted they were of short duration and never led to her seeking advice until a very severe attack in February, 1903, which immediately preceded her entrance to the hospital. All through there had been no trouble with the bowels, nor with micturition. For the last two years the periods had lost their regularity, recurring at intervals varying from one to three months, but there was absolutely no evidence of any relation between the attacks of pain and uterine hæmorrhage. She had herself noticed no increase in the size of the abdomen, and was quite unconscious of any lump or swelling.

During the last six months the abdominal crises had recurred with increasing frequency, at intervals of one month to six weeks, and greater severity. The last attack was the severest of all.

On examination of the abdomen, which was full and

rather tense, a swelling could be felt extending from the pubes upwards to a point one inch below the umbilicus. The fingers could be inserted over the borders of the swelling, between it and the anterior superior spines on both sides. There was marked tenderness on the left side. Fluctuation could be obtained.

Per vaginam the uterus was lying behind the swelling, no part of which projected into the pelvic cavity. It could be felt lying in front and above the anterior vaginal wall, but it caused no bulging. Bimanually the swelling gave the impression of being a not very tense cyst about the size of an ostrich's egg. It lay with its largest diameter across the abdominal cavity, reaching to within one inch of the anterior superior spine on the right, and almost as far on the left. High up behind the cervix could be felt a hard, fixed nodular swelling, which, however, did not depress the vaginal vault.

Per rectum the mass could be distinctly felt projecting into the bowel from the right side, the projection being itself of the size of a hen's egg, but forming part of a larger mass. An impulse was conveyed directly to the mass projecting into the rectum from the abdominal swelling.

The measurement from the pubes to the upper limit of the tumour was 4½ inches.

Examination of the chest showed that the heart was healthy, but there was impairment of resonance over the base of the right lung, and a pleuritic friction sound in the same area. Rhonchi were heard over both lungs. The temperature was normal, and the pulse of fair strength and normal rate. The urine was acid, sp. gr. 1030, with a heavy deposit of urates, but no albumen, sugar, or blood.

A week later (February 16th), a further pelvic examination was made by Dr. Cullingworth. The portion of the tumour extending into Douglas's pouch, and into the vagina above the right fornix, was still almost completely fixed. It was partly cystic, but in part consisted of a harder and more irregular mass, with cords on its surface

suggestive (to the touch) of the inflamed veins of a varicocele. *Per rectum* the swelling could now be felt distinctly in front of the canal, between it and the upper part of the vagina.

The most probable explanation of the existing condition in the light of the patient's history was that the attacks described represented a series of twists of the pedicle of a *right-sided* ovarian cyst, the harder and more fixed portions in the pelvis representing the parts more immediately affected, and therefore altered by œdema and adhesions, probably also by extravasations of blood.

Three days later the abdomen was opened. The omentum was found adherent to the subjacent viscera. It was carefully separated from its adhesions and pushed upwards. The abdominal mass could now be explored. A large cystic swelling was identified, and its pedicle made out, apparently rising from the *left* side of the uterus. Some adhesions to bowel and anterior surface of the uterus were broken down and the tumour brought out through the incision. It was dark, almost black, in colour, and obviously connected with the left appendages. To it was attached an apparently normal ovary. The pedicle was twisted, and the next step in the operation was the unwinding of the twist. To do this the cyst was taken in both hands and turned in the direction of the hands of a watch. The turns were carefully counted, and it was found that there had been one and three-quarter complete twists of the pedicle. A blunt pedicle needle, double threaded, was pushed through the mid-line of the pedicle close to the uterine end, and the ligatures interlocked and tied. The pedicle was then cut through and the cyst removed. For greater security the stump of the pedicle, which had been secured by forceps, was encircled by a silk ligature and tied.

The right side of the abdominal cavity was now explored, and deep down in the pelvis another tumour was found. It was brought to the surface, and proved to be an hydrosalpinx of the right tube, with the right ovary

flattened against its pedicle and adherent to it. The pedicle was tied and the tumour removed, together with a portion of the ovary. On examining the pelvis the uterus was found to be freely movable and to have returned from its retroflexion to a normal position. The abdomen was closed without drainage.

Convalescence was uninterrupted, the temperature never being above 100°. The patient got up on the eighteenth day, and left the hospital just four weeks after the operation. The last note is dated March 16th: "Progress unimpeded. Uterus in good position and mobile."

Examination of parts removed.—The cyst removed from the left side could be seen now to be a hæmatosalpinx, converted into such from a previous hydrosalpinx by the twisting of its pedicle. It formed a large tumour, measuring 5 inches by 4 inches in its longest diameters. It was impervious both at the uterine and fimbriated ends. The tube as it left the uterus was much thickened, the wall measuring a quarter of an inch. Gradually the lumen dilated, until it reached a point about 2 inches from the uterine end; then suddenly it enlarged into a bladder-like cyst, the fimbriæ of the tube forming a ribbed network of raised tissue on the internal wall of the cyst. For the greater part of its area the cyst wall was thick and hæmorrhagic, but at the distal end there was an area about the size of a crown, which was thin and free from hæmorrhage. On section the wall of the cyst was found to consist of a thin outer colourless fibrous layer, a broader middle layer of dark hæmorrhagic material, and an inner thin layer of mucous membrane, which was continuous over the narrow part of the tube, and over the ribs which represent the fimbriæ. This inner layer, with the hæmorrhagic layer, disappeared, to the naked eye at least, on reaching the thin portion of the wall already referred to. The contents of the cyst measured about 14 oz. The fluid was dark and grumous in character, about the colour of chocolate. It was strongly alkaline, and became solid on boiling. Under the microscope were seen the remains

of many red blood-cells and a good deal of amorphous *débris* resembling broken-down epithelium. No pus-cells were seen.

Attached to the external surface of the cyst was the left ovary, slightly hypertrophied and œdematous, but otherwise normal. Near the ovary was a second small cyst the size of a walnut, filled with dark altered blood. The right Fallopian tube was dilated into a typical hydrosalpinx, measuring in its greatest diameters 3 and 4 inches. The walls of the cyst were thin and transparent. There was evidence of pelvic inflammation in the strong adhesions, which divided the whole cyst into a series of rounded swellings, and matted the fimbriated end to the ovary and to the mesosalpinx.

No microscopical examination of the wall of the hæmatosalpinx was made, nor of the pedicle.

The whole problem of torsion in relation to the abdominal viscera is, of course, raised by such a case as this. As is well known, nearly every organ in the abdomen is affected in varying proportions, the liver perhaps being a single exception. Torsions of the bowel, kidney, and testicle are common, and of the spleen not infrequent. Of the female pelvic viscera the ovary is very frequently affected, the tube much more rarely, and the uterus least of all. What is the exciting cause? To this, I think, the answer must be that there is no single exciting cause, but a variety, some intrinsic to the organ affected, and some extrinsic. As regards the first point, the relative frequency of torsion in cases of dermoid and solid tumours of the ovary is very suggestive. Storer states that in 248 cases of ovarian torsion collected from various sources there were 43 dermoids and 23 solid tumours. Irregular shape and varying weight and consistency must tend to produce disturbance of equilibrium. Freund insists that this is the chief factor in torsions even of high degree. But most observers have regarded the extrinsic causes as of more account. Certain conditions must, of course, be present to give freedom of

movement, of which the most obvious are a certain length of pedicle, and a smooth peritoneum without adhesions. We shall see a little later how these conditions apply specially to tumours of the Fallopian tubes, but given their presence the actual exciting cause of torsion is still to seek, and the suggestions that have been made are very numerous. In Thornton's cases of torsion of ovarian cysts pregnancy and labour played a prominent part. Others have suggested the alternate filling and emptying of the bladder and rectum. This last, one would think, might produce a slow progressive twisting (a condition which is by no means rare, and judging from the history was probably present in the case here recorded), but not an acute strangulation. The latter must be produced by some more violent agent, such as the sudden descent of the diaphragm or quick movement of the body as a whole. Quick alterations of abdominal pressure, such as are produced by labour or tapping, might also be effectual. I think myself that sufficient stress has not been laid on the movements of the diaphragm in producing both kinds of torsion, the acute and the chronic. In the latter case suppose the peritoneum to have lost a little of its lustre. There would then be a certain amount of friction, easily overcome by the active contraction of the diaphragm, but sufficient to resist the much weaker force of its passive relaxation. It is easy thus to imagine a tumour driven slowly onwards, and the twist of its pedicle gradually increased.

It was mentioned above that the presence of a sufficiently long pedicle and the absence of adhesions are the two primary conditions which must be satisfied if torsion is to take place. The fact that these conditions can only occasionally be satisfied in tumours of the Fallopian tube explains the rarity of the phenomenon in these cases.

In most cases of salpingitis or pyosalpinx the adhesions are numerous, and torsion consequently impossible. In Cathelin's list of forty-one observations there are six of pyosalpinx, but he gives reasons for thinking that these

are not primary cases of purulent salpingitis, but rather primary hydrosalpinx, with subsequent hæmato- and pyosalpinx. He points out that in one of the observations of Pozzi the contents are described as a mixture of pus and blood. Of course a pyosalpinx is seen occasionally floating free in the pelvis, and in this case torsion would be as easy as in a hydrosalpinx, but the condition is rare. Probably if examined it would prove to be tubercular in origin. Nearly all the cases of tubal torsion recorded are torsions of a hydrosalpinx, converted into a hæmatosalpinx by the torsion, just as hæmorrhage occurs in an ovarian cyst when its pedicle is twisted. The case recorded here is a good example of this bilateral hydrosalpinx with conversion of the left hydro- into a hæmatosalpinx by twisting of the pedicle. Besides hydrosalpinx several cases of torsion of tubal gestations have now been recorded—*e. g.* by A. Martin, Pozzi, and McCann; one or two also of malignant disease (Stroganoff and Warnek); and Hartmann and Reymond published a curious case of twisting of a tube apparently quite healthy save for the hæmorrhagic infiltration produced by the twist itself.

Besides the absence of adhesions, it is necessary for the tumour to have a distinct pedicle, and much more easy for it to rotate when the pedicle is long and thin and the mobility free. These conditions are satisfied when the swelling is situated in the ampulla of the tube and not in the isthmus, and when sufficient growth of the tumour has taken place for it to have obtained an abdominal rather than a pelvic situation. The former condition is almost a *sine quâ non*, the latter not absolutely necessary, but certainly favourable. Where the exact localisation of the tumour in relation to the parts of the Fallopian tube is mentioned in the recorded cases it is almost without exception a dilatation of the ampulla connected with the cornu of the uterus by a long and usually thin pedicle.

Two varieties of torsion.—Leguen particularly has insisted on the slow or chronic variety of torsion. It is by no means so common as the acute form. It cannot

truly be said that there is any hard and fast line between the two forms, but clinically the cases are very different, urgent symptoms in the one leading to immediate operation, and in the other a succession of twists, with only short, if sharp, attacks of pain occurring at intervals perhaps for years. In my own case the first attack of abdominal pain occurred four years before her admission to hospital, and during the last two years the attacks had gradually increased in frequency and severity. It seems probable that these attacks were produced by successive twists, leading ultimately, but very slowly, to complete strangulation of the pedicle and acute symptoms.

Direction of rotation.—The methods of recording this are so various and confusing that it is difficult to arrive at any exact conclusion as to the usual direction of the twist. "From left to right" or "from behind forwards" are phrases loosely employed. I think undoubtedly the best method of describing the direction of torsion is that usually employed by the French writers, namely, "in the direction, or in the inverse direction of the hands of a watch." It must be understood that the face of the watch is towards the tumour, the back towards the uterus, but no other conditions need be observed. In my case the twist was unravelled by turning the tumour in the direction of the hands of a watch. The original twist was therefore in the inverse direction. As it was a left hydrosalpinx, this follows Kustner's "law of torsion." But there are so many exceptions to this law that it can hardly be considered to have much validity, as regards torsions of hydrosalpinx at any rate. Cathelin gives the following table in this connection:

R. side—		
In the direction of the hands of a watch...	2	cases.
In the inverse direction	5	„
L. side—		
In the direction of the hands of a watch...	2	„
In the inverse direction	3	„

These figures afford no support whatever to Kustner's

so-called law. They point, on the contrary, to there being no definite rule as regards the direction of the twist.

Results of torsion.—The number of turns varies greatly in the recorded cases from a half twist (*i.e.*, through 180°) up to four and a half twists. The actual number of twists is really of little importance. What is important is the tightness of the twist and consequent strangulation. It is possible to have a complete twist without any interference with the blood supply, but the usual thing is for the veins to be compressed; and as a natural result of the impeded venous return there is a rapid increase in the size of the tumour, with hæmorrhage both into the cyst and between the layers of its wall. Occasionally the strangulation is so complete that necrosis or gangrene occurs. In one or two recorded cases the twist has resulted in the complete, or nearly complete, separation of the pedicle. Occasionally bleeding takes place into the peritoneal cavity, and a hæmatocele is formed, as in Praeger's first case.

The usual tumour of the tube to undergo torsion is a hydrosalpinx, and it is transformed by the hæmorrhage induced by the torsion into a hæmatosalpinx. The contents are usually fluid, clots being only rarely found. The colour is variously described as dark red, blackish, resembling chocolate, or like the contents of a hæmatocele. Pus is occasionally found, but we have mentioned already that it may be doubted if these are primary torsions of a pyosalpinx. It seems more reasonable to suppose that suppuration has occurred after the twist, as often happens in the case of ovarian cysts.

The ovary is involved in the twist in roughly one third of the cases. I have found it in eleven out of thirty in which the point is specifically mentioned. Rarely other organs are affected. In one case of Hartmann the uterus was twisted a half-turn on itself. In another observation the bladder was nipped between a fibroid uterus and the twisted hydrosalpinx. Adhesions are, of course, common to the broad ligament, to the pelvic peritoneum, to bowel,

and to omentum. Hartmann and Reymond in France, and Praeger in Germany have made careful microscopical examinations of the wall of the cyst and of the pedicle at the seat of torsion. As might be expected, the sections show little more than hæmorrhages in all directions. The arteries in the pedicle remain permeable, at least many of them, though the walls are dissociated by interstitial hæmorrhages, and the vasa vasorum very dilated. The veins, on the other hand, are dilated and thrombosed. The microscopical appearances vary, of course, with the degree of torsion. As Cathelin puts it, there are four stages—congestion, hæmorrhage, mortification, and separation.

Influence of age and pregnancy.—As might perhaps be expected, the age at which this form of torsion occurs is that of full genital activity. Out of 42 cases in which the age is noted 34 were between 20 and 40 (13 of these between 20 and 30, and 21 between 30 and 40). There were 7 cases between 40 and 50, and 1 case under 20—an unmarried girl of 17. No case over 50 has yet been recorded. Pregnancy does not seem to play a very important part as a predisposing agent. Out of 38 cases 10 were nulliparous, and 15 had had only one confinement. At the same time several cases are directly associated either with pregnancy or the puerperium. In Cathelin's list of 41 cases there is only one operated on actually during pregnancy, but in the few cases that I have added two coincided with a four months' gestation, and were operated upon without any interruption of the pregnancy, and one was dealt with immediately after artificial delivery at practically full term. Multiple pregnancies weaken the abdominal wall, and would naturally favour torsion if a tumour of the tube were present; but there is the other side to the picture, namely, that diseases of the tubes are commonly associated with sterility, absolute or relative. The figures given above afford another illustration of this fact.

I propose now to consider shortly the more clinical

aspect of these cases, under the headings of Symptoms, Diagnosis, and Treatment.

Symptoms.—The most prominent symptom, common to all the cases, is abdominal pain of a severe type, situated in the lower part of the abdomen, and in nearly all cases referred to the side on which the twist has occurred. The pain is sudden in onset and very sharp, often leading to faintness and even syncope. In many cases, of which the one recorded here is a good example, there is a history of many previous attacks of pain, usually of short duration, and not so severe as the final attack which leads to operation. These previous attacks may be associated with slight twists of the pedicle, not leading to complete strangulation, or on the other hand they may be, when not severe, due to slight attacks of salpingitis and pelvic peritonitis, and so connected rather with the primary disease which leads to the formation of the salpingitic tumour than with the torsion of the pedicle. In certain cases the tumour itself has been recognised for months before the severe and final attack of pain. This occurred in Praeger's two cases, for example. In my own observation, though the woman had not herself noticed any enlargement of the abdomen, nor was she conscious of any lump, it is certain that the double hydrosalpinx must have been present for some time, forming a distinct tumour had she submitted herself to examination. In those cases where a tumour has been noted previously there are distinct changes observed in it occurring with the acute attack of pain, changes exactly similar to those occurring in an ovarian cyst when its pedicle becomes twisted, *i. e.*, enlargement, tenderness, and loss of mobility.

The pain, though usually situated in the lower abdomen, radiates sometimes to the inguinal region and legs, to the hypochondrium, or to the loins. This has led to wrong diagnoses, such as appendicitis.

There is usually little or no interference with menstruation. In Cathelin's series, out of seventeen cases where the point is mentioned in only forty-eight was there any

irregularity. Occasionally, however, there are irregular hæmorrhages between the periods. It is doubtful whether these are due to the original disease of the tube or to the torsion. Certainly in the analogous cases of torsion of the ovary some irregular bleeding is a fairly frequent symptom.

In my own case the periods had lost their regularity for two years, recurring at intervals varying from one to three months, but there was no evidence of any relation between the attacks of pain and uterine hæmorrhage. It must, too, be noted that the patient was 45 years of age.

Peritonitic symptoms are well marked. Vomiting is commonly noted, of varying severity, but never fæcal. The belly is usually distended, and constipation is the rule, sometimes absolute even to the absence of flatus, leading in two cases to the diagnosis of intestinal obstruction. On the other hand diarrhœa is noted in a few cases. The bladder is occasionally interfered with, leading to frequency of micturition. Retention of urine occurred in one case.

Slight fever is sometimes present, but it is not the rule. The pulse rate is generally quickened, and the face has a somewhat anxious look.

As regards the physical signs, the abdomen is usually distended, and tender to the touch. On gentle palpation a tumour can often be made out, fluctuating and more or less fixed, according to the amount of local peritonitis excited by the torsion. In the cases where a tumour has been observed beforehand augmentation of volume occurs.

The presence of a tumour in the abdomen is very characteristic of this lesion, in contrast to the usual pelvic situation of disease of the Fallopian tubes. This is doubtless due to the fact that torsion is much more likely to occur when the hydrosalpinx has reached such a size as to become an abdominal tumour than when it is confined within the narrow limits of the pelvis.

Vaginal examination does not commonly afford much information, save in the few cases where the tumour is

situated in the pouch of Douglas. In my own observation the tumour did not enter the pelvis, but could be felt lying in front of and above the anterior vaginal wall. This situation has been noted in three other cases.

Bimanually it is possible, if the patient is not too tender, to separate the tumour from the uterus in the great majority of cases, and localise it to the appendages. A careful examination should always be made to determine if possible the condition of the opposite appendages, as disease in that region might suggest the tubal rather than ovarian origin. In one case, published by Warnek, he was able to feel the twisted pedicle both by the abdomen and *per vaginam*, but this must be very rarely possible. The tumour was on the right side. He noted disease of the left appendages also, but still did not come to a correct diagnosis, regarding it as a case of right ovarian cyst with twisted pedicle and left salpingitis.

Diagnosis.—So far as I have been able to discover an absolutely correct diagnosis has never yet been made. The symptoms and signs detailed above show an almost exact correspondence with the symptoms and signs of a twisted ovarian, and this is the most common diagnosis. Sometimes the characteristic signs are not present, and examination is very difficult from the tenderness of the patient, or the presence of another abdominal tumour, such as pregnancy or a fibroid uterus. In these cases the operation is of an exploratory nature, and there is a provisional diagnosis only, usually of salpingitis or appendicitis.

I think the fact that a diagnosis has never been made or even suggested is due to the possibility of the condition not being present to the mind of the examiner. The cases are no doubt rare. Pozzi, in reporting his four cases in 1900, stated that he had never met with the occurrence before 1899, and the case reported here is the first to come under Dr. Cullingworth's observation. Still the number of recorded cases has now reached above fifty, and all since Bland-Sutton's premier observation in 1891. Given the following conditions and signs I think the

diagnosis should be at least suggested: a fluctuating abdominal tumour, not rising above the umbilicus, associated with paroxysmal attacks of pain, culminating in a very severe attack, with vomiting and constipation, and if the tumour has been observed before, increase of size, tenderness, and some loss of mobility.

The great difficulty is to distinguish this from torsion of an ovarian cyst. It cannot be done with certainty. But the shape of the tumour may be suggestive. An ovarian cyst is usually rounded, the twisted hydrosalpinx much more irregular. (In my own observation the tumour only reached to one inch below the umbilicus, and lay with its largest diameter across the pelvis.) If the abdomen were too tender for palpation percussion might be of aid. Instead of the definite upper convex limit of dulness there might be an irregular curve, corresponding rather to the retort-shaped hydrosalpinx than to the circular or oval ovarian cyst. Of course it is only in the case of small ovarian cysts that the question of differential diagnosis could arise. In tumours above the umbilicus no one would suggest disease of the tubes. Bimanual examination might lead to the discovery of bilateral disease, with acute symptoms on one side. This would be a further point in favour of tubal rather than ovarian torsion.

If the case is seen for the first time during the acute attack the severe abdominal pain, collapse, vomiting, etc., suggest either colic (hepatic, renal, or intestinal) or appendicitis. If a tumour is present a mistake is not likely to be made, but where this is absent, or small and not discovered from the extreme abdominal tenderness, the difficulty is great. Localisation of the seat of pain is sometimes of value, and the absence of particular symptoms such as tenderness at McBurney's point or jaundice would help in the differential diagnosis. Ruptured extra-uterine gestation might be suggested, but if watched for a little it is seen that there are not the symptoms of great internal hæmorrhage, nor on the other

hand the physical signs of the formation of a hæmatocele. As we have said before it is only rarely that a twisted hydrosalpinx forms a tumour situated in the pelvis.

From one point of view perhaps a correct diagnosis is a matter of no very great importance. The surgeon may be satisfied that operative interference is called for, and is ready to open the abdomen and prepared to deal with any condition he may find present. But the value of a careful attempt to make a diagnosis beforehand is I think undoubted, and I trust that before long a case may be recorded in which not only will the patient's life have been saved by a timely operation, but also that the condition will have been diagnosed correctly before the abdomen was opened.

Treatment.—This requires little discussion. It is necessarily surgical, and I think no one would dispute that the abdominal is the correct route. The incision should be made in the mid-line, or a little to one side, preferably the side of torsion. After removing the twisted tube the appendages of the other side should be carefully examined. Where the tube is obviously diseased it will of course be removed. One ovary should if possible be left *in situ*. It is a more difficult matter to decide what to do when the other tube is not obviously diseased. Cathelin in his discussion of treatment decides in favour of "une castration bilatérale," leaving only a fragment of ovary, with a secondary hysteropexy, but he allows that if the other appendages are absolutely healthy it may be better to leave them so as to give the patient a chance of a subsequent pregnancy. I think this should certainly be the rule, and that after removal of the twisted tube the other should be dealt with conservatively, by separation of adhesions for example, wherever possible.

With regard to "washing out" and drainage, each case must be considered separately. Though the practice of surgeons differs, I think it may be said that nowadays drainage should be avoided, unless there is some very positive indication for its use.

The prognosis after operation is favourable. So far only three deaths have occurred in just over fifty cases.

Bibliography.

Articles.

Hartmann and Reymond.—Annales de Gynécol., 1894 and 1898.

Maillard.—"De la torsion des Salpingites," Th. de Paris, 1897–98.

Praeger.—Archiv für Gynäkol., 1899. Bd. lviii.

Legueu.—Presse Médicale, Paris, January 20, 1900.

Storer.—Boston Medical and Surgical Journal, 1896, vol. ii, p. 461.

Cathelin.—"De la torsion des Hydrosalpinx," Rev. de Chirur., 1901, pp. 253 and 406. At the end of this article is a table of 41 observations with bibliography.

Cases recorded in paper.

(1) Praeger.—Archiv für Gynäkol., 1899, Bd. lviii.

(2) Ibid.

(3) Pozzi.—Comptes Rendus de la Soc. de Obstét. de Gynécol. et de Pædiat. de Paris, April, 1900.

(4) Pinard and Paquy.—Comptes Rendus de la Soc. d'Obstét. de Gynécol. et de Pædiat. de Paris, October, 1901.

(5) Pinard.—Comptes Rendus de la Soc d'Obstét. de Gynécol. et de Pædiat. de Paris, December, 1902.

(6) Kleinhans.—Veit's Handbuch, p. 713.

(7) Harpoth.—Centrabl. für Gynäkol., 1900, p. 1399.

(8) Waldo.—American Journ. of Obstet., August, 1901.

(9) Ibid.

(10) Baldwin.—American Journ. of Surg. and Gynæcol., 1900. St. Louis.

(11) McCann.—Lancet, May 9th, 1903.

(12) Lewers.—Trans. Obstet. Soc. of London, vol. xliv, p. 362.

Mr. Bland-Sutton expressed satisfaction that Dr. Hamilton Bell had interested himself in the question of torsion of distended Fallopian tubes, and had so carefully collected the recorded cases for publication in the 'Transactions' where they would be accessible for reference. He thought it very stimulating that one of the youngest Fellows of the Society should set forth such a high standard of clinical excellence as to expect the diagnosis of a hydro- or pyosalpinx with a twisted pedicle, especially in view of the fact that almost every acute lesion of the abdominal viscera had, at one time or another, been simulated by axial rotation of ovarian or similar cysts and tumours of the pelvic organs. It is a fact that Fallopian tubes when distended with simple fluid, pus, blood, or even when gravid did twist their pedicles, but it is very difficult to even attempt to frame a plausible theory to explain it; this could be attributed in a great measure to our profound ignorance of the statics and dynamics of the peritoneal cavity.

Dr. McCann said he had been fortunate in having met with an example of tubal pregnancy complicated by torsion of the pedicle. The patient had had two attacks characterised by elevation of temperature, increased pulse rate, sudden severe pain in the right side of the lower abdomen, vomiting and abdominal distension. As the history of tubal pregnancy was indefinite the case was considered to be either an inflamed cyst or a cyst complicated by torsion of its pedicle. When the tumour was removed it was found to be a hæmatosalpinx, the tubal cavity containing blood-clot. Chorionic villi were detected on microscopic examination of the tube wall. The case is described in the 'Lancet' of May, 1903, and appears to be the only example of this unusual complication published in the English language. Martin, of Berlin, in his book on "Eileiterkrankheiten," describes and figures a hæmatosalpinx due to tubal pregnancy complicated by pedicle torsion. The description closely resembles the condition of the tube and its contents which was found in Dr. McCann's case.

Mr. Alban Doran considered that diagnosis of the twisting of a tubal pedicle must be impossible in many cases and that therefore this condition was often overlooked, so that it was commoner than clinical records would lead us to believe. Again it seemed probable, for mechanical reasons, that it was easier for a tube than for an ovarian tumour to untwist itself after axial rotation. Tubal torsion to any appreciable degree was rarer than torsion of the ovarian pedicle because the dilated tube soon became fixed by adhesions, whilst many ovarian cysts did not become adherent to neighbouring structures until after torsion.

Dr. Lewers said that a remarkable feature in his case of pyosalpinx with twisted pedicle (to which reference had been made in Dr. Bell's paper) was the absolutely normal condition

of the ovaries on both sides. In the large majority of cases of pyosalpinx the ovaries were matted to the tubes, and the lump so formed was generally firmly adherent everywhere. At all events in such cases it was impossible to leave the ovaries. In his case of pyosalpinx with twisted pedicle he was easily able to remove the pyosalpinx without removing the ovary. He thought that the freedom of the ovaries in this and similar cases tended to show that the cause of the pyosalpinx was one different from the usual causes of pyosalpinx, viz., gonorrhœa and sepsis. Possibly the cause might be tubercle, but no evidence of it could be found in his case though a careful examination of the pus and tube-wall was made.

Dr. Bell thanked the Fellows for the kind reception they had given to his paper. He recognised fully the great difficulty in the diagnosis of the condition, but he still clung to the belief that, given an irregular swelling situated below the umbilicus, associated with the symptoms of torsion, and associated also with disease on the other side of the pelvis, the possibility of this accident should be present to the mind of the observer. Of course, where the swelling was of the size mentioned by Mr. Targett it would never suggest tubal disease. He was sorry to have missed the case referred to, which, however, must have been very exceptional. He was glad to hear Mr. Targett agreed with the view that when torsion occurred in connection with a pyosalpinx, not secondary to the torsion, it was almost certainly a tuberculous pyosalpinx, though this, unfortunately, could not be shown in Dr. Lewers's case.

MAY 4TH, 1904.

EDWARD MALINS, M.D., President, in the Chair.

Present—37 Fellows and 7 visitors.

Books were presented by St. Thomas's Hospital, Boston Lying-in Hospital (U.S.A.), and the New York Hospital Staffs, the 'Deutsche Gesellschaft für Gynäkologie,' and by Dr. C. Hubert Roberts.

James Marr Brydone, M.B., B.C.Cantab., and Edmund Moritz Illington, Capt. I.M.S., L.R.C.P., were admitted Fellows of the Society.

The following gentleman was elected a Fellow of the Society:—Harry Oliphant Nicholson, M.D.Ed., M.R.C.P.Ed.

Report of Pathology Committee on Two Specimens of Diffuse Adeno-Myoma of the Uterus, shown by Dr. WALTER TATE, at Meeting of Society, April 6th, 1904.

WE, the undersigned, agree with the macroscopic and microscopic descriptions of both specimens as given by Dr. Tate and Dr. Dudgeon.

In specimen No. 1 downgrowths of the endometrium can be traced into the central parts of the tumour. In specimen No. 2 the microscopic appearances resemble

closely those of No. 1, with the exception of the presence of areas of degeneration and hæmorrhage in the myomatous tissue and a more cystic condition of the gland tubules. As no endometrial surface is shown in the sections it is impossible for us to decide whether the adenomatous tissue is directly continuous with the mucosa of the uterus.

JOHN S. FAIRBAIRN.
CORRIE KEEP.

April 21st, 1904. ALBAN DORAN, *Chairman.*

TWO CASES OF ENLARGED WANDERING SPLEEN FORMING PELVIC TUMOURS.

Shown by Mr. FRANK E. TAYLOR.

CASE 1.—E. B—, a married woman, aged 32, was admitted into Chelsea Hospital for Women, under the care of Dr. W. H. Fenton, on January 1st, 1904, complaining of pain in the left side, accompanied by sickness and diarrhœa.

She has had two children, the last fifteen months prior to admission into hospital. At this confinement she was kept in bed for six weeks on account of "septic fever." Whilst then lying in bed she first noticed a lump in the right iliac region, and she experienced a good deal of pain in the same situation.

In September, 1903, she attended as an out-patient, and was then found to have a hard mass in the right iliac region, extending inwards as far as the middle line of the abdomen and up to the umbilicus. She was recommended to become an in-patient, but refused to do so.

From this time until admission in January last she has had a good deal of sickness and diarrhœa, having

had two very severe attacks on Christmas Eve and New Year's Eve, and these she called "bilious attacks."

The catamenia were regular, lasting seven days out of every twenty-eight, and the loss was fairly profuse, and unaccompanied by pain or clots. Between the periods there was some creamy white vaginal discharge. Micturition was normal throughout.

On physical examination the heart and lungs were found to be normal. The surface of the abdomen was dark in colour, and there was some intestinal distension in the umbilical region.

Below the level of the umbilicus, and chiefly on the right side, but also extending across the middle line towards the left, was a hard firm mass rising up in the right flank almost to the level of the umbilicus. It was extremely tender on deep palpation. Its surface was smooth and uniform. It presented a well-defined edge, in which no notch could be palpated. Neither could any movement be elicited.

Per vaginam a hard mass was felt to occupy the anterior fornix; it also extended to the left, forming a very large tumour. It was very tender, and only very slight movement could be induced. The uterus occupied the pouch of Douglas behind the tumour, with which it had no connection.

The history of the case, the apparent origin of the swelling during a septic puerperium, and the presence of a hard mass in the pelvis suggested the diagnosis of parametritis. The definiteness of the swelling and the presence of slight mobility entirely negatived this view. The fact that the tumour occupied the pelvis and was free from the uterus caused it to be diagnosed as an ovarian tumour.

The patient's general condition was so bad that operation was deferred until February 19th. In the interval she was kept in bed, and with skilful nursing and appropriate treatment this very considerably improved.

On February 19th, Dr. Fenton opened the abdomen

through a subumbilical median incision, and found the tumour to be an enlarged spleen embedded in the right side of the pelvis and extending up into the right iliac region. After separating the adhesions, the pedicle of the spleen was found to be twisted through two and a half complete turns. The tail of the pancreas was contained in the pedicle, and extended to within two inches of the spleen. The portion of the pedicle intervening between the tip of the tail of the pancreas and the spleen was ligatured by transfixion and cut through, the spleen being thus removed. The abdominal wound was sewn up in three layers.

Except that for a couple of days after operation the patient was somewhat restless, recovery was uneventful, the temperature never reaching beyond 99·8° F., and only touching this figure once on the day following operation. The wound healed *per primam* throughout, and the stitches were removed on the eighth day.

The patient left the hospital perfectly well on March 10th, that is twenty days after the splenectomy.

Examination of the specimen removed showed it to be a uniformly enlarged spleen measuring $8\frac{1}{2}$ inches in length, $5\frac{1}{2}$ inches in breadth, and 3 inches in thickness. It weighs forty-one ounces.

It was softish and elastic in consistence and dark purple in colour. Its peritoneal surface was smooth and glistening and free from adhesions. It was hardened whole in formalin. On being bisected it presented a striking appearance. The whole of the central part of the tumour, forming the major portion of it, was seen to be composed of a large hæmorrhagic mass, bright red in colour. Round this a thin layer of splenic tissue of a dark-brown hue was spread out, with larger accumulations at each end. The capsule of the spleen is also thickened.

The changes observed on microscopic examination are the presence of a large central hæmorrhagic mass in which no trace of splenic tissue is discernible, which is surrounded by splenic tissue, with increased trabecular

connective tissue and thickening of the connective-tissue capsule.

Case 2.—Dr. Fenton kindly informs me that the above is the second case of enlarged wandering spleen occupying the pelvis and simulating an ovarian tumour which had been observed and submitted to operation by him. The first occurred about twelve years ago in his private practice, and he has kindly supplied me with the following notes from memory to incorporate with this communication :—

Dr. Fenton was asked to go to Hampstead by the late Dr. Miller to perform ovariotomy. On examination of the patient, Dr. Fenton found a large mass in the pelvis independent of the uterus. This he agreed was a solid ovarian tumour, associated with ascites.

The patient's general condition was very bad; she was very weak and wasted, and there were many petechiæ all over the body.

Subumbilical median cœliotomy was performed. In the peritoneal cavity much ascitic fluid was found, and this was removed by sponging, and the tumour was then found to be a displaced and enlarged spleen. It was noticed that the spleen was adherent to as much of the abdominal contents as it came in contact with; so much so that it seemed a serious matter to attempt to separate these adhesions, especially in view of the capillary degeneration shown by the petechiæ on the skin, in the adhesions, and on the surface of the spleen. No attempt was accordingly made at their separation, or at removal of the enlarged spleen. The wound was sewn up in three layers.

Shortly after the operation blood began to ooze from the abdominal wound, and continued in spite of all treatment, until the patient died the next day from a combination of shock and hæmorrhage.

It is unfortunate that in neither of these cases was any blood examination undertaken, as this would probably have

thrown some light upon the nature of the splenic enlargement. Nevertheless, there seems little doubt that in the one case, as the specimen shows, the enlargement of the spleen was due to the hæmorrhage caused by the torsion of the pedicle. It is possible that the attacks of pain and sickness which the patient described as "bilious attacks" were in reality caused by distinct hæmorrhages into the spleen. In the other case there can be equally little doubt that the splenic enlargement was most probably due to leucocythæmia, as the subsequent uncontrollable and fatal hæmorrhage from the abdominal wound would suggest.

TWIN MONSTER.

Shown by Dr. Peter Horrocks.

This was a twin blended in the thorax. It was delivered by Dr. Stewart, of Rotherhithe, who was obliged to rupture the membranes as there were no pains. Two left feet presented. He had considerable difficulty in getting the four arms born, but after that was accomplished he was able, by carrying the legs and body backwards, to obtain the delivery of the anterior head, the posterior quickly following. Delivery was accomplished without an anæsthetic. There was only one umbilical cord and only one placenta. The cord terminated in a single umbilicus just below the lower end of the united thoraces.

During the pregnancy, the mother, who was a multipara but only twenty-four years of age, had been greatly frightened by an idiot child living in the same house, who used to come and stroke her and utter unearthly shrieks.

A dissection of the monster may be of interest in regard to the development of two embryos from a single ovum.

Dr. Lockyer noted that Dr. Horrocks drew attention to the fact that there was only one placenta, and he (Dr. Lockyer)

remarked that this is what one would expect with double-headed monsters, inasmuch as they arose from uniovular impregnation, where the ovum possessed but one germinal spot, the monster being due to a subsequent error, viz. a division of the blastoderm, which, being incomplete, had resulted in the twins being conjoined.

FIBRO-MYOMA OF THE UTERUS UNDERGOING SARCOMATOUS DEGENERATION.

Shown by Dr. Peter Horrocks.

This specimen was removed by abdominal hysterectomy in March, 1904. The patient was 46 and single, and had for some years suffered from menorrhagia. In December, 1903, she had some illness, which was thought to be peritonitis, and on examination it was found that she had a large tumour rising into the abdomen out of the pelvis. I first saw her in January, 1904, and recommended no operation, with the idea of conducting her safely over the climacteric. But examining again a month later, I found it was growing rapidly, and so recommended operation. I removed the uterus and tumour in March by abdominal section, and the patient made a good recovery. Appended is a report made by Dr. Leonard S. Dudgeon.

Some authorities still disbelieve in the possibility of sarcomatous change in a fibro-myoma of the uterus. There is no *à priori* reason against it, and this case is one more in proof of it. In the 'Obstet. Trans.' for 1898 I showed a similar case. Doran published a case in the 'Trans. of the Pathological Society,' vol. xli, and Finlay in vol. xxxiv of the same 'Transactions.' There is one significant point common to all these cases, namely, that the tumour was known to have existed for years in the usual state of slow growth, and that it began to grow rapidly shortly before operation or removal.

Pathological Report by Leonard S. Dudgeon, M.R.C.P.

The weight of the tumour was found to be 2 kilogrammes 200 grammes. It consisted of one large solid mass, and several small nodules about the size of a hen's egg firmly adherent to the main tumour. On section, the whole mass except for a firm pale periphery about half an inch in width resembled raw beef, and towards the centre was quite soft and necrotic. The small masses closely resembled the large tumour in longitudinal section. Fluctuation was obtained over most portions of the tumour, but there was no evidence of any suppuration.

A large area at one portion of the main mass was extremely hard, and consisted of dense calcified masses which could only be cut with bone forceps.

There was no evidence of inflammation over the surface of the tumour.

Microscopical histology.—Sections of the tumour were made from the following situations :—(1) Central area of necrosis, (2) area of necrosis and adjoining tissues, (3) area of calcification, (4) firm tissue between the calcified area and the area of necrosis. The specimens were fixed in Orth's bichromate formalin mixture, cut in paraffin, and stained with Mayer's hæmalum and eosin, or orange G, and with Van Gieson's stain.

By Van Gieson's stain we are able to show that a small portion of the whole tumour consists of dense fibrous tissue and delicate muscle bundles. There are large areas of necrosis and fatty degeneration irregularly scattered throughout this portion of the tumour, while the main bulk of the tumour shows almost every variety of degeneration.

In one of the microscopical preparations, a small area of large round cells with very pale and granular nuclei, and some spindle-shaped cells, can be seen to have infiltrated the tissues in all directions. Sections prepared from the softer portion of the tumour are found to consist of cells of all shapes and sizes, but chiefly large

round cells with granular nuclei, some of which stain intensely with hæmatoxylin, and giant cells, some of which contain four or five darkly stained nuclei and almost resemble the giant cells which we meet with in sections of tubercular tissue. Many spindle-shaped cells are also scattered throughout the specimens.

Van Gieson's stain shows that delicate bands of fibrous tissue interlace in all directions throughout the highly cellular regions of the specimens.

In some of the sections cells radiate from the walls of the small blood vessels in a "spoke-shape" fashion and closely resemble what we meet with in specimens of hæm-angeiomatous sarcomata. The small nodules attached to the surface of the main tumour were found to have a similar structure.

Large areas of calcification and numerous small dots of similar structure can be seen in sections prepared from one portion of the tumour, which otherwise consists of degenerated fibrous tissue, sharply marked off from the fibro-myomatous tissue.

This tumour is, therefore, an example of a fibro-myoma which has undergone all forms of degeneration, including sarcomatous degeneration. The main bulk of the tumour appears to be of this nature, and the large areas of degeneration are chiefly situated in the sarcomatous growth.

Mr. Shattock stated that he considered that the growth was a mixed-celled sarcoma.

Dr. Handfield-Jones asked how it was possible to decide in the specimen, which had just been described, whether the sarcomatous degeneration had begun in the substance of the fibroid or had started in the endometrium, and in the course of its extension had involved the fibroid. He narrated a case which had been under his care of a woman aged fifty-six, who had had a fibroid of the uterus which reached up above the umbilicus. After the menopause, which occurred at the age of fifty, this had shrunk down to a short distance above the pelvic brim. During the last eighteen months metrorrhagia had been constant, and the uterus had again enlarged, until it reached the level of the umbilicus. The whole mass was removed by supra-vaginal

hysterectomy, and then the uterine cavity was found to be distended by a large mass of sarcoma, which had also involved the old atrophied fibroid. Probably in this case sarcoma had not originated in the fibroid, but had involved it secondarily.

Mr. Alban Doran doubted whether these tumours, said to be "sarcoma" histologically, were clinically malignant. Ulesko Stroganowa,* examining a large series of uterine fibroids removed in a Russian hospital, made out malignant elements in 10 per cent. of all the cases—a proportion quite at variance with our clinical experience of this familiar new-growth. Mr. Doran suspected that the cells which were large and spindle-shaped might be altered plain-muscle cells. Histological elements of that kind, when subjected to morbid influences, assumed strange appearances, especially when a number were seen in section, cut longitudinally, transversely, and obliquely. He reminded the Society of the drawings of sections of the wall of a cyst of the urachus, reported in the eighty-first volume of the 'Medico-Chirurgical Transactions.' The muscle-cells, originally normal elements in the urachus, assumed very malignant appearances, yet the new-growth was perfectly innocent. There was a great want of after-histories to these cases of malignant degeneration of fibroids.

Dr. Eden said that he had been interested in the subject of sarcomatous changes in fibroids for some years. In 1893 he had exhibited before this Society (vol. xxxv, p. 408) an ovarian cyst in the wall of which he had found a nodule the size of a walnut, which, on microscopic examination, proved to be a sarcoma. The diagnosis was confirmed by the subsequent death of the patient from extensive pelvic recurrence within a few months of the operation. Since that time he had seen two cases of sarcoma attacking a uterine fibroid. He had no difficulty in accepting the fact that a malignant growth might arise in a benign neoplasm just as easily as in healthy normal tissues. But the term sarcomatous or malignant "degeneration" as applied to this process was, he thought, an unhappy one, because "degeneration" implied loss of vitality or death of cells, while a malignant new-growth was characterised by extraordinary activity and proliferation of cells. The process was rather the occurrence *de novo* of a malignant growth in the tissues of a benign neoplasm.

Dr. Peter Horrocks replied that Dr. Handfield-Jones's case was probably a sarcoma from the beginning, because the endometrium appeared to be the starting point. But this was not so in his case, and cases were on record of a fibroid polypus with sarcomatous degeneration in it, and yet where the pedicle was not affected by sarcomatous change. He did not think with

* "Ueber Bösartiges Myom der Gebärmutter," 'Monatsschr. f. Geb. u. Gyn.,' September, 1902, p. 427, and October, 1902, p. 826.

Doran that the change was one in the muscle-cells, thus rendering it a thing peculiar to fibroids, but he believed it to be a real and ordinary sarcomatous change developing from the connective-tissue. Dr. Eden objected to the term degeneration, which, however, was the one usually employed.

A CASE OF ADENO-MYOMA OF THE UTERUS.

Shown by Mr. Frank E. Taylor.

M. F—, single, aged 37, hospital nurse, was admitted into Chelsea Hospital for Women, on March 4th, 1904, under the care of Mr. Bland-Sutton, complaining of pain and excessive loss at the periods. Menstruation now lasted eight days out of every twenty-three to twenty-eight; the loss being excessive and accompanied by some pain. About seven or eight years ago the loss became increased and the duration became longer than it had previously been. This condition became gradually worse, and has been much more marked during the last two years. During the last few months there has been some vaginal discharge between the periods. Micturition has been normal, and the bowels regular throughout.

The patient finds that her vocation as hospital nurse is now much interfered with.

On abdominal examination, some resistance was felt in the right iliac fossa, where there was tenderness on pressure. No abdominal tumour could be felt.

Per vaginam the cervix was found to be soft and patulous: it was directed downwards and backwards. A rounded swelling was felt in the anterior wall of the uterus, and a smooth, regular, hard, rounded mass could be felt to the right of the uterus in the region of the ovary.

The diagnosis of multiple uterine fibro-myomata was

made, and operation—myomectomy, if possible—was decided upon because of the interference with her work which the condition caused.

On March 7th, the patient was etherised and carefully examined under the anæsthetic. The previous findings were confirmed and cœliotomy forthwith performed. The enlarged uterus was exposed, and an incision was made over the tumour in the anterior uterine wall with a view of enucleating it. This proved to be impossible because of the diffuse nature of the growth and the entire absence of any capsule, there being direct continuity of the tumour mass with the uterine wall. Supra-vaginal hysterectomy was accordingly performed, and both uterine appendages were left behind.

The abdominal wound was sutured in three layers. Convalescence was rapid and uneventful, the wound being dressed on the eighth day, when the stitches were removed and the wound found to be completely healed *per primam*.

The specimen, which weighs five ounces, consists of the major portion of an enlarged uterus, which is also distorted by the presence of two small projecting subserous tumours. The uterine appendages, not having been removed at operation, were absent. The uterus measures three inches in length. On extending the incision in the anterior wall of the uterus, the tissue offered much resistance to the knife, being dense and hard. The uterine cavity and endometrium were not discernible.

The body of the uterus, which constituted the upper $2\frac{1}{2}$ inches of the specimen, had walls measuring $1\frac{5}{8}$ inches in thickness. These were seen to be composed of a mass of dense, hard, coarsely-striated, spongy-looking tissue, with striæ running in all directions and without any arrangement into whorls.

There was no attempt at encapsulation of the growth, which was quite diffuse, and appeared to occupy the whole thickness of the uterine wall right up to its peritoneal investment, which, however, was not invaded

by the growth, being quite smooth, glistening, and free from adhesions.

Projecting from the surface of the uterus in the region of the right tubal angle are two small, hard, rounded tumours. The larger one, three inches in its longest diameter, and rather larger than a chestnut, which it somewhat resembles in shape, springs from the right of the fundus uteri above the insertion of the tube. Its peritoneal surface, which is smooth and glistening, is slightly tuberose.

The smaller tumour is $\frac{3}{8}$ inch in diameter: it is the shape and size of a small marble. It projects from the lateral aspect of the body of the uterus, behind and below the tubal attachment. It is also covered by smooth, glistening peritoneum.

Both these tumours are well encapsuled, and on section are hard, white, glistening, and whorled, presenting all the macroscopic appearances of fibro-myomata, and markedly contrasting with the diffuse growth in the body of the uterus.

Microscopic examination of the diffuse growth shows the typical appearances of an adeno-myoma of the uterus, which I have fully described in the 'Journal of Obstetrics and Gynæcology of the British Empire' for March, 1904, that is to say, it consists of interlacing bundles of unstriped muscular tissue running in all directions and enclosing islands of epithelial tubes lined by a single layer of columnar epithelium—uterine glands—surrounded and separated from the muscular tissue by a greater or less amount of richly cellular lymphadenoid connective-tissue.

The two subserous tumours are typical fibro-myomata, being composed of interlacing strands of fibrous and plain muscular tissue, and are quite devoid of glandular elements.

UNIOVULAR TWINS.

Shown by Dr. Cuthbert Lockyer.

Dr. Cuthbert Lockyer showed the placenta membranes and a fœtus papyraceus belonging to a case of uniovular or homologous twins.

The placenta, common to the two fœtuses, was composed of unequal halves which varied much in character. The smaller part, which corresponded to the smaller of the two amniotic sacs, was very thin, hard, and densely fibrotic on section; it contained no calcareous plates, but grated on section like dried-up fibrous tissue. Its maternal surface showed no division into cotyledons, but presented a uniform cake-like mass. To its fœtal aspect was attached the thin, attenuated umbilical cord, which at its distal extremity was united to a fœtus compressus, in which the male sex was just distinguishable by fusion of the two halves of the scrotum.

The larger portion of the placenta was intimately fused with the smaller, although at the junction of the two the tissue was very thin. Its maternal surface was deeply divided into cotyledons, and these appeared quite normal to the naked eye. From its fœtal surface an umbilical cord of normal size and thickness came off. The corresponding fœtus was not shown. The two amniotic sacs were of very unequal size, the one related to the normal part of the placenta being twice the size of the other. The septum dividing the two, and consisting of two layers of amnion, was thick, strong, and complete. The clinical history kindly provided by Dr. Ernest Randall, who sent the specimen to the writer, was as follows:

Mrs. N—, aged 30. Had had one child previously, two and a half years ago. Delivery was spontaneous at the eighth month; no cause could be assigned for the premature labour. Four months later the patient had a severe flooding, which was regarded as an early abortion.

Following this the catamenia had been normal until August 12th, 1903; since then there was a slight show of one day's duration each month until November, when all sign of menstruation ceased. Dr. Randall saw the patient on January 4th, 1904, and found the fundus uteri at the umbilical level, and the patient said she had felt fœtal movements; twin pregnancy was not diagnosed, nor was there any indication of fœtal death. On January 22nd, much abdominal pain was complained of after a very fatiguing day's work. On February 23rd, Dr. Randall examined the patient at 8 a.m., and found commencing dilatation of the os. At 4 p.m. on the same day, spontaneous delivery by a vertex presentation occurred. The fœtus was healthy: it was considered to be a seven-months' child, and lived for two hours only. The placenta was delivered twenty minutes after the birth of the child by "considerable abdominal compression," and this was immediately followed by the compressed fœtus. There was no *post-partum* hæmorrhage, and the puerperium was quite normal.

The simultaneous fecundation of two germinal spots belonging to one ovum is a comparatively rare occurrence. When it does occur, the two children are of the same sex. Veit, as quoted by Clifton Edgar, found that in 429 cases of multiple pregnancy, 383 were from two distinct ova, 46 from a single ovum, and two of these had a single amnion. Dr. Thomas Wilson in a paper on "Hydramnion in Cases of Uniovial or Homologous Twins," read before this Society in 1899, gives binovial twins as seven times more common than those derived from one ovum.

He draws particular attention to the association of hydramnion with this type of twins, and records twenty-two cases of its occurrence, and says its causation is found in the relation of the vessels of the two fœtuses to the common placenta. "The twin whose vessels run a shorter or more direct course obtains an undue share of blood from the placenta, in which anastomoses take place between the vessels belonging to the two fœtuses. In

this way one fœtus grows faster than the other and its heart becomes not only absolutely but also relatively larger than that of the other; that is to say its heart becomes really hypertrophied. This leads in some way to increased uptake of fluid in the placenta and so to increased exudation by this twin. This increased exudation takes the form of excessive secretion, certainly from the kidneys, probably from the skin, and possibly also from the portion of placenta belonging to the affected fœtus; and the accumulation of these discharges leads rapidly to enormous hydramnion of the fœtus."

In the 'Transactions of the Obstetrical Society' for 1890, Graily Hewitt describes one case similar to those to which Wilson drew attention, and Edgar, quoting Ahlfeld, says, "There may be a marked amount of fluid in one sac and very little in the other."

Other abnormal conditions which may be found associated with homologous twins are fœtal atrophy or acardia and fœtus papyraceus (of which the present specimen is an example). Vesicular degeneration of the chorion, albuminuria, placental disease, velamentous insertion of the cord are complications which may be met with in this as in any other type of twin pregnancy, whilst double-headed monsters will have a different explanation, these not being the result of the spontaneous fecundation of two germinal spots, but due to the partial fusion of the single blastoderm. A section taken through the junction of the quick and the dead part of the placenta and also another showing the structure of the former at its thickest part and at a considerable distance from the latter, were exhibited.

A large unorganised hæmorrhage surrounded by maternal decidua and by chorionic villi was seen at the junction of the dead and living portions of the placenta. The dead tissue showed chorionic villi in an advanced stage of fibrosis and hyaline degeneration, totally devoid of syncytium and Langhans' cells and with their vessels occluded by fibrous tissue. Areas of round-celled

infiltration existed between the decidua and the chorionic villi. The villi were for the most part packed closely together, but here and there fibrinous areas existed between them. The living placenta at its junction with the dead part and for the space of two centimetres distant, was chiefly characterised by the enormous size of its vessels. This was not due to atonic dilatation, since in addition to the increased lumen the walls were very much hypertrophied. The close proximity of such vessels to the free hæmorrhage above referred to as having existed at the junction of the quick and dead parts, would seem to suggest that there had been an attempt made by the living fœtus to send blood through the dead portion after the vessels of the latter had been occluded.

The villi in the living part were quite normal in appearance, not only as seen in the examination of the section taken at some distance from the "junction" but even where the two portions (dead and living) met, the transition from dead, fibrotic, and hyaline chorionic villi to normal villi being abrupt.

NECROBIOTIC FIBROID REMOVED FROM A RECENTLY DELIVERED PATIENT AGED TWENTY-TWO.

Shown by Dr. J. S. Fairbairn.

This specimen is shown as a good example of necrobiotic change in a uterine fibroid removed from a patient who was confined some five weeks previously. It is also of interest as showing the difficulty of arriving at an accurate diagnosis, for the age of the patient and the symptoms to which it gave rise were more suggestive of some inflammatory mischief in the pelvis than of a fibroid of the uterus.

The simplest way will be to begin with the clinical history of the case. The patient, aged 22, had always had good health ; the catamenia were regular, and small in amount, but there was slight dysmenorrhœa for the first two days of the period. She had been married thirteen months, and was confined of her first child on March 10th. During the later months of her pregnancy she suffered considerably from a sharp pain shooting from the right side to the vulva, but no lump or tender spot was noticed in the abdomen. As the account of the delivery and puerperium is of considerable importance, the notes of this part of the history have been obtained from Dr. Mordaunt Wheler, of Battersea, under whose care she was. Dr. Wheler saw her for the first time when she was in labour, and though he had his hand on the uterus for some time after the expulsion of the placenta and membranes, which came away entire, he did not detect any defined swelling of the uterus. The labour was not a protracted one, but forceps were used to complete delivery when the head was low down, as the patient showed some signs of exhaustion. For the first few days of the lying-in period nothing unusual was noticed : there was no rise of temperature, the lochia were normal and on non-offensive. About the fifth day the temperature began to rise, and for the next three or four weeks continued to do so until her admission to hospital, reaching 100° and on one occasion, early in the illness, 102°, that being the highest recorded. A tender swelling was first noticed on the sixth day. It appeared first on the right side, but later became more median in position, and was thought to be connected with the uterus. Dr. Turner, who was called into consultation with Dr. Wheler on March 22nd, thought that there was some infiltration of the right broad ligament. As the tumour appeared to vary in size from one day to another, a catheter was passed to exclude involvement of the bladder. The question of retained products of conception with subinvolution of the uterus was discussed, but in the absence of hæmorrhage or of

any morbid change in the lochia, no exploration of the uterine cavity was undertaken. About the third week, a second tumour was noticed higher up on the right side and was thought to be ovarian. The tumours were always markedly sensitive to pressure. On April 6th the patient got up for the first time to come to the hospital, and I saw her in the out-patient department of St. Thomas's. She was anæmic and looked ill, and had a temperature of 100°. On examination of the abdomen, two apparently distinct swellings could be made out; one, a central swelling above the pubes, rising up out of the pelvis, and another movable swelling in the right iliac fossa, extending from within an inch of the anterior superior spine to a finger's breadth above the umbilicus. They were both very tender to palpation. *Per vaginam*, the tumour in the right iliac region could not be reached from below; on the left side an elastic fluctuating swelling, closely incorporated with the uterus and apparently fixed, was found to bulge down the anterior fornix. The tumour in the right iliac fossa was thought to be an ovarian cyst, either inflamed or with a twisted pedicle, while the median fluctuating swelling adherent to the uterus was thought to be an intra-pelvic abscess or a suppurating ovarian cyst. The patient was admitted to the hospital under Dr. Tate, and examined by him two days later. Dr. Tate found much the same condition as was noted in the out-patient room. A definite sulcus could be made out between the tumour on the right side and the mass in the hypogastric region. The former he considered to be an ovarian cyst with a twisted pedicle, while the lower swelling connected with the uterus was looked upon as a cyst of the left ovary, probably a dermoid, as it did not appear to be fixed enough for a suppurating mass. During her stay in the hospital the temperature did not rise above normal and the patient improved considerably in appearance.

Abdominal section was performed by Dr. Tate, on April 14th, when both swellings were found to be connected

with the uterus, forming one tumour of an hour-glass shape, the division into two masses being formed by a very definite constricting band. The tumour grew from the right side of the uterus and invaded the right broad ligament, and appeared to be constricted at the place where it expanded into the ligament. The tumour was enucleated from its bed, but as the cavity left in the uterus was very ragged and did not contract down, the body of the uterus was removed by supra-vaginal amputation, the left tube and ovary being left. The patient made a good recovery, though the abdomen had to be reopened on the fourth day for intestinal obstruction, due to constriction of bowel by a piece of omentum adherent to the stump.

The tumour removed weighed 1 lb. 9½ oz.; it was soft, and showed throughout on section the fleshy-red, raw-beefsteak appearance which is characteristic of this form of necrosis. At one pole definite thrombosis of the vessels could be seen. It had a slight stale odour. Broth cultures from the centre proved sterile. Microscopically, the tissue showed the usual signs of necrosis in the extensive disappearance of nuclei, leaving the wavy fibres stained by the ground stain. There was also some engorgement of the vessels, and a little hæmorrhage into the tissues, but the necrosis was the chief feature as shown by the microscope.

The specimen illustrates many of the points referred to in a paper on this necrotic process, in the 'Journal of Obstetrics and Gynæcology of the British Empire' for August, 1903. First of all the frequent occurrence—nearly 40 per cent. of cases—in connection with pregnancy or recent delivery, as well as the fact that the change appears to be a fairly acute one and to occur in patients of all ages. It is certainly not a senile change. The necrosis is evidently either a vascular change or due to bacterial invasion. As it does not appear to be due to the latter, it is in all probability due to interference with the blood supply. The thrombosis noted in this

specimen would appear to confirm this, but there is nothing to show how it is brought about. Its clinical manifestations, too, are interesting. The slight rise of temperature, with some constitutional effects, the pain and tenderness of the tumour, together with the softness and sense of fluctuation, give rise to the impression of an inflamed cystic swelling, and the most frequent error in diagnosis, that of ovarian cyst, with torsion of its pedicle, was made. As was shown in the paper referred to, the change probably begins during pregnancy, indicated in this case by the pain, but is hastened by the retraction of the uterus during the puerperium. No doubt this also explains why the tumour was not detected until, by the diminution in the size of the uterus, it became separated from the uterus and so easily recognisable as a distinct mass.

NECROBIOTIC FIBROID.

Shown by Dr. Florence N. Boyd.

Mrs. Boyd showed a specimen of a uterus containing an interstitial fibroid in a state of necrobiosis removed by abdominal panhysterectomy from a patient of 45, who was admitted to the New Hospital for Women with a left-sided strangulated femoral hernia. A successful operation for this latter condition was followed on the third day by thrombosis of the left internal saphenous vein accompanied by slight œdema of the leg. The patient was kept strictly at rest, and no extension of the thrombus was observed. The femoral wound healed by first intention. On the eleventh day after operation the temperature rose, and in two days reached 103·8°, the patient complaining of pain in the region of the wound. Examination showed a re-

sistance to the left of the mid-line reaching halfway to the umbilicus, extending into the anterior and left fornices, and displacing the cervix to the right. There was extreme tenderness over the whole mass, rendering a satisfactory bimanual examination difficult, and the examination was followed later by a rigor (103·4°) and a pulse of 140. A diagnosis of a deep septic cellulitis in relation to the operation was made, but an incision above Poupart's ligament, with the object of reaching pus extra-peritoneally, showed the mass to be a fibroid in the anterior and left wall of an enlarged uterus. The wound was closed, as it was uncertain whether some degenerative change in this fibroid was the cause of the fever, or some general septic condition connected with the thrombosis of the saphenous. The fever continued with occasional rigors, and pain and swelling of the metacarpo-phalangeal and right shoulder joints appeared, but lasted only a short time. The patient lost ground rapidly and became very ill, and it was decided, after consultation, to remove the uterus and fibroid. Immediately before operation local peritonitis was noted to have set in. At the operation some turbid fluid was found in the peritoneal cavity, and adhesions of some standing were found round the fibroid in the left side of the pelvis. On manipulation pus oozed from a small opening in the anterior part of the fundus. A panhysterectomy was done, the intestines turned out and freely washed with saline, and the peritoneal cavity drained through the vagina by tube and iodoform gauze, and in both lumbar regions by gauze. The fever continued after operation, and the patient was only now, five weeks after operation, slowly recovering.

The specimen consisted of the entire uterus, containing a solitary interstitial fibroid (5 inches by 3 inches), which showed a whiter peripheral portion continuous with the uterine wall, and a central red portion resembling on section raw beefsteak. In the peripheral portion were numerous sinuses, from which, on pressure, thick pus oozed. Bacteriological examination of the fresh pus, of a

culture from the pus, and stained sections of the peripheral and central portions of the tumour showed the presence of large diplococci lying between the pus cells; and besides these, numerous cell-colonies of minute biscuit-shaped diplococci, six or eight pairs of which appeared to lie in some cases inside the polynuclear leucocytes. The exact nature of these organisms remained doubtful. The sections were stained by methylene-blue and tannic acid, also by Gram's method, and were prepared by Miss Woodcock, M.B., pathologist to the New Hospital for Women, who also reported on the histological appearances of the sections: "In the peripheral portion the structure is that of an ordinary fibro-myoma, but the nuclei do not stain as well as usual, and in places, especially around the veins and venous sinuses, there is an infiltration with small round cells and polynuclear leucocytes, amounting in some sections to an abscess formation. In one artery there is thickening and inturning of the wall and proliferation of the intima, as described by Dr. Fairbairn. The section of the central portion shows advanced necrotic change. Very few nuclei are present, and the ground-substance stains reluctantly with eosin. There is no leucocytic infiltration in this central part."

LITHOPÆDION OF FOURTEEN YEARS' DURATION SUCCESSFULLY REMOVED.

Shown by Mr. Hedley C. Bartlett.

Lithopædion is a very rare condition, and, from what I can gather, I should say ultimately lithopædion will have a tendency to become rarer still, for this reason: that the advances which have been made in pelvic surgery will entirely do away with the condition, because as soon as a tubal pregnancy is diagnosed the abdomen is opened, the

tube containing the fœtus is removed, consequently doing away with all further likelihood of a lithopædion forming.

In this paper I do not intend to deal with cases of lithopædion which have been endeavouring to find an exit from the abdomen, probably for some years, through the various lines of least resistance which they generally take; but I only intend to deal with those cases which have been found by examination, diagnosed, and removed by laparotomy. The former kinds of lithopædion are so frequently met with, and are not of so much interest as those which have been sequestrated for several years and then diagnosed and removed by the surgeon. These latter cases are extremely rare. I have looked up the literature of these cases in the College of Surgeons' Library, and in this paper I shall refer to a few notes of the cases which I have come across.

The first case which I will relate is my own case, and which forms the subject of this paper.

H. H—, aged 49, having the following family history: Mother died of cancer of the womb.

Personal history.—She was 25 years old when married. The catamenia were delayed until 19 years old. Ten months after marriage she became pregnant and carried for three months, and then miscarried. She was then laid up for five months (with inflammation of the womb). Then she had three years' interval of good health. She again became pregnant, and she carried for four months, and then miscarried again. Two months after this miscarriage she again became pregnant and carried for seven months. She is then said to have miscarried again. She was ill for six weeks; considerable hæmorrhage, sudden pain which lasted an hour, and she was in bed for two weeks; and this was fourteen years ago. She was irregular as regards her catamenia until she was 42 years old, when the catamenia ceased. Six years ago she saw Dr. Routh in London, who told her that she had a fibroid, which would probably disappear after the change of life. Dr. Routh sends to me the following note which he made at

the time: "Hard exudation behind and to the right of uterus, probably subsiding acute peritonitis."

State on examination.—Uterus low in pelvis, very tender, pushed somewhat forward, somewhat fixed, sound passes readily, offensive discharge. In Douglas's pouch and perhaps a little more to the left can be felt an extremely hard and rounded swelling the size of an orange, absolutely fixed posteriorly and also fixed to uterus. It is due to this fixity that probably the uterus is fixed in pelvis; therefore the uterus is indirectly fixed, not directly. The finger cannot be passed above and behind the tumour, which presses considerably on and into the rectum. The swelling on examination through the rectum can be readily felt and gives the feeling of a hard, bony, rounded mass with a sharp projection. The hardness is different, however, from the hardness of a malignant growth. Examination was intensely painful.

The different conditions which pass through one's mind with such a swelling might be :—(1) Malignant disease of the left ovary and tube; (2) a bony growth extending from the back of the sacrum; (3) a fibroid tumour of the uterus, which had undergone some calcareous change; (4) a stone which had ulcerated through from some neighbouring organ; (5) a dermoid tumour of the ovary; or (6) a Fallopian tube which had undergone some calcareous change; and this latter was the view I inclined to.

I suggested the abdomen should be opened. The operation was performed on October 9th, 1903.

On passing the hand into the pelvis on the left side of the uterus could be felt the swelling above described, but buried very deeply by adhesions and coverings. These were torn and broken through, when at once some very sharp points were felt. One was loosened and detached and removed, and a humerus was delivered. This cleared up the mystery, and by still further careful manipulation the whole of the specimen which I now show was removed. The grave where it had been lying was

carefully mopped out. The left ovary and tube could not be made out at all—appeared to be absent. The right ovary and tube were normal. The abdomen was closed in the usual manner and the patient made an uninterrupted recovery. The temperature during the whole of convalescence was normal.

The lithopædion which I removed weighs 1 oz. 2 drams 40 grains, and measures in its greatest length 2½ inches and round its greatest breadth 4¾ inches. Probably it looks like a four or five months' fœtus, but might be more owing to shrinkage.

Other cases.—The notes of the following cases of lithopædia will be of interest:

Case No. 1.—This case was reported by Andrew Currier, of New York, in 1898, in the 'Gynæcological Transactions of America.' Some bones had been discharged through rectum, making diagnosis easy. This case was laparotomised.

No. 2.—A case related by Walter Tate, in 1902, in the 'Obstetrical Society's Trans.,' vol. xliv, which was diagnosed as a dermoid cyst of the ovary. A lithopædion was found of sixteen years' duration.

No. 3.—Another case of lithopædia related by Bryant in the 'Guy's Hospital Reports, 1901,' a lithopædion causing acute intestinal obstruction by being adherent to the ileum in two places. Pregnancy had never been suspected. On opening the abdomen the lithopædion was found. This case did not recover.

Remarks on Lithopædia.—There are many interesting cases on record of lithopædia which have migrated from their position into other parts of the body in their efforts to get out. In one case a lithopædion had wandered into the umbilical hernia. I believe another case Professor Humphry removed piecemeal through the rectum.

It used to be a question whether, supposing lithopædion was diagnosed, one would be justified in opening the abdomen to remove it, but now there is no such question.

The difficulty in these cases of lithopædion appears to be in the diagnosis, and in several of those cases which I have referred to besides my own—in three of the cases at least which I looked up—fibroid tumour of the uterus had been diagnosed; for this reason, probably, that the lithopædion is very adherent to the uterus, and can be felt as part and parcel of the uterus and cannot be moved independently of the uterus, for there is no doubt that the tendency of the lithopædion is to form very tense, hard adhesions of a strong fibrous nature bleeding readily on interference.

There is no doubt that lives have been lost by allowing these lithopædia to wander about the abdomen gaining fresh adhesions to important organs and probably especially in getting in contact with the bowel, whereby gases are absorbed, causing the lithopædion to lay in a suppurating sac and therefore causing a double danger.

There have been one or two interesting lithopædia found *post mortem* which probably during life gave no trouble, one specimen in the Middlesex Hospital and one in the College of Surgeons' Museum.

It is interesting to note also that a woman may have a lithopædion or a macerated skeleton of a fœtus between the layers of the broad ligament, and yet conceive in her uterus. Stonham relates such a case.

The term lithopædion does not mean that the fœtus is converted into stone, but that its tissues are impregnated with limesalts (calcification).

If we could insure that these migratory fœtuses would remain quiet between the layers of the mesometrium, we might be inclined to leave them alone, but the whole tendency of modern surgery for safety is to remove them.

Probably in my case the rupture took place in the tube lying between the layers of the left broad ligament close to the uterus, and extending backwards under the peritoneum and invading the connective tissue round the rectum.

My reason for thinking that the tube ruptured in that position is due to the fact that the patient has had for years an offensive discharge dating quite from the time when she is said to have miscarried, and also to the fact that the pain which she had at the time of rupture did not give rise to much shock and soon passed off.

HÆMATOMA AND HÆMATOCELE; A STUDY OF TWO CASES OF EARLY TUBAL PREGNANCY.

By Alban Doran, F.R.C.S.,
SURGEON TO THE SAMARITAN FREE HOSPITAL.

(Received January 11th, 1904.)

(*Abstract.*)

It is generally taught that hæmatocele associated with interrupted early tubal gestation demands operation whilst a hæmatoma or extra-peritoneal hæmatocele under the same conditions will subside if the patient be kept at rest. Two cases which do not support this teaching are related and discussed at length. In the first, the patient passed clots over two months after the last period, pelvic pain set in and a swelling could be detected in the right fornix and iliac fossa. A week later a decidua was expelled, then a mass with all the characters of a pelvic hæmatocele developed and became harder and smaller during prolonged rest. Menstruation was re-established within two months. In the second case the patient was seized with vomiting and pain in the right iliac fossa when a period was due. Four days later uterine hæmorrhages set in. A swelling could soon be defined above the pubes, its lower limits formed a convex mass behind the cervix, simulating a hæmatocele in Douglas's pouch. This swelling steadily increased in size. A month after the beginning of the symptoms a decidua was passed, eleven days later acute internal hæmorrhage occurred. The author operated and discovered a very large hæmatoma containing four pounds of old clot. The uterus, appendages, and pelvic peritoneum were entirely above the clot and formed its capsule. The right tube had burst between the folds of the broad ligament so that a hæmatoma developed and ultimately leaked into the peritoneal

cavity which contained a little recent clot. The uterus and appendages were removed with the clot, the cervix was saved. A show of blood was seen twice within seven months after the operation. The nature of the first case was evident, there was a bleeding tubal mole on the right side and a pelvic hæmatocele as its consequence. The lower part of the hæmatocele formed a convex mass in Douglas's pouch. According to Taylor and other authorities this condition rarely ends in spontaneous cure, but Veit, Champneys, Lockyer, and Gossmann are of a contrary opinion on the ground of clinical experience, and this case, like several others recently under the author's care, was cured by prolonged rest. The author admits, however, that convalescence is usually more rapid when the tubal sac is removed, although operation involves cicatrices and retained ligatures. In the second case it was proved at the operation that there had been originally no hæmatocele whilst a great quantity of blood escaped between the folds of the broad ligament. The blood had raised up the peritoneum of Douglas's pouch which encapsuled its upper part, as in the case of a large cyst or fibroma of the broad ligament. The convex mass behind the cervix was therefore not in Douglas's pouch, which did not exist, but represented the lower limits of the entirely subperitoneal hæmatoma. The acute symptoms were caused by secondary rupture into the peritoneum. The hæmatoma was the homologue of the posterior tubo-ligamentary pregnancy of Taylor, but the products of conception had been completely destroyed. The secondary rupture into the peritoneal cavity was the homologue of Taylor's fourth class of tubo-abdominal pregnancies. The author suspects that in other cases a hæmatoma behind the cervix has been taken for a hæmatocele in Douglas's pouch. Hence hæmatoma is probably not so rare a result of interrupted extra-uterine pregnancy, and not so amenable to expectant treatment as is generally taught, its dangers being underrated. Hæmatocele is certainly very common and its perils have been apparently overrated. Careful clinical study of these conditions is yet needed.

The question of operative or expectant treatment in early extra-uterine pregnancy is of high importance, but remains unsettled. For authorities are not agreed as to

what is the best course to pursue when hæmorrhage sets in and stops the early abnormal pregnancy. Hæmatocele, the result of intra-peritoneal hæmorrhage, may undoubtedly subside as has been demonstrated by the experience of authorities to whom further reference will be made, and by a case in my own practice presently to be related. A majority of gynæcologists, however, hold that hæmorrhage into the peritoneal cavity even when due to a bleeding mole and not to rupture of the tubal sac demands operation. On the other hand, all authorities appear to admit that hæmatoma, the result of hæmorrhage into the pelvic connective-tissue outside the peritoneal cavity, is far more likely to be absorbed, and therefore does not as a rule render operative interference urgent. Even Taylor who insists that cases of intra-peritoneal hæmorrhage from a ruptured tube or tubal mole rarely recover without operation,* at the same time admits that when the tubal sac ruptures into the connective-tissue space below the peritoneum a hæmatoma is the result, and in some instances the pressure and disturbance caused by this collection of blood is sufficient to stop the progress of the misplaced pregnancy. When this is the case, the hæmorrhage is slowly absorbed, and if the pregnancy be early and abortive, the products of conception undergo absorption also.†

Roughly speaking, then, we are taught by certain living writers of repute that a hæmatocele implies great peril and demands operation, whilst it is generally admitted that a hæmatoma ‡ represents a far less dangerous ending to an interrupted tubal pregnancy, and will subside if the patient be kept at rest.

The two following cases are of some interest because they do not support this teaching. For in the first there

* 'Extra-Uterine Pregnancy,' p. 148.

† *Loc. cit.*, p. 64.

‡ That is to say, subperitoneal hæmorrhage, as defined above. The term "tubal hæmatoma" applied to hæmorrhagic mole is confusing, and is therefore not employed in this communication.

were all the signs of tubal abortion with hæmorrhagic mole and pelvic hæmatocele, yet the patient recovered and the hæmatocele underwent absorption. In the second, a hæmatoma developed, but though the patient was kept at rest in hospital, the effusion of blood did not subside. On the contrary, it ruptured its capsule so that intra-peritoneal hæmorrhage occurred, rendering immediate operative interference needful.

Case 1.—Bleeding Tubal Mole and Pelvic Hæmatocele.

Clots passed over two months after last period, with pelvic pain and swelling in right fornix and iliac fossa; decidua passed a week later, a mass with the characters of pelvic hæmatocele then developing and gradually becoming harder and smaller. No operation; prolonged rest. Period re-established within two months, becoming regular.

E. H—, aged 24, was admitted into my wards in the Samaritan Free Hospital on February 11th, 1903, for symptoms indicating ectopic gestation.

She had been married for over six years, and had been twice pregnant. The first child was five years and nine months old, and was delivered at the seventh month by forceps; the second was one year and eight months old, and was delivered by forceps at term. Both children were reared, and the puerperium was uncomplicated after both labours. At the age of thirteen, this patient had been under treatment for anæmia, but she had never suffered from any serious illness.

The catamenia recommenced and continued regular during lactation after both labours, but the second child was only suckled for six weeks. There was scanty show every third week with much pain.

The last period occurred in the first week in December, 1902. On February 7th, 1903, over two months later, some clots passed, and there was much pelvic pain. Hæmorrhage continued, especially at night. Dr. Williams, of Connaught Street, was called in on February 11th, and

found the patient in severe pain, with a temperature of 101°, and a pulse of 120. She complained of much bearing-down pains at night, and was at once sent to the Samaritan Hospital.

The patient was very anæmic and thin, but quite free from cachexia or depression of spirits. I detected much distension in the right iliac region with tenderness on palpation and resonance on percussion. No hard body could be defined. The uterus was almost fixed, the right fornix was occupied by a tender mass of about the size of a walnut, hardly encroaching on Douglas's pouch but connected with the swelling in the corresponding iliac fossa.

On February 13th, the distension was more marked, very resonant and much less tender. The uterus was more fixed and displaced forwards, the mass in the right fornix larger. In the afternoon the decidua, which I now exhibit, was passed. The temperature was 100·2°, the pulse 132. There was absolutely no shock nor pain. The passage of the membrane afforded relief and I decided to wait for awhile before operating.

On the morning of February 14th, I detected a firm mass in the right iliac fossa, cup-shaped with the convexity upwards and extending across the middle line. The shrinking of the dimensions of this mass was very appreciable day by day. By the 20th it was quite hard and round; the show, for the first time since admission, was absent. By March 2nd the pelvic condition was more evident than before, for there was a firm insensitive convex body in the posterior fornix continuous with the mass above the right groin. The uterus was drawn up in front of the mass, the cervix lying against the pubes.

The whole mass steadily contracted, and on March 23rd, when I discharged the patient, it projected three inches above the pubes, lying more in the middle line than before. On April 6th I had an opportunity of examining her. The uterus now moved with a convex mass which occupied the posterior and right fornices. The fundus

could be clearly defined and the upper part of the mass did not extend above the level of the fundus. On April 9th a true period with molimen occurred, lasting five days, and the show was rather free. A little powdery, brownish blood was occasionally discharged until the end of April. Then the period became regular; by the end of June the mass behind the uterus had greatly diminished and the patient was in excellent health. I noted distinct pulsation at the base of the right broad ligament, as is observed in a tubal pregnancy still in progress. At the end of July the anæmia had almost disappeared and the pelvic pains had passed away. I afterwards heard that the patient was in very good health in October.

This case was to all appearances an instance of bleeding tubal mole * on the right side and development, subsequent to the expulsion of the decidua, of a pelvic hæmatocele. That hæmatocele was cup-shaped above and formed inferiorly a convex mass projecting into the posterior vaginal fornix. In other words, its lower part really occupied Douglas's pouch (Fig. 1). This relation of the clot is of importance in association with the next case, where also a convex mass projected into the posterior fornix, but did not occupy Douglas's pouch, since that serous fold had been completely displaced by extra-peritoneal hæmorrhage.

I have repeatedly verified this combination of tubal mole and pelvic hæmatocele on the operating table; indeed,

* I need not dwell on the pathology of this condition on which so much light has been thrown by Cullingworth, Bland-Sutton, Lockyer, Handley, and others, as this communication deals with the question of intra- and extra-peritoneal collections of blood rather than with tubal mole. I may as well note, however, that whilst in rupture of a tubal sac immediate, free, and dangerous hæmorrhage is the rule, in tubal abortion it is said to be the exception, yet Gottschalk ('Zentralbl. f. Gynäk.,' No. 4, 1903, p. 113) reports a case of free hæmorrhage at the commencement of a tubal abortion. Is this exceptional condition so rare, and is the rule about hæmorrhage immediately on the rupture of the sac so invariable? I suspect not. The question is interesting, as I am discussing another theory about rule and exception in cases of tubal pregnancy.

it must be familiar to all well versed in the surgery of the female pelvis. Masses of clot are discovered concealing the pelvic viscera. The uterus, the unaffected appendages and the conspicuous tubal mole come into view when the clot is removed. Below and behind Douglas's pouch is found full of blood, fluid or otherwise. Thus the effused blood, save that which is still inside the tubal mole, lies outside the uterus and appendages which it covers up

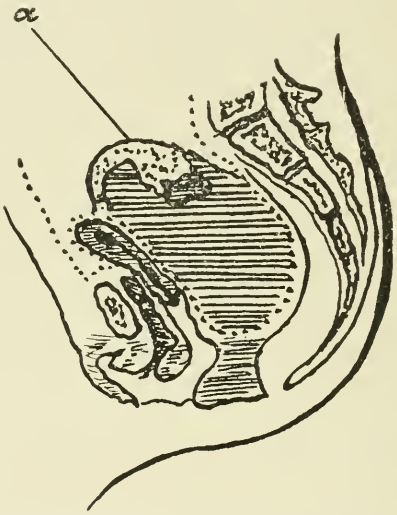

Fig. 1, Case 1.—The dotted line shows the peritoneum of Douglas's pouch in normal position. The clot fills the pouch. (*a*) Fallopian tube containing a tubal mole which caused the hæmorrhage.

more or less completely. In the next case, on the contrary, the uterus, tubes and broad ligaments completely covered the great collection of effused blood, only a small amount of which was beginning to escape into the peritoneal cavity by leakage from the broad ligament.

Taylor, whose demonstration of intraperitoneal hæmatocele is well-known for its clearness, teaches that "in women it is almost always caused by tubal pregnancy, sometimes by rupture of the tube and sometimes by bleeding from the fimbriated end without rupture. *The latter*

is the more common cause of intraperitoneal hæmatocele, and this bleeding from the unruptured tube is usually set up by the presence of a hæmorrhagic mole within it." *

Turning to treatment, the opinion of the same authority on that important matter is not so generally accepted as is his interpretation of the morbid anatomy of the condition in question. He maintains that an operation is always needed in cases of rupture of the tube and tubal mole (*loc. cit.*, p. 148) where these hæmatoceles develop, the collection of blood being, in his opinion, "almost always" due to those complications (p. 65). He states that "occasionally, here and there" a patient recovers without operation, and admits that he has seen five or six such cases (p. 148). He declares that "natural cure is rarely satisfactory and that it contrasts somewhat unfavourably with operative methods" (p. 149).

Many gynæcologists follow Taylor's principles, but experience has shown that he has overrated the perils implied by the development of a hæmatocele. I have had under my care a considerable number of cases during the last few years that have done very well without operation, though I, as well as certain more thorough advocates of expectant treatment, must make allowance for errors of diagnosis, the more so as I shall explain how another variety of hæmorrhage in ectopic gestation, namely hæmatoma, may be mistaken for hæmatocele.

I admit that convalescence is without doubt more rapid after operation, but in my cases of spontaneous recovery the patients remain perfectly comfortable, with no abdominal cicatrix and with no ligatures on stumps, complications always to be dispensed with if possible. But several authorities are even more conservative than myself. My colleague, Dr. Lockyer, has published a valuable critical review on this question. (†) Champneys'

* *Loc. cit.*, p. 33.

† "The Conservative or Expectant Treatment of Extra-Uterine Pregnancy," 'Journ. of Obstet. and Gynæc. of the Brit. Empire,' vol. ii, p. 173. See also, for a recent instructive discussion on the same theme,

statistics are familiar to us all,* but Lockyer also dwells upon the opinion of Veit. That gynæcologist lays down a principle in direct contradiction to Taylor's teaching. "We cannot assert," says he, "that when the ovum is dead dangers are absent. We can, however, state that subsequent to death of the ovum a favourable termination is much more probable. *These cases will mostly recover without help.*" Lockyer himself concludes that the conservative treatment of ectopic pregnancy in the earlier months has established for itself a secure position in modern gynæcology. It is specially satisfactory in the treatment of tubal mole and diffuse hæmatoceles. Gossmann also believes in the frequency of spontaneous cure.†

When we turn to hæmatoma, sometimes called extra-peritoneal hæmatocele, Taylor differs from many of us as to its relation to ectopic gestation. He demonstrates how a tubal sac may burst so as to discharge the ovum into a space which it makes for itself by forcing apart the layers of the broad ligament. In consequence, an anterior or posterior tubo-ligamentary pregnancy develops. Taylor's theory is generally accepted, being based on sound anatomical and pathological evidence, and in fact we all admit that the ovum may lie between the layers of the broad ligament. That being the case we must further allow that blood from a ruptured tubal sac may also force itself into the broad ligament, in other words it will form a hæmatoma. Nevertheless, Taylor teaches that hæmatoma of the broad ligament is only in the minority of cases due to tubal pregnancy (*loc. cit.*, p. 65).

I am of opinion that hæmatoma is more frequently the result of extra-uterine pregnancy. In the case which

Gustav Klein, "Operiren oder Nicht-Operiren bei Eileiter-Schwangerschaft und Haematocele?" 'Monatsschr. für Geb. u. Gyn.,' December, 1903, p. 897. The conflicting evidence of Klein and Gossmann deserved consideration.

* "A Contribution towards the Study of the Natural History of Tubal Gestation, illustrated by a Series of Seventy-five Original Cases," 'Journ. of Obstet. and Gyn. of Brit. Empire,' vol. i, p. 585.

† Gustav Klein, *loc. cit.*

I will now relate the extra-peritoneal position of the clot and displacement of the pelvic peritoneum were made very manifest at the operation. There was a source of fallacy which led me to suspect before the operation that the clot lay in Douglas's pouch. I cannot help thinking that many cases of hæmatoma have thus been diagnosed as hæmatocele.

CASE 2.—HAEMATOMA FOLLOWING RUPTURE OF TUBAL SAC.

Pain in right iliac fossa and vomiting when period was due, four days later hæmorrhages and swelling above pubes steadily increasing and forming below a convex mass simulating a hæmatocele. Decidua passed over a month after beginning of symptoms—eleven days later acute internal hæmorrhage; operation, hæmatoma containing four pounds of clot discovered, uterus, appendages and pelvic peritoneum forming its capsule, right tube opening into hæmatoma which leaked into peritoneal cavity. Removal of uterus, appendages and clot; recovery.

A. B—, aged 31, was admitted into my wards in the Samaritan Free Hospital on March 14th, 1903, with symptoms indicating ectopic gestation.

She had been married eleven years, and her first pregnancy ended normally two years after marriage. Two years later, when in the seventh week of her second pregnancy, she received a blow in the eye and aborted; the curette was used in the Queen's Hospital, Birmingham, shortly afterwards. The third pregnancy ended one year and a half later at term; the fourth also terminated normally, on March 23rd, 1902, but hæmorrhages occurred during the puerperium and lasted for eleven weeks, when Dr. Davidson, of Shepherd's Bush, plugged the uterus and the bleeding ceased. The child had died in the fourth week.

The catamenia returned and were regular until January 14th, 1903, when free show appeared, lasting for four or five days. A fortnight later the patient

suddenly "felt very languid." On February 15th, sharp pain was felt in the right iliac fossa, and she vomited twice. On the 19th hæmorrhages set in; they were slight, but the pains increased. Dr. Davidson kept her at rest, and on March 8th detected a lump above the pubes. She was seen a few days later by Dr. Lockyer, who sent her into my wards, having diagnosed ectopic gestation.

The patient, on admission, was slightly anæmic; she had been slightly so for several months. The abdomen was distended with flatus and very tender to touch. A firm deposit could be felt in the hypogastrium, its upper limits lay within three inches of the umbilicus, and the blunt-edged fundus of the uterus could be defined high on its anterior surface.

On vaginal examination, I detected a big, firm mass uniformly convex, in the posterior fornix, which made me suspect that it must be in Douglas's pouch, a hæmatocele in fact; but it proved, as will be shown, to be extra-peritoneal. The cervix was small and pushed upwards and forwards. Very distinct pulsation could be felt in both lateral fornices.

The temperature on admission was 102° in the mouth, at the end of a week it dropped to 99°, then it rose to 100° at night and never fell to normal; shortly before the operation it was 100·2°.

Three days after admission, on March 17th, I found that the decidua * which I now exhibit, had been passed on the previous night. There was great trouble from constipation, and it was not easy to introduce an enema tube as the mass pressed on the rectum.† A long, shreddy, shaggy clot was passed on the 18th. The bowels were at length opened by aperients, and the patient fared better for a few days.

On the evening of March 28th, a clot as big as a walnut was passed, and a few hours later violent pains,

* My thanks are due to my colleague, Dr. Lockyer, for examining and mounting the deciduæ from these two cases.

† This symptom would favour the diagnosis of hæmatoma.

"like labour" as the patient described them, set in. At 6 a.m. on the 29th, I was called up and found the patient in a state of collapse with a very rapid, feeble pulse. The swelling was distinctly larger and much more tense. There could be no doubt that internal hæmorrhage was taking place.

From the first, ectopic gestation seemed very probable, and the discharge of a decidua on the 17th made the patient's condition yet more clear. There was no evidence of fresh hæmorrhage when the decidual membrane came away, so I thought that the hæmatocele as it seemed to be, would gradually disappear. Several large hæmatoceles in my own practice have become absorbed. When the acute symptoms set in, I concluded that there must be fresh intra-peritoneal hæmorrhage, and in order to arrest it I operated, with the assistance of Dr. Lockyer, Dr. Belfrage administering gas and ether.

The pelvis was elevated throughout the operation. I made a free incision and found that the hard mass was the uterus drawn high up on the anterior aspect of a convex swelling, together with a greatly distended right Fallopian tube. The left tube, also much dilated, ran down the left border of the swelling. The great omentum adhered firmly to the fundus and to the right tubal sac. A small collection of recent clot lay behind the omental adhesion in front of adherent small intestine and descending colon. These adhesions were detached.

I laid open the right tube. About four ounces of old, dry, brown clot were found in its canal and then a big dark swelling came into view, forming as it were the floor of the dilated tubal cavity. I cut into the thin membranous tissue consisting of organised clot which formed the wall of the swelling, and then a great mass of coagulum appeared, more recent than that which had filled the right tube. I removed no less than four pounds of this clot, which filled the whole pelvis.*

* No trace of a fœtus could be detected. The pregnancy had been interrupted at a very early stage.

The patient's condition at this stage was very serious, and as the precise source of the hæmorrhage could not be determined, I tied both ovarian vessels, turned down an anterior flap of peritoneum from the lower part of the uterus, secured the uterine vessels, and amputated the uterus through the upper part of the cervix. That organ then came away with both tubes and ovaries, and with the great dome of membrane which had capped the mass of clot. That displaced membrane consisted of the opened-up broad ligament and peritoneum which had once formed Douglas's pouch.

The pelvis was drained with iodoform gauze and the abdominal wound closed except at its lower angle.

Over one pint of saline fluid was injected under the breast during the operation, and a saline enema was administered. After the abdominal wound had been closed a pint and a half of saline fluid was injected into the left median basilic vein.

When the patient was put back to bed her condition was very unfavourable. At the end of three-quarters of an hour she seemed a little stronger, though there was no pulse at the wrist. Brandy and digitalis were given; enemata and hot water could not be retained. At noon the temperature had risen to 105·2° and there was a rigor. I observed marked facial spasms which lasted for several minutes. Half an hour later the pulse could be felt. By 6 p.m., after free administration of digitalis and brandy, the temperature had fallen to 103°; the pulse was 150, but distinct and regular. At 10 p.m. temperature 101·6°, pulse 138, and the patient took barley water. The absence of vomiting was remarkable.

Twenty-four hours after the operation, the patient seemed much stronger and flatus passed naturally. I removed the gauze, and little or no oozing followed; a rubber tube was left in the lower angle of the wound for a few days. The cavity was washed out with antiseptic solutions for about four weeks, some sloughy tissue coming away. The anæmia was relieved by suitable

treatment, and the patient left hospital with a sinus in the lower angle of the wound four inches deep. The general health was good.

I last saw the patient on November 2nd, 1903. She had gained flesh and was much less anæmic. On August 9th, she noticed a show of blood which lasted for two days; on October 13th, a much more copious discharge set in and lasted for four days.* A little pus discharged from the sinus, which was 2½ inches deep. The long cicatrix of the abdominal wound was firm. On vaginal examination the cervix was found to be quite movable; the fornices were free.

This case was clearly an example of hæmatoma caused by rupture of a tubal sac, between the layers of the corresponding broad ligament. The accident must have occurred about February 15th and the ovum was destroyed, else a posterior tubo-ligamentary pregnancy would have developed. The hæmorrhage continued until at length the whole pelvic peritoneum was heaved up. That part which had formed Douglas's pouch became the superior and posterior part of the capsule which covered the great mass of clot (Fig. 2). The uterus and appendages were raised up with the anterior layer of the broad ligament so as to constitute the anterior part of the capsule. The lower part of the clot, free in the pelvic connective tissue, lay not in Douglas's pouch, but in its site, and could be detected by touch as a convex mass behind the cervix.

On the night of March 28th, nearly six weeks after the rupture of the tube, the capsule leaked a little posteriorly to its superior limits at the point of adhesion to the omentum. On this occasion there was sharp pain, such as has been noted in intra-peritoneal hæmorrhage,

* It is very doubtful if any ovarian tissue could have been left as both ovaries were easily removed with the body of the uterus. In oöphorectomy for the cure of uterine fibroids it was quite otherwise. I have discussed this question in the Harveian Lectures (Lecture II, 'Lancet,' 1903, vol. i, p. 415).

but the patient's sufferings must have been largely due to the tension of the capsule of peritoneum, a necessary result of the renewed hæmorrhage.

Had a fœtus escaped through a rent in the capsule, instead of a clot, then granting that the patient and fœtus had survived, a tubo-abdominal pregnancy of the fourth class according to Taylor (*loc. cit.*, p. 58) would have developod. Earlier writers believed that most

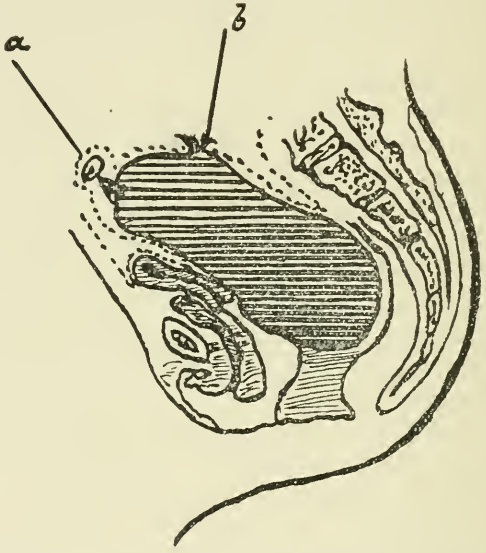

Fig. 2, Case 2.—The dotted line shows the pelvic peritoneum completely displaced upwards by the clot. (*a*) Dilated right Fallopian tube which had ruptured into the parametrium; (*b*) site of secondary rupture into peritoneal cavity.

abdominal pregnancies were established in that manner, which implied that abdominal was secondary to tubo-ligamentary pregnancy (*loc. cit.*, pp. 47, 48).

The cause of the renewed hæmorrhage in Case 2 was not clear. Most probably it was due to straining at stool. There were no solid motions in the intestinal canal at the time, but on the contrary, looseness of the bowels following free purgation by sulphate of magnesia,

which had greatly relieved the flatulence. In order to hasten the escape of flatus and liquid motion, patients often strain at stool.

The most prominent physical sign, after the presence of a tumour in the hypogastrium, was the convex mass behind the cervix. A similar kind of swelling is to be detected when there is a pelvic hæmatocele and the blood in Douglas's pouch has coagulated; a tubal sac in the same position also forms a convex mass behind the cervix.* But there was no Douglas's pouch in this case, a fact which was made clear at the operation. All collections of clot as well as all cysts and fibroids which burrow thoroughly into the posterior fold of the mesometrium must, if they continue to grow, displace that portion of the peritoneum which constitutes Douglas's pouch so that it will lie on the top and back of the clot or tumour. This displacement of the peritoneum is very plainly seen when a large fibroid of the broad ligament is exposed and enucleated from its serous investment. I have demonstrated at full length this displacement in the Harveian Lectures for 1902.†

Taylor‡ in treating of broad ligament hæmatoma, observes that in some cases "by burrowing in front of the rectum low down in (*sic*) the pouch of Douglas it may produce a well-defined tumour behind the uterus that closely simulates intra-peritoneal swelling of a

* Taylor rightly lays stress on the fact that a swelling behind the cervix in these cases may be the gravid tube and not a hæmatocele or hæmatoma. For his view of the relation of the gravid tube to the hæmatocele see *loc. cit.*, p. 113, par. 10. This heaving up of Douglas's pouch has recently been noted by Savariaud when operating upon a case of hydatid cyst burrowing in and beyond the broad ligament. "J'essaie en vain de luxer la tumeur hors du Douglas; *elle soulève le péritoine pelvien en s'en coiffant.*" (The term is most expressive, the clot in my case was *coiffé* by the pelvic peritoneum.) See Savariaud, "Kystes Hydatiques du Ligament large et du Grand Epiploon," 'Revue de Gynéc. et de Chir. Abdom.,' November—December, 1903, p. 986.

† Lecture I, 'Lancet,' vol. i, 1903, p. 350, section, "The Surgical Anatomy of the Broad and Ovarian Ligaments."

‡ *Loc. cit.*, p. 65.

distended and adherent tube." But a broad ligament hæmatoma cannot be *in* Douglas's pouch, as it is essentially an extra-peritoneal condition. Taylor illustrates the above remarks by a drawing from Hart and Carter's work,* on inspecting it that author's meaning at once becomes clear. The clot is represented *behind* the posterior layer of Douglas's pouch, being in the case illustrated insufficient in bulk to heave up the whole pouch in the manner which I have already endeavoured to explain. Thus the relations of one form of small hæmatoma are proved by Hart and Carter's section, whilst the relations of an unusually large hæmatoma were made evident by the condition of the affected parts which I detected when operating on Case 2.†

Thus these two cases indicated in the first place that hæmatoma is not so rare a result of interrupted extra-uterine pregnancy as is generally taught, and that it may be mistaken for hæmatocele. Hæmatoma is, however, decidedly less frequent than hæmatocele, in relation to ectopic gestation. For the tubal sac is more likely to discharge its contents through the ostium into the peritoneal cavity or to burst into that cavity than to rupture between the folds of the broad ligament. When the broad ligament is opened up in this manner experience has proved that, instead of a hæmatoma forming, the ovum not rarely continues to develop, constituting the tubo-ligamentary pregnancy, anterior or posterior, of Taylor. There remains a considerable minority of cases where the ovum is destroyed and a true hæmatoma develops and displaces the pelvic peritoneum upwards after the manner of a tubo-ligamentary sac.

* *Loc. cit.*, fig. 27, p. 66.

† See Taylor, *loc. cit.*, fig. 29, p. 68, where a broad ligament pregnancy has already begun to heave up Douglas's pouch. As that author justly observes (p. 69), this illustration is "exceedingly simple and intelligible." Lawson Tait's well-known "jelly-fish," convex above, concave below, represents an intermediate or average type of hæmatoma.

In such a case the lower part of the hæmatoma, bulging behind the cervix, may be mistaken for a hæmatocele occupying Douglas's pouch, though in reality that pouch no longer exists, its peritoneum lying above the hæmatoma.

Secondly, the hæmatoma of extra-uterine gestation, even when developed early, is not so innocuous as compared with hæmatocele, as certain authorities are inclined to believe. The peritoneal capsule may yield so that dangerous intra-peritoneal hæmorrhage ensues.

Thirdly, there can be no doubt of the truth of the prevalent theory that hæmatocele is a very frequent result of interrupted tubal gestation. At the same time, whilst the dangers of hæmatoma have been underrated, the perils of hæmatocele have been exaggerated, at least as regards the earlier stages of ectopic gestation. The hæmatocele often signifies that the issue of blood from a tubal mole has permanently ceased, nor is it certain that the same may not be said of many cases of early rupture of the tube.

In conclusion, we must admit that the importance of faithful clinical study of extra-uterine pregnancy from its earliest recognisable stages cannot be over-estimated. There is much that we can safely teach, yet there remains more that we must learn about ectopic gestation, above all as to the relation of prognosis to treatment.

Dr. Peter Horrocks said he agreed with those who thought that extra-uterine gestation was much commoner than was supposed, and that a great many cases got well without being diagnosed or treated. Moreover he had seen many cases that had recovered without operation. He related details of such a case seen by himself, Dr. Herman, and Dr. Galabin. On the other hand he related details of a case which was kept under observation for many weeks until it was considered safe to let her go home; as she was bidding good-bye to the other patients she was seized with pain and collapse and had to be operated on. Nevertheless it was his practice not to advise operation when the blood appeared to be encysted or clotted, and the patient was not in great pain, and when she had no signs of sepsis, and when she was within easy reach of efficient help. He had listened in vain for

any indication which would enable one to diagnose a hæmatoma such as the one described from an ordinary hæmatocele.

Dr. Cullingworth said he had listened to the paper with great interest, for the condition described in Mr. Doran's second case was rare, much rarer than Mr. Doran in his modesty had indicated. It was suggested in the paper that hæmatoma was probably not so rare a result of interrupted extra-uterine pregnancy as had been generally taught, but the only ground for this opinion appeared to be that a case had occurred in Mr. Doran's practice, and that he "suspected" that undiagnosed cases had occurred in the practice of others. That was surely not a very logical position to take up. From his (the speaker's) own experience (one in about seventy cases), and from what he had gathered from reading, he must still continue to regard pelvic hæmatoma as a rare complication of interrupted tubal pregnancy, and an extensive hæmatoma such as Mr. Doran had described as excessively rare. With regard to treatment, the cases on record were at present far too few to justify them in formulating any conclusions as to the dangers incurred, or any fixed rules as to the line of treatment to be adopted. Each case must be dealt with according to its own individual features. Mr. Doran's was an instance in point. He had operated, not because the condition was a hæmatoma, for he did not know it before operation, but because there was reason to believe that fresh hæmorrhages were taking place. In reference to the comparative dangers of intra-peritoneal and extra-peritoneal hæmorrhage, it was obvious, as Lawson Tait had long ago pointed out, that hæmorrhage into the peritoneal cavity, being a hæmorrhage into a practically unlimited space, was, *cæteris paribus*, bound to be more formidable because less likely to be spontaneously arrested than a hæmorrhage into connective tissue. But that exceptionally extensive pelvic hæmatomata *may* occur, and may call for prompt measures, is proved by the case cited in the paper. He gathered that Mr. Doran was unable to give them any help in diagnosing an extensive hæmatoma from a hæmatocele. Fortunately this was not a matter of much practical importance. The treatment of every case had to be decided on general principles. Notwithstanding these criticisms he was grateful to the author for his most valuable paper.

Mr. John W. Taylor, after acknowledging the kind references to himself and to his work in Mr. Doran's paper, said he was pleased to find that he was so much in agreement with Mr. Doran, in greater agreement, he thought, than Mr. Doran recognised. It is true that in one sentence in his book (which Mr. Doran quoted) he had said that a broad ligament hæmatoma due to tubal pregnancy might be absorbed and undergo a natural cure, but this was inserted rather in deference to popular teaching than as the result of personal observation. So far as

his own experience went the only recoveries without operation which he had himself observed were the seven or eight cases of peri-tubal hæmatocele, most of which were referred to in his book. Mr. Taylor had always held and taught that whereas hæmatoma due to other causes than tubal pregnancy was very generally easily absorbed, a broad ligament pregnancy and hæmatoma due to broad ligament pregnancy was specially dangerous. The example quoted in his book (on p. 69) was exceedingly similar to Mr. Doran's in its severity and clinical urgency, and on the next page the dangers of broad ligament pregnancy and hæmatoma resulting from this were contrasted unfavourably with those of tubo-abdominal pregnancy in the following terms: "In tubo-abdominal pregnancy, if the patient survive the fourth month and the dangers incidental to the extrusion of the fœtus from the tube, she is free from further dangerous complications until the term of pregnancy is near its completion. In the tubo-ligamentary, on the other hand, owing to the higher position of the placenta and its liability to detachment from the growth of the pregnancy, the patient is *never free from danger*, and although many cases of this kind go on to term, *secondary rupture and fatal hæmorrhage are by no means uncommon or impossible at almost any stage of the development.*" Nothing could be plainer than this, he hoped, in pointing out the danger of broad ligament hæmatoma and secondary rupture from first to last all through the case of a tubo-ligamentary pregnancy. What Mr. Taylor had originally said regarding the general danger of expectant treatment in tubal pregnancy and the advisability of operation was the result of personal observation and experience—an experience which had, on more than one occasion, been very similar to that recounted by Dr. Horrocks. This experience might possibly be affected to some extent by the exigencies of his hospital practice (the accommodation at the Women's Hospital being too limited to allow of patients coming in for rest), but on the whole he thought that his advice was sound. He had what he regarded as a wholesome horror of active placental tissue bottled up within the abdomen and having no channel of exit. In one respect Mr. Taylor differed altogether from Mr. Doran. Mr. Doran appeared to think that hæmatoma might be a rather common result of tubal pregnancy. Mr. Taylor believed that ligamentary invasion and hæmatoma was always a rather rare result, and had been accustomed to consider the proportion as roughly gauged by the ratio of the circumference of the tube to the chink or line of the ligamentary attachment. Dr. Cullingworth had spoken of encapsulation of the hæmatocele as preceding absorption. Mr. Taylor would like to point out that in some cases it prevented absorption, and a fully encapsulated hæmatocele might remain for many months within

the abdomen unchanged and a constant source of pain and danger.

Dr. Amand Routh related a case of hæmatoma of the broad ligament following tubal rupture, where the extravasated blood had stripped up the retro-uterine peritoneum, but did not cause the formation of a convex tumour as felt *per vaginam*, but rather a concave hardness like a half-collar. He had in that case found that the extravasated blood was extremely slow in being absorbed. He thought a distinction should be made between encysted and diffuse hæmatocele. If the hæmatocele was diffused bleeding was probably still going on, and if the severe pain felt in these cases was as high as the umbilicus, it was evidence of extensive hæmorrhage into the peritoneal cavity. Such a case needed prompt abdominal section. If the hæmatocele was encysted, operation was rarely called for, and when done should always be by a free incision *per vaginam* through Douglas's pouch, a gauze drain being left in the cavity. This operation of posterior colpotomy was only indicated where the hæmatocele became increasingly tense and bulged downwards into the vagina. Even if pyrexia occurred, operation was not called for if there was no evidence of increased tension as shown by vaginal bulging or by increase in size of abdominal tumour.

Dr. Blacker was much interested in the question of the rarity of a hæmatoma of the broad ligament. He had met with two examples of this condition. In the first case the abdomen was opened and the blood removed, the patient doing well, while in the second case, that of a patient with a typical history of extra-uterine gestation, admitted into the Great Northern Hospital, he had been able to confirm the disappearance of the tumour at a subsequent operation. At the first operation, June 13th, 1902, the left broad ligament was found to be distended to the size of a fœtal head by a tumour of softish consistence, evidently blood clot. On the surface of the tumour were a number of large veins, and in separating some adhesions one of these vessels was torn. As the tumour was considered to be an intra-ligamentary hæmatoma the abdomen was closed, the hæmorrhage, which was rather troublesome, being finally arrested with an iodoform gauze plug. The patient made a good recovery, and when she left the hospital the tumour was a little smaller. In February, 1904, she returned with a ventral hernia, no doubt due to the use of the gauze plug at the first operation. The abdomen was re-opened for the purpose of dealing with the hernia, and the tumour on the left side was found to have entirely disappeared. Except for some adhesions the left broad ligament was normal. The case was an interesting proof of the fact that a hæmatoma of the broad ligament could disappear entirely, leaving behind practically no trace of its existence. He thought that it was necessary to distinguish very carefully

between the results to be obtained by expectant treatment in cases of hæmatoma of the broad ligament such as Mr. Doran was referring to, and cases of broad ligament gestation in which the fœtus was still alive; two entirely different classes of cases and requiring quite different treatment in most instances.

Mr. Alban Doran, in reply to Dr. Horrocks, believed that the diagnosis of a large hæmatoma from a large hæmatocele, and the determination of the side on which either originally developed, were not always possible, as the uterus tended to come in front of the mass, just as it lay in front of a big tumour of either broad ligament. The nature and original seat of the big mass which displaced the uterus upwards, forwards, and towards the middle line were in this respect immaterial. In regard to Dr. Cullingworth's remarks Mr. Doran maintained that his two cases showed that it was an error to suppose that a convex mass behind the cervix was necessarily in Douglas's pouch. The undoubted rarity of hæmatoma and the admitted frequency of Taylor's tubo-intraligamentary pregnancy implied very clearly that the ovum, when it was forced through a rupture in the tube into the space between the layers of the broad ligament, usually survived and continued to develop. Professor Taylor dwelt on the manifest dangers of intra-ligamentary pregnancy in its later stages, but Mr. Doran confined himself in his paper to the accidents of early tubal pregnancy. Dr. Amand Routh spoke of encysted and diffused hæmatocele. In Case 1 in this paper the blood was very possibly encysted through adhesions which cut off the pelvic peritoneum from the general peritoneal cavity. But coagulability was an important factor in respect to true hæmatocele. Mr. Doran had found a clot like a tennis ball loose in the pelvic peritoneum and quite unencysted, that is to say, there had been diffuse hæmatocele, but strong coagulability had stopped the hæmorrhage and saved the patient.

JUNE 1st, 1904.

Edward Malins, M.D., President, in the Chair.

Present—47 Fellows and 8 visitors.

R. Drummond Maxwell, M.B., was admitted a Fellow.

The following candidates were proposed for election: Mary H. Frances Ivens, M.B., M.S.Lond.; James Cole Marshall, M.B.Lond., F.R.C.S.Eng.; Norman Blake Odgers, M.B., B.Ch.Oxon., F.R.C.S.Eng.; Edward Colston Williams, M.B., B.S.Lond.

PRIMARY CARCINOMA OF BOTH OVARIES.

Shown by Dr. Cuthbert Lockyer.

I am indebted to Dr. W. J. Maurice for his kind permission to show this case, and also for supplying me with the clinical details.

The patient was aged 47, single, no children. Menstruation was regular and normal until February, 1904, when it ceased. The patient had never suffered from leucorrhœa; she had suffered for some years from loose kidneys, and Dr. Maurice had examined the abdomen in August, 1903, but detected no pelvic tumour. As the

patient had always been extremely thin a tumour of any considerable size would have been noticed.

Two weeks after menstruation ceased the patient discovered that she had a tumour. She was then abroad, but came home at once, and Dr. Maurice, on March 30th, 1904, removed the two growths now exhibited. There was considerable ascites, which was not blood-stained. The right tumour occupied the pelvis, the left lay in the abdomen. There were no adhesions. Each tumour had a broad short pedicle. No sign of malignant disease was discovered in any other part of the body.

Recurrence occurred within six weeks of the operation. The abdomen was reopened for intestinal obstruction, and enterostomy performed on May 24th. The intestines were studded with tubercles of new growth, and were quite adherent to the anterior abdominal wall. Ascites was again present, the fluid was not blood-stained. The present condition is one of temporary relief, but emaciation is rapidly proceeding.

The left solid ovarian tumour measures 5 by 4 inches. It is oval in shape and flattened from before back. Its long diameter is vertical. The pedicle consisting of the mesosalpinx has been cut quite short; it measures $1\frac{3}{4}$ inches in width, and still attached to its outer portion is the extremity of the left Fallopian tube, which is normal in appearance. The pedicle and tube lie in a sulcus on the anterior aspect of the tumour at the junction of the upper with the middle third; the rest of the anterior surface is rendered irregular by deep sulci and broad furrows, which give the growth a nodular appearance. The posterior surface of the tumour is smooth and flattened. On section the growth presents a greyish yellow colour, and shows rounded masses of smooth material held together by strands of connective tissue. One small cyst-like space was seen measuring 1 by $\frac{3}{4}$ inches.

Microscopically, long columns and masses of glandular epithelium, mostly of spheroidal shape, are seen running in clefts and occupying alveolar spaces within dense

fibrous tissue. The latter varies greatly in amount in different parts of the section; in places it is reduced to a minimum, the cells being almost devoid of supporting stroma. Elsewhere it is very dense, but even here the thick coarse trabeculæ are invaded by the gland elements, the latter lying in lymphatics and also in the thick-walled blood-vessels (!), which lie in the dense fibrous matrix. The individual cells are for the most part much altered by degeneration; they present as swollen spheres with a very reticular protoplasm; many contain vacuoles. These swollen cells may be seen fused together, forming irregular protoplasmic masses with two, three, five, or more nuclei, whilst some of the single cells contain two large distinct nuclei. The nuclei are large, and for the most part oval in shape; they show a finely granular protoplasm and various karyokinetic figures.

The right-sided ovarian growth measures 5 by 4 by 3 inches. Its shape is irregularly ovoid, with its long axis running transversely. The anterior surface is puckered, deep fissures dividing it into lobes. Running transversely across this surface is a deep sulcus in which lie the meso-salpinx and right Fallopian tube; the latter is somewhat thickened but otherwise normal, being quite free from adhesions and signs of peritonitis. The pedicle is three inches in width and is very thick and vascular. The posterior surface is even more nodular and tuberous than the anterior. Many small projecting bosses are here seen, but they present no roughness, no adhesions.

On section, the solid tissue has a greyish-yellow colour; there is no indication of division into lobes of smooth growth such as was seen in the tumour on the left side. The entire surface is *uniformly* smooth and putty-like. No cysts are seen.

Under the microscope the general characters of the tumour are the same as that on the opposite side, but the degeneration of cells is more marked. In some of the degenerated swollen cells the nuclei have entirely disappeared, in others the nucleus is reduced to a thin

crescent of deeply staining protoplasm on the periphery of the cell. No loose chromatin granules can be seen, nor are any broken down individual cells to be found, the final stage of the degeneration being a fusion of the bubble-like denucleated cells to form a complex reticular myxomatous mass, in which not a trace of cell-formation is left. The relation of gland elements to stroma is different to that seen in the left-sided tumour. Here small clusters of cells lie quite separate and distinct in a wide field of loose œdematous fibrous tissue. The discrete patches of tightly packed gland tissue present the picture so familiar in adenoma mammæ.

To the right Fallopian tube was attached a small cystic body one inch from the abdominal ostium. A microscopical section through the tube and cyst proves the latter to be a tiny accessory hydrosalpinx. The tube wall itself, although its peritoneal coat is everywhere quite normal, is found to be infiltrated with cancerous deposit. The cancer-cells are arranged in oval clusters within the principal lymphatics of each fimbria and within the perivascular lymphatic channels accompanying the thick-walled vessels lying in the fibro-muscular wall. The malignant invasion has extended from the ovary through the mesosalpinx into the tube wall, and from thence through the central cortex of the fimbriæ up to their columnar-epithelial covering on the one hand, and also through the fibro-muscular wall of the tube as far as the peritoneal coat on the other hand. There are no free cancer cells in the lumen of the tube, and no implantation of cancer cells on the external peritoneal coat. The naked-eye appearances of the tube gave rise to no suspicion that it was the seat of invasion, and I should probably not have examined it microscopically but for wishing to investigate the nature of the small cyst on its upper surface. Whilst there is nothing unusual in the spread of glandular carcinoma along efferent lymphatics wherever the growth may be situated, an anatomical demonstration of this ordinary pathological process in this particular situation—

where the ovary is the primary seat of the lesion and the tube has become secondarily involved—has never, so far as my memory serves me, been so clearly demonstrated. The condition of the tube raises the important question as to whether the uterus itself might not be likewise involved in secondary growth, and if this can be shown to be the case, the correct treatment would involve not only the removal of tubes and ovaries, but also total abdominal hysterectomy. There would appear to be three distinct ways by which the tubes may become the seat of carcinoma secondarily to the ovary: (1) by implantation of papillomatous nodules on its peritoneal coat; (2) by the entrance of ascitic fluid, carrying cancer cells, through the abdominal ostium of the tube, followed by implantation of these cells on the surface of the fimbria; (3) by continuity of tissue, the cells travelling along the lymphatic channels accompanying the large blood-vessels in the hilum of the ovary and in the mesosalpinx which join up with the vessels entering the tube at its "uncovered" surface.

The section placed under the microscope shows a portion of mesosalpinx with the tube attached thereto, and the cancer cells can be seen to track along the lymph-channels in the connective tissue, and to enter the tube wall, where they have both the centripetal and centrifugal distribution already described.

Dr. W. J. Maurice stated that the patient was a single woman, aged 47. She had suffered for some years from loose kidneys, and her abdomen had been examined by him in August, 1903, when, as she was extremely thin, any considerable tumour would have been detected. She had had no pelvic symptoms, and there had been at no stage any vaginal discharge. In February, 1904, menstruation, which had always been regular and normal, had ceased, and about the same time she herself had discovered a tumour. She was seen on March 28th, and was found to have a solid tumour in the lower abdomen freely movable, with ascites. Ovarian tumour was diagnosed, probably malignant. Operation March 30th. There was much ascitic fluid, not blood-stained. The right ovary occupied the pelvis; the left lay in front of it and formed the tumour which had been felt and seen. There were no adhesions and no evidence of

growth elsewhere. The pedicles were broad and very short; otherwise removal was perfectly easy. Recovery was slow, but uneventful. Recurrence had, however, taken place in less than six weeks, and on May 24th Dr. Maurice had had to operate for intestinal obstruction. Ascitic fluid, not blood-stained, was again present; the small intestine was extensively adherent to the anterior abdominal wall; the pelvis was full of growth, especially about the right broad ligament; the intestines and parietal peritoneum were everywhere covered with small warty growths. Enterostomy was performed and had given great relief. Since the last operation emaciation had progressed very rapidly; the discharge, which had at first been fæcal, now consisted of partially digested food, and probably the opening was somewhat high up, which would partly account for the loss of flesh, but clinically the most striking feature of the case had been the very rapid growth of the original tumour and the still more rapid recurrence. Removal of the uterus with the appendages, as suggested by Dr. Lockyer, might perhaps be more satisfactory in any future case of the kind, but in this instance the result would probably have been the same.

Miss Thorne described a case of what she believed to be primary carcinoma of the ovary in a patient aged forty-six. The onset was unusually acute, the woman stating that she had felt sudden severe pain in the left side while doing heavy washing. The left ovary was found to be enlarged and tender; the right ovary was normal. The left ovary increased rapidly in size, and an exploratory laparotomy was performed, when the left ovary was found to consist of a mass partly solid and partly cystic and densely adherent to the surrounding parts. There was no free fluid in the abdomen or pelvis. On microscopic examination the left ovary showed typical carcinomatous growth. The patient died four months later. At the *post-mortem* examination made at the cancer wing, Middlesex Hospital, it was found that in addition to the large carcinoma of the left ovary there was a deposit in the right ovary. The ileum was adherent to the primary growth and was ulcerated through. There were secondary nodules in the liver.

CANCER OF THE BODY OF THE UTERUS SIMULATING FIBROID IN A WOMAN AGED THIRTY-SIX.

(With Plate VII.)

Shown by Dr. Herbert Spencer.

The points of interest in the case were the occurrence of cancer in the body of a uterus containing fibroids in a patient aged thirty-six, the slow growth of the tumour, and the freedom of the patient from recurrence six and a quarter years after the operation of combined vaginal and abdominal hysterectomy.

The specimen is a uterus measuring $5\frac{3}{4}$ in. by $4\frac{1}{2}$ in. by 3 in., and weighing $14\frac{1}{2}$ oz. in the fresh state. There is a subperitoneal fibroid of the size of a marble at the fundus and an interstitial fibroid as big as a pea just above the internal os (see Plate VII).

The uterus is distended by a soft brittle growth of the size of a small orange, which has infiltrated the muscular wall, in one place to within $\frac{1}{6}$ in. of the peritoneum. The substance of this growth has been broken into by the curette. The lower surface of the growth is fairly smooth; the cervical canal is filled with blood-stained mucus. The microscope shows the growth to consist of closely set narrow columns of epithelial cells; in some of these columns a lumen is apparent, but most of the columns appear to be solid; the columns are separated by strands of connective tissue in which fine capillaries can be made out; bands of muscular tissue also separate the columns where the growth is extending into the muscular wall. There is extensive infiltration with small round cells both in the connective-tissue stroma and in the muscular wall in advance of the extending growth. It is a glandular carcinoma of the body of a somewhat unusual type. The small sub-

peritoneal tumour is a fibro-myoma and contains numerous small vessels but no glands.

The history of the case is as follows:

A. D—, aged 36, was admitted to University College Hospital on October 15th, 1896, complaining of pain in the back, in the left side of the abdomen, left leg, and left hip, of discharge (slightly coloured red) and of bearing-down. These symptoms had been present for ten months.

Menstruation began at 16 and had been regular even during the present illness. There was no family history of cancer and the patient appeared fairly healthy.

On October 27th, 1896, under an anæsthetic, the uterus was found to be a good deal enlarged and hard, as if it contained a fibroid. The sound passed for four inches. A little nodule on the top of the uterus appeared to be a subperitoneal fibroid. The uterus was curetted and a considerable quantity of "endometrium" was removed and tincture of iodine applied. The appearance of the scrapings under the microscope did not suggest malignant disease.*

After the curetting the coloured discharge diminished.

On November 19th, 1896, the sound passed for $3\frac{1}{4}$ inches. After leaving the hospital the patient was fairly well, the uterus remaining large. On March 25th, 1897, it was noted to be three times its normal size.

On February 2nd, 1898, the patient was readmitted to the hospital for copious watery discharge, which had been present for several months; she had lost flesh and had pains in the back.

The uterus was now of the size of the uterus at the third month of pregnancy; the sound passed 5 inches. I regarded it as a case of submucous fibroid and dilated the cervix with a view of removing it. The curette, however, removed a large piece of soft brittle growth, which was evidently malignant. I therefore on February

* This may have been due to a piece of the endometrium (and not growth) having been removed by the curette.

DESCRIPTION OF PLATE VII,

Illustrating Dr. Herbert Spencer's specimen of Cancer of the Body of the Uterus simulating Fibroid in a woman aged 36.

The drawing shows a sagittal section of the uterus (natural size). A subperitoneal fibro-myoma (as shown by the microscope), of the size of a marble, is seen at the fundus, and an intra-mural one, of the size of a pea, above the internal os. The uterus is distended by a greyish-yellow growth, of the size of a small orange, invading the muscular wall. The microscope shows this growth to be a glandular carcinoma (see pp. 235, 265).

Illustrating Dr. HERBERT SPENCER'S case of Cancer of the Body of the Uterus simulating Fibroid in a woman aged 36.

Bale & Danielsson, Ltd.

28th, 1898, removed the uterus by the abdomen, after separating the cervix from the vagina, closing the cervix by suture and leaving a pair of forceps attached to the front and another to the back of the supra-vaginal cervix to act as guides. The peritoneum was not closed (this was a mistake in technique) and a piece of gauze was passed through the hole in the peritoneum into the vagina. One ovary was left behind. The patient made a slow recovery owing to an attack of cystitis and thrombosis of the veins of the left leg.

The patient was again admitted to the hospital on October 14th, 1898, suffering from intestinal obstruction, probably due to adhesion of a coil of intestine in the pelvis, though the fact was not definitely ascertained. The distended bowel was opened next day by my colleague, Mr. Raymond Johnson. She recovered well, but still has a very small fistula through which a little liquid fæces escapes at times; the main part of the fæces passes through the anus. The fistula causes very little inconvenience and it has been decided not to close it.

I examined her on October 20th, 1903. She was in very good health. The vagina admitted a speculum $1\frac{1}{16}$ in. in diameter; the interior wall measured $2\frac{7}{8}$ in. in length, the posterior wall $4\frac{1}{8}$ in. in length. There was no difficulty in having connection and only occasionally pain. Sexual gratification occurred.

I examined the patient recently and heard from her by letter on June 1st, 1904, six and a quarter years after the hysterectomy. She is well and free from recurrence. This is the first case in which I removed the cancerous uterus by the abdomen.

Dr. F. E. Taylor thought that although there was no doubt as to the carcinomatous nature of the growth, yet it certainly differed in many ways from the appearances usually presented by a specimen of ordinary carcinoma of the body of the uterus. He asked if Dr. Spencer had considered the possibility of it being a case of carcinoma originating in a diffuse adeno-myoma of the body of the uterus, the glandular elements of which had undergone an atypical proliferation, and so become carcinomatous, as in

the cases described by Cullen and others. He thought that some evidence could be adduced in support of this view from a consideration of the three following facts. In the first place, Dr. Spencer had told us that the microscopical examination of scrapings removed from the uterus by a previous curettage had failed to show any evidences of carcinoma, which showed that the endometrium was not the source of the growth. Secondly, the history of a growth of six* years' duration, which had been diagnosed as a fibro-myoma in its earlier stages and had only been considered to be malignant disease in its later stages, was a very significant fact, being just the history that would be expected in a case of carcinomatous transformation of an adeno-myoma. Thirdly, the distribution, extent, and appearance of the growth, as shown in the specimen handed round, would all tally with this view of the case. He therefore proposed that the specimen be submitted to the Pathological Committee for further investigation.

Dr. Spencer, in reply, said he considered in ordinary cases of abdominal hysterectomy it was a fault in technique not to close the peritoneum. He did not think the tumour was malignant growth arising from an adeno-myoma, as its structure was quite different from that of the two adeno-myomata he had met with and of those described by v. Recklinghausen, Cullen, and others. Such an origin, however, was not impossible. The growth was a carcinoma of glandular origin.

(For report of the Pathology Committee, see page 265.)

PREGNANCY IN A UTERUS WITH FIBROIDS: PANHYSTERECTOMY DURING LABOUR IN THE SEVENTH MONTH.

By J. Bland-Sutton.

In March, 1904, Dr. Beer placed under my care in the Chelsea Hospital for Women Mrs. F—, aged 33, on account of an abdominal tumour complicated with pregnancy.

The patient had been married a few months, and had

* The symptoms were of *two* years' duration; the growth was known to have been present for one year and four months.—Ed.

ceased to menstruate since October 27th, 1903. She considered herself to be pregnant, but her peace of mind was disturbed by a rounded tumour as big as a man's fist, which had become markedly prominent in the neighbourhood of the umbilicus. Examination satisfied me that this lump was a fibroid in the anterior wall of a gravid uterus, but the pelvis also contained a large rounded elastic swelling, and as the cervix uteri was flattened against the pubes, it caused some difficulty to determine whether the globular body in the true pelvis represented the fundus of a retroverted gravid uterus, or another fibroid incarcerated by the uterus. As there were no symptoms of urgency or interference with the urinary organs, it seemed judicious to keep the patient under observation, especially as she was anxious to have a living child. She reported herself at intervals, and the uterus rose in the abdomen, but the pelvic mass remained unaltered. On May 9th the patient came to the hospital in great pain and distress; on examination she was found to be in labour, with the arm of the fœtus protruding through the mouth of the womb. Dr. Eden kindly saw the patient and decided that an operation was urgently indicated, as the pelvic tumour absolutely obstructed the transit of the fœtus, and that it was dead. After the patient's abdomen had been rendered as antiseptic as the urgency of the case allowed, I exposed the uterus through a free abdominal incision and performed panhysterectomy, removing the uterus and its neck with the tumours, fœtus, placenta, ovaries, and tubes intact.

The early stages of the operation were conducted in sterilised rubber gloves until the peritoneum was sutured over the vaginal opening. I then discarded the gloves, as they had probably become contaminated by contact with the vagina, and then carefully washed out the pelvis with sterilised water and completed the operation without gloves.

In the course of convalescence an abscess formed at the pelvic end of the incision, the result probably of

a staphylococcus infection in consequence of the hurried preparation of the skin.

The operation offered no difficulty and occupied about three quarters of an hour. During the enucleation of the

cervix I was a little puzzled to determine where the cervix ended and the vagina began, as the parts were soft and œdematous, but a subsequent examination of the parts showed that the whole cervix was removed. The specimen, as displayed in the drawing, shows the uterus divided in a sagittal direction; an interstitial fibroid occupies its anterior wall near the fundus; it is of the colour of mahogany in consequence of red degeneration, which is such a common change in fibroids of the body of the uterus when complicated with pregnancy. The larger fibroid grew from the posterior aspect of the cervix, and almost completely occupied the cavity of the true pelvis. This tumour was soft as if degenerating, and resembled in colour the peculiar yellowish appearance of wet washleather. It would be tedious to attempt a description of the extraordinarily contorted condition of the fœtus, but this is faithfully displayed, as well as the œdema of the presenting-arm, in Mr. Charles Berjeau's admirable drawing.

I have on many occasions performed supra-vaginal hysterectomy for fibroids complicating pregnancy, and find it is an easier task than removing an unimpregnated uterus; but this is the first occasion on which I have performed panhysterectomy upon a patient in labour.

Dr. Handfield-Jones asked Mr. Bland-Sutton how long the patient had been in labour before the operation was performed. Though the tumour was situated in the lower uterine segment, it was noteworthy how markedly fibroid growths were drawn up and elongated, so as to render the passage of an infant possible, even in the most unpromising cases. He narrated the case of a patient, who had recently been under his care, where delivery had been effected after version, though the patient had a fibroid in the cervical area, and delivery had seemed at first absolutely impossible.

Dr. Eden said that when asked to see Mr. Bland-Sutton's patient he found the following condition: On abdominal examination the uterus appeared to be firmly retracted; no part of the body of the fœtus could be felt distinctly, nor was the fœtal heart audible. The ring of Bandl was not found, but the outline of the uterus was distorted by the fibroid tumour and its

recognition was hardly to be expected even if it had been present. On vaginal examination an arm was found, prolapsed, with the hand outside the vulva. The limb could be followed upwards behind the symphysis pubis, but the os externum was out of reach and could not be felt. Behind the posterior vaginal wall was a large, hard, absolutely fixed swelling, which appeared to occupy the greater part of the pelvic cavity. Version was clearly impracticable, and he judged that there was considerable risk of spontaneous rupture of the uterus if the labour was allowed to continue. This opinion was now confirmed by the marked thinning of the anterior part of the lower uterine segment shown in the specimen. In his opinion the case was clearly one in which delivery per abdomen was indicated.

PAROVARIAN CYST WITH TWISTED PEDICLE.

Shown by Dr. Comyns Berkeley.

A CASE OF PRIMARY HYDATID DISEASE (ECHINOCOCCUS) OF THE FALLOPIAN TUBE.

By T. W. Eden, M.D.,
ASSISTANT OBSTETRIC PHYSICIAN TO CHARING CROSS HOSPITAL.

(Received January 10th, 1904.)

(*Abstract.*)

The author records the case of a woman of forty years of age who had been married for thirteen years, had never been pregnant, and presented herself at the Chelsea Hospital for Women in July, 1903, complaining of pain in the back and left side. On examination a small pelvic tumour was found in the pouch of Douglas, which from its position and characters was thought to be a dermoid cyst of the right ovary. Operation was performed on September 10th, 1903, when the tumour was found to be incorporated with the upper border of the densely adherent right Fallopian tube, and to be filled with detached hydatid vesicles. The ovary was quite separate, and unaffected except by adhesions. The tube and ovary of the left side were adherent, but otherwise unaffected. There was no trace of hydatid disease elsewhere. The patient made a good recovery. The naked-eye and microscopic characters of the specimen are then described.

After examination of the literature the author believes that only one other case of primary hydatid disease of the Fallopian tube is on record, viz. that described by Doléris in 1896. With regard to the ovary, he believes that only one case of primary hydatid disease of this organ has been recorded, viz. that described by Péan in 1895. Pelvic hydatids usually begin in the peritoneum or connective tissue.

The female pelvic organs are but rarely the localities chosen for the deposition and development of the ova of

the *Tænia echinococcus*. They not uncommonly become involved in extensive hydatid growths, developing primarily in the liver or other abdominal organs, but they are rarely the localities primarily affected. The ovary and Fallopian tube are among the last sites in the whole body selected by those parasites, and it is on account of the extreme rarity of the condition that the following case is recorded.

Mrs. E—, aged 40, was admitted to the Chelsea Hospital for Women under my care on September 4th, 1903. She had been seen by me in the out-patient department in the previous July, where she came complaining of pain in the small of the back and in the left side, with troublesome palpitations of many years' standing. Her menstrual periods were regular and the loss moderate in amount, but she habitually suffered severe pain during the whole time in the hypogastric and sacral regions. She had no vaginal discharge, and was in good general health. Although married for thirteen years, she had never been pregnant.

On local examination (July, 1903) a small, tense cyst was found in the pouch of Douglas, firmly adherent to surrounding structures, and connected by an easily palpated pedicle with the right cornu of the uterus. On rectal examination the posterior wall was felt to be of almost stony hardness, and the case was diagnosed as being probably a dermoid cyst of the right ovary. Its removal was advised, but as the hospital was about to be closed for the annual cleaning, the operation was postponed until September.

On the patient's admission on September 4th her condition was practically unchanged in all respects. The operation was performed on September 10th. After opening the abdomen the swelling was easily defined, as no adhesions had formed except in its immediate neighbourhood. The swelling itself was densely adherent, and on exposing it by means of retractors, its wall was seen to

be of a dull yellow colour and of very dense appearance, not unlike an ovarian dermoid with cartilaginous walls. Much time and care were expended in separating the unusually strong and resistant adhesions, some of which required ligature. The tumour ruptured in the manipulations, revealing its true nature, for large numbers of loose, thin-walled, cystic structures escaped, easily recognisable as hydatid vesicles, accompanied by loose membrane and a scanty amount of thin fluid. The tumour was emptied as far as possible and the loose vesicles and membrane carefully removed from the peritoneal cavity. The remaining adhesions were then separated, a good pedicle obtained, and treated in the usual manner by transfixion and ligature. There was a good deal of oozing from the tumour-bed, but this was all controlled by pressure with hot sponges. The structures removed were the appendages of the right side; the left appendages were involved in adhesions apparently as dense as those surrounding the tumour. There was, however, no enlargement either of the tube or ovary, and as separation of the adhesions would in all probability have involved the removal of the appendages it was considered better to leave them undisturbed. No other swelling could be felt in the abdominal cavity, and the remaining viscera appeared to be quite free from hydatid disease, so far as could be determined by palpation. No drain was required, and the abdomen was closed in the usual manner, in three layers.*

Up to this time the tumour was believed to be ovarian, but careful examination by the pathologist to the hospital (Dr. Taylor) demonstrated its tubal character.

Description of the specimen.—The specimen consists of the right uterine appendages including the ovary, the Fallopian tube, and the mesosalpinx. The ovary is of normal size, its surface being rough and showing tags of

* Convalescence was a little delayed by the formation of a small hæmatoma in the abdominal wound, but the patient left the hospital well in a month.

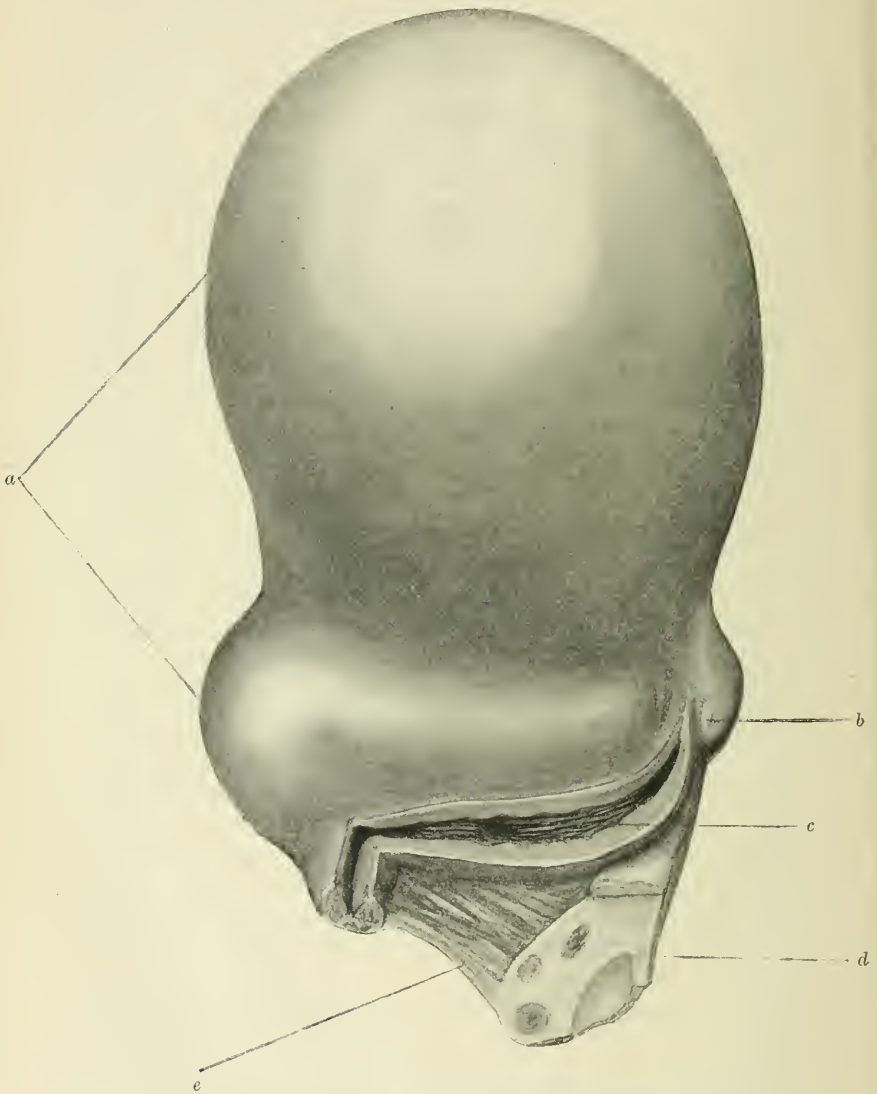

Illustrating Dr. Eden's Case of Hydatid Cyst of the Fallopian Tube. *a*, Cyst. *b*, Ostium abdominale. *c*, Lumen of tube. *d*, Ovary. *e*, Mesosalpinx.

torn adhesions. On dividing the ovary it is seen to contain two small corpora lutea in the stage of retrogression, one abortive follicle containing blood, and one small cyst lined with a smooth membrane. The organ was obviously functionally active when removed. The mesosalpinx measures one inch in greatest vertical diameter; it is a little thickened, and its peritoneal surfaces are roughened from adhesions. The usual transparency of this portion of the broad ligament is lost, so that the condition of the parovarium cannot be made out by inspection.

The Fallopian tube measures four inches from the divided end to the abdominal ostium. The inner third is not much altered in naked-eye characters. With the upper border of the outer two thirds is closely incorporated a cyst of considerable size; this cavity was at first regarded as the dilated lumen of the tube, and the hydatids were considered to occupy that portion of the canal of the tube. In fact, this was the description of the specimen first sent in to the Society in this paper, but further examination proved it to be erroneous, and by the courtesy of the senior Hon. Sec. I have been allowed to correct the error. As will be seen from the drawing, the tubal canal is intact, and has been laid open, running apparently in the lower wall of the cyst. There was no communication whatever between the tubal canal and the cavity of the cyst, and it was owing to the failure to demonstrate this connection that the error in description was discovered. The union of the cyst wall with the upper wall of the tube is a firm organic union, and not the result of adhesions.

The abdominal ostium of the tube is sealed, but its position is clearly indicated in the specimen by a dimple and a small tag which may represent a single atrophied fimbria. The surface of all parts of the specimen is roughened and shows many tags of adhesions.

The cyst, which is oval in shape, rises steeply from the upper wall of the tube, and is firmly incorporated with it from the junction of the inner and middle thirds

nearly to the abdominal ostium. It measures $4\frac{1}{2}$ in. in vertical, 3 in. in transverse, and $2\frac{1}{4}$ in. in antero-posterior diameter. The wall varies in thickness from $\frac{1}{16}$ to $\frac{1}{4}$ of an inch, being on an average about $\frac{1}{8}$ of an inch. It contains but a single cavity; the inner wall is smooth and polished, the hydatid membrane having been completely detached.

Microscopic details.—Examination of the fluid obtained from the hydatid vesicles shows large numbers of typical brood-capsules and free hooklets. The detached membrane is lamellar in character, and represents the outer cuticular layer of the cyst. Sections of the wall of the tube taken from the dilated portion show that little of the normal structure remains, the greater part consisting of stratified layers of hydatid membrane showing the characteristic pectorate markings. The diagnosis of the nature of the tubal cyst is thus fully established; but its mode of origin is not so simple and presents some points of interest. Two points are fairly clear: Firstly, the hydatid ova were not deposited in the lumen of the tube, nor has the resulting cyst involved the lumen in its further development. Secondly, the union of the cysts with the wall of the tube is so intimate that it cannot be possible that free peritoneal hydatids have become adherent to the tube and have developed in that position. Further, there is no evidence of any other abdominal organ having been infested with the parasite. This point is worth consideration because, in the view of Lawson Tait, pelvic hydatids always arise secondarily to rupture and escape of hydatid vessels from another abdominal organ—usually the liver. The most probable explanation appears to be that the ova were deposited in the tissues of the upper wall of the tube, and their development in that position was sufficiently slow and gradual to avoid rupture either into the peritoneal cavity or the tubal canal. Inasmuch as the subperitoneal cellular tissue is the favourite pelvic location for hydatids, it seems further reasonable to surmise that in this case ova were deposited beneath the

peritoneal covering of the tube, and that they continued to develop in that position. From the long duration of the patient's symptoms and the unusual density of the adhesions met with at the operation, it is clear that the disease was of long standing—probably of many years—and the microscopic recognition of a peritoneal investment after so long an interval is, of course, impossible.

Regarding the source of the parasitic infestment, I can give no information. The patient had lived all her life in London or its immediate neighbourhood, and she had never kept a dog or cat, or any other pet animal, in her life. The ova must have been ingested with some article of food.

The first writer who endeavoured to collect information about pelvic hydatids appears to have been Villard, who published in the 'Annales de Gynécologie' for 1878 a paper entitled "Considérations Cliniques sur les Kystes Hydatidiques du petit Bassin chez la Femme." In this paper he collected twelve cases published since 1817, and added a personal observation of his own. Following him Freund,* in 1885, published eighteen fresh cases observed by himself, and to him is due the credit of laying the foundation of our knowledge of the subject. Since Villard's paper was published numerous additional cases have been recorded, and these have been collected by Doléris,† who, in 1896, brought up the total to seventy cases, including those previously recorded. Pelvic hydatids, as a complication of pregnancy and labour, have recently been discussed by a Hungarian writer, Franta,‡ in an important monograph of 250 pages. But it may be said that these researches throw no light upon the conditions which determine the locality which the hydatid ova select for their development.

Pelvic hydatids appear to find their primary lodgment in the great majority of cases beneath the peritoneum in

* 'Gynäkologische Klinik,' 1885, p. 302.

† 'La Gynécologie,' 1896, p. 97.

‡ Boubele, Mëchozilové Teilotenstoi za Porodu, a v. Sestinedeli.

the pelvic cellular tissue of the pouch of Douglas. Here they burrow in all directions, and come into relation with the uterus, bladder, rectum, ovary, and Fallopian tubes. No case has yet been recorded of the primary lodgment of hydatids in the uterine cavity or the uterine walls.* Several cases are known where hydatids have invaded the hollow pelvic viscera by perforation of their walls, but that is obviously a different condition, and must not be confused with cases of primary lodgment.

In the Fallopian tube and ovary, primary hydatid disease is extremely rare, and I have thought that it might be useful to look through the literature with the object of finding such cases if they existed, and of examining the evidence in favour of their primary origin in these organs.

Text-books, I was not surprised to find, contradict one another consistently upon the subject. In the last edition of his text-book on 'Tumours,' Mr. Bland-Sutton says that no case of primary hydatidiform disease of the ovary has been recorded, and only one case in the Fallopian tube, in the case of Doléris. Veit's 'Handbuch der Gynäkologie' states, on the other hand, that a case of primary echinococcus of the ovary was recorded by Péan in 1895. Martin, in his monograph 'Die Krankheiten der Eileiter,' published in 1895, makes no mention of echinococcus of the tube. Griffith, in the 'System of Gynæcology' edited by Allbutt and Playfair, says there is "grave doubt whether any of the cases so recorded are really hydatids of the ovary."

My search through the literature has convinced me that there was on record, previous to my own, one case of undoubted primary hydatid disease of the ovary, and one

* Since this paper was written an Inaugural Dissertation of the University of Amsterdam by J. de Vries has appeared on the subject of "Echinococcus of the Uterus." The author records an original observation of his own, and claims to have found in the literature seven other cases of apparently primary uterine hydatids. The original paper I was unable to read, and the only abstract which I have found was very cursory ('Monats. für Geburts. und Gynäkol.,' March, 1904), so that I am unable to do more than call attention to de Vries' paper.

of the Fallopian tube, and I now give short abstracts of these cases as recorded by the authors.

Péan's account of his case is so brief that it may be transcribed *verbatim*.*

"Case 98. *Hydatid cyst of right ovary; cœliotomy; recovery.*—M. O—, Spaniard, nineteen years old, submitted to operation June 12th, 1888. Brunette, pale, very emaciated. Menstruated first at age of 11; not married. Commencement of trouble ten years ago in the right side of abdomen. No pain. Four months before operation capillary puncture had yielded 6 litres of fluid. Abdomen distended to umbilicus.

"*Operation.*—Abdominal wall incised from pubes to umbilicus; no ascites or adhesions. Cyst wall whitish, moderately thick. On puncture 8 litres of limpid fluid mixed with hydatids. Incision of the cyst enabled us to withdraw a considerable quantity of daughter cysts, and to determine that the cyst originated in the ovary and had become prolonged into the broad ligament. This was clamped, ligatured in two parts, and returned after the excision of the tumour. Duration fifteen months; good recovery; no recurrence."

It is unfortunate that a more detailed description of the cyst after removal was not given, nor any note made of the absence of hydatid growths in other organs. But the authority of Prof. Péan is unimpeachable, and I am certainly prepared to accept this case as the only undoubted instance hitherto recorded of primary hydatid disease of the ovary. Very many cases are on record in which the ovary was involved in extensive pelvic hydatids, but in such instances demonstration of the organ primarily affected is impracticable, and they need not be further referred to.

The previously recorded case of hydatid disease of the Fallopian tube was recorded in full detail by Doléris in 1896. The following is an abstract of his description:

* 'Diagnostique et Traitement des Tumeurs de l'Abdomen,' vol. iii, p. 671.

"M. J—, aged 36, the daughter of a butcher, was married at age of 24, to a man of the same occupation as her father. She was not personally brought much in contact with animals. Towards the end of the first year of her married life she began to suffer from attacks of abdominal pain which often necessitated her staying in bed. At first these attacks coincided with the periods, later they became quite irregular. After a few months constipation and dysuria appeared. An abdominal tumour was discovered in 1888, and thought to be a fibroid; she was treated with ergot for many months, and got much thinner, the monthly loss being diminished. During the last five to six years the tumour has grown rapidly. She has never been pregnant.

"She was seen by Doléris in September, 1895. He found the cervix small and firm, and displaced upwards and forwards behind the symphysis. The body could not be felt. The pouch of Douglas was depressed towards the vagina and contained a firm, regular tumour. Per abdomen a nodular tumour was felt, extending above the umbilicus nearly to the epigastrium, and about the size of a seven months' gravid uterus. Sound passed 8·5 cm. ($3\frac{1}{2}$ inches). The diagnosis was a multinodular fibroid.

"On March 24th, 1896, the patient was submitted to operation. The tumour was found to consist of the two Fallopian tubes enormously enlarged and measuring, the one 57 cm. ($22\frac{3}{4}$ inches) in length, the other 53 cm. ($21\frac{1}{4}$ inches). In general appearance they resembled large intestine, with thickened walls, and were irregularly distended in places. The convolutions of the tumours were intimately adherent to one another by broad surfaces. The cavity was full of hydatid capsules. On the omentum were some small cysts resembling dead hydatids, but there was no other trace of tumour in any of the abdominal organs.

"After removal the tumours weighed 2 kilos. The walls varied in thickness, and were pearly-white in colour, and almost transparent in places. Both tubes were

distended in the greater part of their extent, the right to within 1 inch, the left to within $\frac{1}{3}$ inch of the uterus. The ovaries, though adherent, were normal in appearance."

Doléris's description of the parts removed leaves something to be desired, and the illustration published with his paper represents the tubal swellings intact. But the author clearly regarded the condition as the development of hydatid vesicles within the tubal canal, so that the case differs considerably from that here recorded.

NOTES ON A CASE OF HYDATIDS OF, OR CONNECTED WITH, BOTH OVARIES, RIGHT BROAD LIGAMENT, LIVER, OMENTUM, MESENTERY, AND OTHER PARTS.

Shown by Chas. J. Cullingworth, M.D., F.R.C.P., and H. H. Clutton, M.C.(Cantab.), F.R.C.S.

(Received February 15th, 1904.)

An unmarried lady, aged 24, the eldest of a family of five orphan sisters, was sent to Dr. Cullingworth, in the month of June, 1896, from one of the continental health resorts. She had been under treatment for nine months on account of an abdominal swelling which had been attributed to indigestion. Pain in the left leg having, however, supervened, an abdominal examination had been at length made, and what was believed to be a movable and displaced kidney discovered. The history the patient gave was that, five years previously, viz. in 1891, when in the act of jumping from a chair upon which she had been standing, the chair tilted and she received a blow upon her back. This was immediately followed by severe pain and vomiting, necessitating a week's confinement to bed. She had been subject, she said, to pain ever since.

In July, 1895, she had slipped and fallen over some stones in a mule-path, and had had, as a result, pain in the lower part of the abdomen, requiring the application of poultices. Her doctor was unable, at that time, to come to any conclusion as to the precise cause or seat of the pain. On the only occasion on which he had examined

the abdomen he thought he felt, in the right hypochondrium, a tumour give way under his fingers. He stated, in his letter to Dr. Cullingworth, that as the nausea from which the patient had been suffering ceased immediately, he felt confirmed in his belief that he had replaced a dislocated kidney.

The patient arrived in England on June 6th, 1896, and consulted Dr. Cullingworth on the 19th. She complained of some pain in the morning on passing urine. She had no pain at that time in the region of the kidney. Her general health was fairly good. Her appetite was dainty. The catamenia were quite regular; their average duration was four days; they were normal in quantity and painless.

The abdomen was enlarged by a rounded, fixed, cystic swelling, situated in the supra-pubic region, which was dull on percussion from the pubes upwards. The flanks were resonant. There being some suspicion that the bladder might be distended, a catheter was passed and a pint of clear non-albuminous urine was drawn off. The uterus was felt to be of normal length, and displaced forwards and to one side. A portion of the tumour occupied Douglas's pouch.

The opinion then formed was that there was a cystic tumour either of the ovary or of the broad ligament, and that it ought to be removed.

The patient was admitted into a private nursing home, and, on July 24th, 1896, assisted by his colleague, Dr. Walter Tate, Dr. Cullingworth opened the abdomen by a median incision, and in doing so entered a cyst, from which a quantity of clear fluid escaped and a number of hydatid cysts floated out. The incision was thereupon enlarged. On the hand being passed into the peritoneal cavity, cysts were found connected with both ovaries and with the right broad ligament. All these cysts were removed, and proved to be hydatids. That connected with the right ovary was preserved, and is now No. 2379 B in the museum of St. Thomas's Hospital (see drawing).* The

* The specimen was shown.

broad ligament tumour was of considerable size, and had displaced both uterus and bladder. It had, moreover, burrowed down into the deeper parts of the pelvis, where it was extremely adherent, making it difficult to remove. It was, in fact, removed piecemeal. A bladder sound was

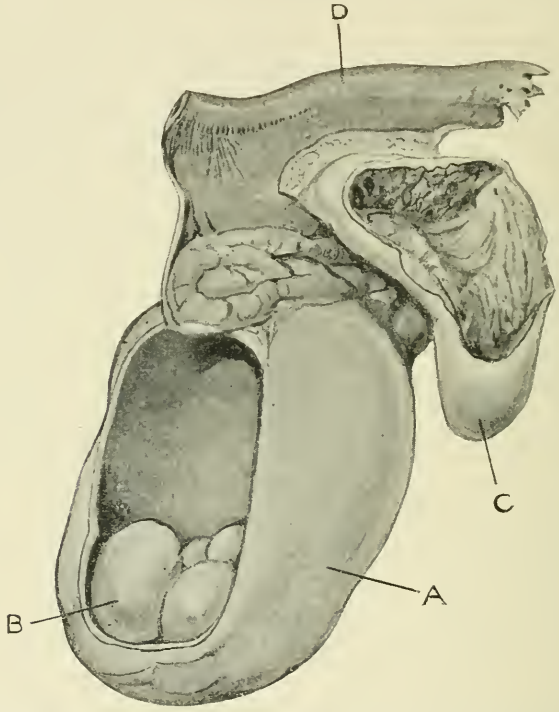

Sketch by R. E. Holding, of the right ovary and Fallopian tube, from the preparation (No. 2379 B) in the museum of St. Thomas's Hospital. *A.* Hydatids of, or attached to, right ovary, seen through the transparent cyst wall. *B.* The same, exposed to view by cutting out a window in the cyst wall. *C.* Torn remains of a burrowing hydatid cyst connected with the right broad ligament. *D.* Right Fallopian tube.

kept *in situ* during the separation of the adhesions to the bladder, which were firm and extensive. The cyst wall was in part much thickened, and presented an appearance suggestive of papilloma. There were observed several small cysts of the omentum, as many as possible of which

were removed. Numerous smaller cysts in the mesentery were also seen, and a large cyst in the right loin believed at the time to be a cyst of the right kidney. A second large cyst in the upper part of the abdomen extended from the splenic region on the left across and upwards beneath the lower end of the sternum towards the right. These were all left to be dealt with at a future time, especially as during the latter part of the operation (which lasted two and a half hours) the patient had been pulseless and in a very alarming condition. Strychnia was injected twice, and the abdomen was closed as quickly as possible. A glass drainage-tube was left in for a few hours, as there was considerable oozing from the raw surface in the deeper parts of the pelvis. Before removing the patient to bed, a catheter was passed. The urine withdrawn was quite clear.

For some hours after the operation the patient was in a condition of collapse, and strychnia was again injected on two occasions, on one of them in conjunction with morphia. The drainage-tube was removed in the afternoon of the day following that of the operation. From that time the patient made a good recovery, her temperature never exceeding 100° F.

It was ascertained on inquiry from the patient and her friends that she possessed a pet dog to which she had been extremely devoted, and which, especially as it had been much out of health, she had constantly tended and been in the habit of kissing and fondling.

When the patient had sufficiently recovered from the first operation, she was transferred to the care of Mr. Clutton, with a view to the attempted removal of the cysts in the *upper* part of the abdomen.

On October 26th, 1896, Mr. Clutton opened the abdomen through the rectus above the umbilicus, and found three large and separate cysts attached to the liver, two at the free margin and one in the body of that organ. There were also several smaller ones. All except two were removed entire, but the ectocystic walls of the two

largest were reduced in size and then attached by sutures to the abdominal incision. It was not thought safe to drop their very large surfaces back into the abdomen. The shock during and after the operation was extreme, and appeared to be due to the traction to which the diaphragm was exposed. The pulse remained at 150 for twenty-four hours. During the operation another large cyst was felt towards the spleen, but this was left for a subsequent operation.

On November 19th, 1896, a swelling having been felt for at least ten days in the left iliac fossa, and increasing pain having been experienced in the front and back of the pelvis, the July incision was reopened by Dr. Cullingworth. One large cyst was evacuated and the wall sutured to the parietal incision. On November 27th a quantity of stinking pus and numerous hydatids escaped *per rectum*. This was followed a few days later by a slough, which was probably the ectocyst. The temperature, which had been high, now dropped to normal, and all the wounds healed.

On February 2nd, 1897, an operation was undertaken by Mr. Clutton for the removal of the cyst which was thought to be in relation with the spleen. The abdomen was opened through the left rectus, and the large hydatid cyst previously felt was found to be attached to the free margin of the left lobe of the liver. It was adherent to the diaphragm and stomach, and could not be brought to the surface. It was therefore packed all round with gauze and evacuated *in situ*. There was the usual countless number of daughter cysts and laminated membranes to be removed. A certain amount of ectocyst was cut away and the remainder sutured to the abdominal incision. The same kind of shock was experienced as in the operation of October, 1896, but it did not last so long after the operation was over. A sinus left from this operation lasted for some years, and was due to silkworm-gut sutures which were gradually drawn up towards the diaphragm out of sight. This was the only one of the patient's many operations which was followed by a persistent sinus.

On January 12th, 1899, the patient reported that she had remained free from any evidence of hydatid cysts until about a month ago. On the 15th Mr. Clutton reopened the cicatrix over the liver to the right of the median line, and another incision was made, still further to the right, through the rectus. Three large cysts, each containing hundreds of daughter cysts, were evacuated and the ectocysts sutured to the abdominal incision. The peritoneal cavity was not opened. Dr. Cullingworth, who was present, took the opportunity of the patient being anæsthetised to examine the pelvis *per vaginam*. He found a large swelling in Douglas's pouch. The bowels soon became difficult to move, and enemata began to return too quickly. On examination on January 31st it was found that the pelvic cyst had increased very rapidly since the operation of January 15th.

On February 2nd, 1899, Dr. Cullingworth made a vaginal incision and found one large cyst, which on evacuation was discovered to be free from any daughter cysts. Rectal examination subsequently proved that the whole swelling, which previously filled the cavity of the pelvis, had gone. On passing a finger into the ectocyst through the vagina, it was found that the cyst was adherent to bone on the patient's right side. By March 22nd all the wounds and sinuses were closed except the sinus of February, 1897. The pelvis was also carefully examined and found to be free from cysts.

On September 20th, 1899, Mr. Clutton removed a large cyst with its ectocyst, from the deep layer of the abdominal wall without opening the peritoneal cavity. It contained no daughter cysts. The pelvis was examined through the rectum, and a round, hard lump was felt in front, which it was thought might be the remains of the ectocyst of a previous operation. It was therefore decided to leave it. At a later operation (January 9th, 1900) this lump had disappeared.

On January 9th, 1900, a cyst was removed from the cicatrix over the liver. It had no daughter cysts. After

this operation the patient remained free from any evidence of hydatid disease till January, 1902. A swelling was then noticed on the right side over the free margin of the liver.

On February 18th, 1902, this cyst was removed without opening the peritoneal cavity. A careful examination of the whole abdomen was made under an anæsthetic, and a small, very movable swelling was found in the right iliac fossa. The patient was unaware of its existence, and it was left alone. This tumour remained stationary in size and gave her no trouble.

Towards the end of 1902 and during the early part of 1903 she had occasional attacks of frequency of micturition, lasting only for a few days at a time, and without any change in the quality of the urine. On September 30th, 1903, Dr. Cullingworth made a bimanual examination and found a large cyst extending from the base of the bladder to the brim of the pelvis on the left side.

On October 20th, 1903, Mr. Clutton opened the abdomen through the left rectus just above the pubes. The cyst was found to be beneath the pelvic fascia and behind the sigmoid flexure. After the peritoneum and fascia had been divided, the cyst, which contained a large number of daughter cysts, was easily extracted. The cavity from which it was removed extended to the bottom of the pelvis. The ectocyst was closed with sutures and left *in situ*. The abdomen was also opened on the right side to remove the cyst, which has been previously described as remaining unaltered since February, 1902. There were found to be two small cysts in the mesocolon, which were easily removed without spilling their contents. They were both very old, without daughter cysts, and one of them was entirely cheesy in consistence. The wounds healed in the ordinary way, but the temperature began to rise ten days after operation, and a distinct swelling appeared on the left side of the pelvis in the position of the closed ectocyst.

On November 2nd this swelling was opened, and offensive pus evacuated. A drainage-tube was introduced.

On November 10th there was an escape of pus *per vaginam*, and on syringing through the drainage-tube above the pubes the lotion ran out below. By November 26th the discharge had almost ceased, and the drainage-tube was removed. On December 7th the sinus had healed. Meanwhile a silkworm-gut suture had been removed from the sinus which had existed so long in the left hypochondrium, and that sinus also healed. The patient therefore left the Home early in December without any sinus.

It is impossible to say that there will be no further development of hydatid cysts, as, in the course of the case, there has already been an interval of two years without any necessity for operation. As the case has now, however, extended over a period of eight years, it seems a pity to keep an interesting record locked up in case-books any longer, and the announcement of Dr. Eden's forthcoming paper suggested the present as a suitable opportunity for publication, though, of course, it is impossible to say that the ovaries, although the first part operated upon, were the primary seat of the disease.

It may be well to add that there has been no menstruation since the first operation. There has been no complaint of flushings or of any of the nervous discomforts that frequently accompany or follow the menopause, and that have been said by some to be specially marked when the menopause has occurred prematurely as the result of operation.

Note.—We should like to take this opportunity of acknowledging our gratitude to Mr. E. F. White, of Putney, who gave the anæsthetic for every operation except the last. In some of the operations, especially those which involved the under surface of the diaphragm, he had a most trying experience. The patient was extraordinarily courageous in returning again and again for fresh operations, but she was really of very feeble constitution, and so nearly ceased to breathe when difficulties arose that both operator and anæsthetist had to cease for a time and await her recovery. Under these trying

circumstances Mr. White was most patient and skilful. Mr. F. C. Abbott assisted in most of the operations, and to him also thanks are due for help and advice in many difficulties.

The President said that in the case narrated by Dr. Cullingworth it was difficult which to admire most—the persistence of the surgeons or the fortitude and endurance of the patient. The success ultimately attained justified the repetition of the operation and the wisdom in dealing with the recurrences. He had seen one case of hydatid in the pelvis where a cyst some $3\frac{1}{2}$ inches by 2 was taken from the side of the uterus and front of the right broad ligament. From its ultimate connection with subjacent structures it bore out the opinion of Mr. Bland-Sutton that these cysts originated in the subserous tissue. There was no evidence of hydatids elsewhere in the body; in this instance it was a single cyst, isolated in the situation found, and possessing all the characters of an echinococcus growth.

Mr. Clutton said that the patient owed her present satisfactory condition to the fact that, contrary to the usual experience, the development of hydatid cysts had, in her case, been hitherto limited to the abdomen. Had the disease affected the thorax or the brain, as so often happened, the result might have been very different. He could not withhold from the patient herself a tribute of admiration for the cheerful courage with which she had faced operation time after time. With regard to the question of pelvic hydatids he could not, speaking as a general surgeon, see any reason for supposing that hydatids in the pelvis differed from hydatids in other parts, or that anything was likely to be gained by considering them separately.

Mr. Bland-Sutton expressed his interest in the papers, and observed that some years ago he had taken great pains to verify the references and study records relating to primary echinococcus colonies of the ovary, and found them unreliable, and he ventured to suggest that Dr. Cullingworth's specimen should be re-examined to determine whether the colony really arose in the ovary or in the connective tissue of the broad ligament, and as it increased in size flattened the ovary over its periphery. Mr. Bland-Sutton had recorded a case of this kind ('Clinical Journal,' October 23rd, 1901). It would also be found that if the distribution of echinococcus colonies among the abdominal viscera was critically examined it would be seen that, in the great majority of instances, the parasite really selected the subserous tissue. This is true of the kidney—where they flourish in the connective tissue of the renal sinus—the bowel, the broad ligament, omentum, rectum, etc. The immunity of the ovary depended on the fact that it lacked a loose serous investment, and this is also

true of the testis, which seems equally immune with the ovary to these parasites. The loose connective tissue of the mesosalpinx and the adjacent portion of the broad ligament formed admirable environments for the maturation of the six-hooked embryo of *Tænia echinococcus*, but was not quite so accessible as the loose connective tissue of the mesocolon, the mesorectum, or the omentum. The multiplicity of the lesions depended on the number of ova swallowed (the extraordinary number of cysts in some patients would suggest the probability that occasionally an entire proglottis had been ingested), and the cysts and colonies gave rise to clinical signs according to the rate at which they grew, and this varied with the favouring nature of their position and the character of the tissue. It seems also certain that the brood-cysts may be *sown* into the connective tissue of the wounds made for their removal, a view supported by the frequency with which echinococcus cysts grew in the cicatrices of operation wounds made for the removal of primary colonies. Of this Mr. Bland-Sutton had observed several cases in his own practice.

Dr. F. E. Taylor congratulated Dr. Eden both on the excellent report he had given of a case which was certainly unique as far as this country is concerned, and on his masterly survey of the whole subject of pelvic hydatids. As Mr. Bland-Sutton had remarked that many of the cases recorded in literature as hydatids of the ovary were not true hydatids—that is to say echinococcus cysts—he (Dr. Taylor) would like to mention the ease with which the echinococcus nature of the cyst in Dr. Eden's case was recognised. On incising the cyst many typical hydatid vesicles at once escaped in the fluid of which circles of hooklets abounded; and microscopical examination of the cyst-wall with its laminated membrane and secondary brood-capsules absolutely proved its nature. Dr. Taylor agreed with Mr. Bland-Sutton as to the predominance of hydatids of the abdomen in the subperitoneal tissues, and believed that Dr. Eden's case was of this variety, its situation in the anti-mesosalpingeal border of the tube, independent of the tube-lumen, lending support to this view. Its occurrence in the Fallopian tube was, he considered, merely an accidental circumstance.

Dr. Cullingworth, in reply to Mr. Bland-Sutton, said that now that his attention had been called to the possibility of the cyst exhibited not being actually ovarian, but having the ovary stretched over it, he would suggest to the curator of the St. Thomas's Hospital Museum that a further examination of the specimen should be made in order to clear that point up. If that were done he would ask permission to append to the paper a note giving the result.

JULY 6TH, 1904.

EDWARD MALINS, M.D., President, in the Chair.

Present—40 Fellows and 4 visitors.

Books were presented by the Staffs of the Middlesex Hospital and the Presbyterian Hospital of the City of New York.

Herbert John Paterson, M.A., M.B., B.C.Cantab., F.R.C.S.Eng., was admitted a Fellow.

Asa C. van Buren, M.B., B.S. (Ashford, Middlesex), was declared admitted.

The following candidate was proposed for election: Thomas Rose, M.R.C.S., L.R.C.P.

The following candidates were elected Fellows of the Society: Mary H. Frances Ivens, M.B., M.S.Lond.; James Cole Marshall, M.B.Lond., F.R.C.S.Eng.; Norman Blake Odgers, M.B., B.Ch.Oxon., F.R.C.S.Eng.; Edward Colston Williams, M.B., B.S.Lond. (Liverpool).

Report of the Pathology Committee on Dr. Horrocks's Specimen of Fibro-myoma of the Uterus undergoing Sarcomatous Degeneration. (See p. 184.)

We have examined sections prepared from the growth, and we find it shows an admixture of smooth muscle-fibres and sarcoma elements, the latter preponderating.

Cuthbert Lockyer.
Herbert R. Spencer.
Peter Horrocks.
G. Bellingham Smith.

May 4th, 1904.

Report of the Pathology Committee on Dr. Herbert Spencer's Specimen of Cancer of the Body of the Uterus simulating Fibroid. (See p. 235.)

We have examined sections prepared from the growth, and are of opinion that it is a glandular carcinoma of the body. The small subperitoneal tumour at the fundus is a fibro-myoma.

Herbert R. Spencer.
G. Bellingham Smith.
Cuthbert Lockyer.

June, 1904.

FURTHER NOTE, CASE OF PRIMARY TUBERCULOSIS OF CERVIX.

By Dr. W. H. B. Brook.

On May 6th of last year I brought before the notice of the Obstetrical Society a case of primary tuberculosis of the cervix, for which I had performed hysterectomy.* A

* See 'Obstet. Soc. Trans.,' vol. xlv, p. 185.

wish was expressed that I should report the subsequent history of the patient.

I saw and examined her on May 24th of this year. She was then in excellent health and had put on weight.

UTERUS WITH CARCINOMA OF THE BODY AND MUTIPLE FIBROIDS.

Shown by Dr. Lewers.

The patient from whom the specimen shown was removed was 45 years of age. She had been married seven years, but had never been pregnant. She was admitted into the London Hospital on February 13th, 1904. Menstruation had always been regular till two years prior to her admission. For the last two years there had been a constant blood-stained vaginal discharge. There had been no severe losses. There had been some pain in the lower abdomen, but only quite recently.

She had noticed a lump in the abdomen six years ago. On examining the abdomen a large, hard, somewhat irregular tumour was felt rising from the pelvis, and reaching in the middle line a distance of 2 inches above the umbilicus. In the right nipple line the tumour reached the ribs.

On vaginal examination a blood-stained, offensive discharge was seen issuing from the os uteri. The vaginal portion was normal, and the external os rather small. The sound passed for 8 inches.

Operation, February 23rd.—The diagnosis made was uterine fibroids, and at the operation Dr. Lewers proceeded with the operation he generally adopts for that condition, namely amputation of the body of the uterus, intending to leave the cervix. On cutting through the cervix at the level of the internal os at this stage of the

operation he found, however, that there was a malignant growth in the lumen of the cervix in the plane of section. Accordingly he proceeded to remove the whole cervix from above; the operation performed was therefore abdominal panhysterectomy. The patient made an uneventful recovery.

Remarks.—The case emphasises the importance when operating for fibroids of having the body of the uterus opened immediately on removal, so that, if a malignant growth is present in the endometrium, the operator can immediately continue the operation, and remove the cervix also. He also thought as carcinoma of the body, not very rarely in his experience, is a complication present in cases of uterine fibroids, the possibility of such a conjunction should be borne in mind when the question of expectant treatment or operation was under consideration.

Dr. Herbert Spencer suggested to Dr. Lewers that instead of having an assistant to open the amputated fibroid uterus at the time of the operation to see if it contained malignant disease, which it would in some cases be quite impossible to decide, he should remove the entire uterus by total hysterectomy. The presence of an assistant for the above purpose had been suggested by Cullen, who preferred to amputate the uterus through the cervix and reserved total hysterectomy for cases where malignant disease might develop in the cervix. As numerous cases showed that malignant disease might develop in any cervix, it logically followed that Cullen ought to remove the cervix in every case. He hoped therefore soon to see Cullen a convert to total hysterectomy. Dr. Lewers seemed to make little of cutting through the malignant growth in cases of cancer complicating fibroids if the cervix were afterwards removed, but there could be no doubt that the risk of local implantation of cancer was greater in that case than if the uterus were removed entire. His own case of cancer of the body complicated by fibroids removed by total hysterectomy was free from recurrence after six and a quarter years, a result which might have been less satisfactory had he first amputated the body. He had two years ago expressed his belief in the superiority of total hysterectomy over amputation for fibroids, and he was glad to hear from Mrs. Scharlieb that she too liked the operation. For his own part he

had not amputated a fibroid uterus for four and a half years. There were cases of malignant disease which could not be distinguished from fibroids before or during an operation, and there were many cases recorded in which malignant disease had subsequently developed in the cervix which had been left behind. He believed a careful study of statistics showed that the total operation was the safer of the two, for reasons stated in the paper alluded to, and his preference for total hysterectomy for fibroids was increased by the report of cases like those of Dr. Lewers and Dr. Tate, in which the cervix had to be subsequently removed owing to the discovery of cancer in the body.

Dr. Amand Routh thought Dr. Lewers' view that cancer was often associated with fibroid tumour of the uterus was incorrect, and should certainly not be held to be an argument in favour of hysterectomy before the menopause. If, however, metrorrhagia became a symptom after the menopause in a woman known to have had a fibroid, it was strong presumptive evidence of cancer having developed. In such a case, if the uterus were removed it should be by panhysterectomy. Dr. Routh did not, however, consider that cancer was relatively so frequent in fibroid uteri as in cases where no fibroids were present.

Dr. Galabin said that one symptom in Dr. Lewers' case, namely metrorrhagia, might have raised the suspicion that cancer existed as well as fibroid. He had met with several cases of this kind in which exploration of the uterus by a curette failed to reveal the cancer which lay beyond reach or in some recess under the fibroid, and in which the disease was only revealed either by removal of the uterus or dilatation sufficient to allow the finger to explore. He considered that in all cases of fibroid in which continuous or irregular hæmorrhage could not otherwise be cured in a moderate time, the uterus ought to be removed. He had met with the combination of fibroids with cancer of the fundus commencing from the endometrium so often that he thought that the fibroids predisposed to the cancer. In one instance the cancer was precisely limited to the endometrium covering the fibroid. He agreed with Dr. Spencer that panhysterectomy involved no greater risk than supra-vaginal hysterectomy, though he did not follow him in preferring panhysterectomy in all cases. He was accustomed to choose that operation in parous women if the cervix were lacerated or inflamed or showed adenomatous hypertrophy or any other lesion. But in single or nulliparous women with a healthy cervix, he thought that if supra-vaginal hysterectomy were performed there was no appreciable risk that the cervix left behind would afterwards become affected by cancer.

Mrs. Scharlieb entirely agreed with Dr. Herbert Spencer that panhysterectomy for fibroids was the best operation both for

immediate and remote results. In supra-vaginal amputation the cervix was left and might become the seat of malignant disease in after years. It was demonstrated by Dr. Lewers' case and by many others that malignant disease of the endometrium may co-exist with fibroids, and that its presence may not always be detected before or during operation.

Dr. Lewers thought for the greater number of cases of uterine fibroids requiring operation amputation of the body of the uterus, leaving the cervix, was the best operation. Of course, if a malignant growth were detected during the operation the cervix also should be removed. It happened sometimes that in hysterectomy by the method described a very small portion of the mucous membrane of the body of the uterus was unintentionally left. This was an advantage, as then he found such patients had slight monthly losses, and suffered much less, or not at all, from the disturbances incidental to the production of an artificial menopause.

CYSTIC TUMOUR OF UTERUS.

Shown by Dr. Purslow.

This specimen was removed from a married woman, 24 years of age, who was admitted to the Queen's Hospital, Birmingham, November 12th, 1903, with an abdominal swelling the size of a seven months' pregnancy.

She stated that she had first noticed the swelling of the abdomen six weeks previously, and that since that time it had been rapidly increasing in size and that she had lost flesh and strength lately.

On examination.—The abdomen was found to be distended by a cystic tumour having the characters of an ovarian cystoma, and a diagnosis of this condition was made, the rapid growth of the tumour and the loss of flesh giving rise to a suspicion of malignancy.

Operation.—The abdomen was opened in the middle line, the cyst exposed and tapped and a large quantity of thin yellow fluid evacuated from two loculi.

The cyst was found to be growing from the fundus uteri; it had lifted up and invaded both broad ligaments and the mesosigmoid, and had formed numerous thick omental adhesions; the latter were tied and divided and the broad ligaments were treated in the same way. When the level of the internal os was reached the uterus was cut across and the body of the uterus with the tumour removed.

A gauze drain was passed through the posterior fornix into the vagina, and the abdominal wound was completely closed.

The operation was prolonged and difficult, but the patient rallied well and eventually made a good recovery.

On examining the specimen it will be seen that the cyst wall is directly continuous with the tissue of the fundus uteri. There is no communication between the cavity of the cyst and that of the uterus.

A microscopic examination showed that the wall of the cyst consisted of interlacing muscle-fibre bundles and was lined on its inner aspect by a mass of blood and inflammatory exudate in various stages of organisation. There was no epithelial lining.

The cyst is, therefore, probably a degenerated fibroid, but the unusual points about the case appear to me to be the early age of the patient and the rapid growth of the tumour, and it is with the hope of learning something more of its character that I have brought this specimen here this evening.

TUBAL MOLE.

By Dr. Purslow.

This specimen was removed from a patient, thirty-six years of age, who was sent to me by Dr. Darlington, of Handsworth, and gave the following history:

Menstruation commenced at sixteen, and had always been regular, though attended by considerable pain. The patient had been married twelve years, but had never, so far as she knew, been pregnant. She had been complaining for some considerable time of pain in left ovarian region, which for the past few months had been getting worse; it was this pain which caused her to consult Dr. Darlington, and he had tried various methods of treatment without giving her relief.

State on admission.—On bimanual examination a small tender mass could be felt on the left side of the uterus, and from its character I considered it to be a swelling of the Fallopian tube.

The patient was admitted to the Queen's Hospital on April 21st, 1903, and two days later the abdomen was opened. A small mass of greyish-purple colour was found adhering loosely to the fimbriated extremity of the left Fallopian tube; it was readily detached on gentle manipulation and came away in the fingers. The tube appeared to be normal, and the uterus and other appendages were normal, so that nothing further was done. The wound healed by first intention, the pain disappeared, and has not returned.

On examining the specimen, which measures about 2 inches by 1¼ inch, and is roughly oval in shape, it is seen, on section, to be composed mainly of blood-clot, but in its interior a distinct amniotic cavity with a fœtus of three to four weeks' development can be seen. The outer covering of the mass is of a greyish-purple colour, except at one spot about the size of a sixpence, where this covering is

absent and the deep red colour of the interior blood-clot is seen; this area marks the site of attachment to the fimbriated extremity of the tube.

On making further inquiries of the patient after the operation, she stated that two and a half years previously she missed two periods, and that when menstruation reappeared the period was profuse.

The case may, I think, be considered to be one of practically complete tubal abortion, and the history leaves little doubt that the pregnancy in the tube occurred two and a half years before the operation, as that was the only interval of amenorrhœa during twelve years of married life.

Complete extrusion of the ovum from the fimbriated extremity of the Fallopian tube in cases of tubal pregnancy is, I believe, a rare condition.

Professor Taylor, in his well-known book on extra-uterine pregnancy, says: "In a very few cases (one is reported by Mr. Sutton) the mole is extruded from the Fallopian tube into the abdominal cavity, forming a true tubal abortion."

THREE CASES OF VARIATION OF THE POSTERIOR FONTANELLE IN CHILDREN.

Shown by Dr. A. W. Sikes.

Dr. A. W. Sikes showed three specimens illustrating the above. In one there was a small Wormian bone completely filling up the fontanelle; in another the squamous portion of the occipital bone was small, and what ought to have been the fontanelle was filled up with two small bones. In a third badly ossified case, the posterior fontanelle showed four fissures, and in appearance closely resembled the anterior.

Dr. Boxall remarked on the frequency with which deviations from the normal type of posterior fontanelle occurred.

FIBRO-MYOMA AND CYSTIC DISEASE CO-EXISTING IN THE SAME OVARY.

Shown by Dr. Walter Tate.

M. B—, a widow, aged 71, was admitted to St. Thomas's Hospital in March, 1904, with the following history. The periods began at 19, and were always accompanied by pain. She was married at the age of 30, and had one miscarriage at the sixth month. The menopause occurred at 46. A year after the menopause patient noticed that her stomach was getting larger. She began to lose flesh, and had severe pain across the lower abdomen. She was in the Waterloo Road Hospital for two months. The abdomen continued to get larger until 1891, when she had a fall, and the abdomen then returned to its normal size. Patient remained fairly well from this time till two years ago, when the abdomen again began to enlarge. There has been severe pain and progressive enlargement of the abdomen during the last two years. She has also had occasional hæmorrhage from the vagina, the last occurring about a fortnight ago.

On admission, the abdomen was found to be distended to the size of a seven months' pregnancy. The greater part of the distension was due to a cystic tumour which occupied the abdomen, but in the left hypochondrial region there was a hard mass, of the size of a fœtal head, which was continuous with, and appeared to form part of, the cystic tumour. There was some prolapse of the vaginal walls, but the tumour did not encroach on the true pelvis.

On March 22nd abdominal section was performed. The tumour was everywhere firmly adherent to the

abdominal wall, bowel, omentum and contiguous structures. In one place, where the adhesion to bowel was very dense, a small portion of the cyst wall was left attached. The abdominal cavity was douched, and the wound closed without drainage. The tumour removed consisted of two distinct parts—a solid portion of the size of a fœtal head, which appeared to grow in the wall of the cystic tumour, and a cystic portion, the wall of which was inflamed, and lined by lymph. On section of the solid portion it presented a firm fibrous appearance, with commencement of necrotic change in the central part. On section the tumour proved to be a fibro-myoma. The wall of the cystic portion on section showed chronic inflammation.

Mr. Alban Doran had observed cystic disease in association with myoma of the ovary. The specimen was figured in the 'Edinburgh Medical Journal' (vol. iii, p. 455, 1898), and he had exhibited it two years since, before the Society, as part of the discussion on Dr. Fairbairn's paper on "Fibroid Tumour of the Ovary" ('Obstet. Soc. Trans.' vol. xliv, p. 168, 1902). The tumour had caused severe pain, simulating inflammatory disease of the appendages.

NECROBIOTIC UTERUS ASSOCIATED WITH RECENT PREGNANCY.

By Alban Doran, F.R.C.S., and Herbert Williamson, M.A., M.B.

This fibroid uterus was removed from a patient who had recently been pregnant, and the changes in the fibro-myoma which it bore were most probably due to the pregnancy.

Mrs. E. B—, aged 38, married six months, was sent into my wards in the Samaritan Free Hospital by Mr. Butler-Smythe on December 16th, 1903. He had diagnosed tumour associated with pregnancy. The patient had

noticed swelling of the abdomen for over one year, and the period had been absent for four months. The abdomen was greatly distended, its integuments were markedly pigmented; a dark streak, corresponding to the middle line, extended from the pubes to over two inches above the umbilicus. The distension was due to a large tumour slightly bilobed; the right portion nearly touched the ribs; the left did not extend quite so much upwards, but reached the left hypochondrium. It also lay obliquely, its lower part passing across the middle line so as to cut off the right portion from the right iliac region.

The right portion was very resistant, yet on palpation distinct contractions were occasionally felt, and there was suspicion of a fœtal head within its limits. The left portion fluctuated on percussion; a souffle was audible to the right of the middle line inferiorly, and a fœtal head could distinctly be defined. On December 29th I explored. On reaching the peritoneum I could feel the fœtus quite distinctly in the left portion of the mass; the head lay below, and there was nothing to impede natural delivery. The tumour, the character of which was not absolutely clear, lay quite above the uterine cavity. I thought that the best course was to leave it alone until after labour.

Dr. J. R. Johnson, of Richmond Hill, attended this patient at her confinement, which took place at term on April 9th. Delivery was spontaneous; the child was a very small but apparently healthy male. It rapidly gained flesh and weight within the first month, yet died rather suddenly when seven weeks old. Mr. Johnson detected a large tumour rolling about from side to side in the abdomen, which remained very lax after the birth of the child. He noticed that the tumour was painful on pressure.

On May 2nd the patient got up, and in the night had a violent attack of pain referred to the epigastrium. It strangely simulated those familiar symptoms caused by axial rotation of an ovarian cyst. The pains subsided on rest, and on May 7th the patient was readmitted into the Samaritan Hospital.

I noted remarkable pigmentation of the skin of the abdomen, which had developed since she was discharged from the hospital in January. On examination I found a freely movable oval mass occupying the middle of the abdomen from the pubes to the epigastrium. It was uniformly elastic, without any sign of fluctuation on percussion, and, what was most significant, it was distinctly tender on touch. The uterus was small and soft, and on the tumour being moved laterally the movement was imparted to the body of the uterus. The base of the tumour came down into the pelvic brim, the cervix lay posteriorly. The temperature on admission was 101°, and there was free show.

Diagnosis was not very easy; the recent history of a sudden attack of pain suggested ovarian tumour with twisted pedicle, a very common accident after delivery. The uterus, however, seemed closely connected with the tumour.

I operated on May 12th. The tumour, as may be seen, proved to be a fibroid of the body of the uterus, which I amputated a little above the cervix; there was no morbid tissue of any kind on the divided surface of the stump, and the portion of the uterine cavity exposed seemed quite healthy. Both ovaries were saved. The patient recovered without any complication.

The temperature, which had reached 101° for three nights after admission and fallen to 99·4° on the morning of the operation, rose to 101° on the evening after the removal of the tumour. It fell to 99° within twenty-four hours and never rose higher in the course of convalescence.

Description of the tumour.—Dr. Herbert Williamson examined the parts removed, the specimen, which weighed 8 lbs., having been sent to the Museum of St. Bartholomew's Hospital, and kindly wrote out for me the following report:

"The tumour is of oval shape, everywhere smooth, rounded, and clad with peritoneum, except over the lowest portion, where this membrane has apparently been stripped

down during the operation. In one or two places small subperitoneal nodules are seen. Two inches from the lowest part of the specimen on either side is the point of attachment of the Fallopian tubes. These structures have been divided close to the tumour, and their proximal ends are included in a ligature. A little anterior to the attachment of each tube, at the same level, is the round ligament.

"On the plane of amputation is seen the aperture of the uterine cavity. This lies towards the posterior part of the tumour. A probe introduced through this opening passes for a distance of 3½ inches backwards and somewhat upwards.

"The dimensions are—length 11·5 cm., circumference at widest part 20·5 cm.

"On section, the tumour is seen to be a fibro-myoma situated in the anterior wall of the uterus. The cavity of the uterus, enlarged to a length of 3½ inches, lies behind and below. The fibroid is large, single, and of the interstitial variety; it is everywhere definitely encapsuled by uterine wall, though in some places the exact line of demarcation is not easy to determine.

"In colour it is red and fleshy-looking; the colour is apparently due to staining of the whole mass with blood pigments. In parts it became distinctly darker after exposure to the air. One or two large vessels are seen cut across near the centre of the tumour, and scattered throughout are numerous small, almost punctiform, hæmorrhages.

"The consistence is soft and jelly-like, so that it can be deeply impressed by the finger; after section a fluid of a mucoid character exuded from the surface. The arrangement of the various whorls which constitute the tumour can still be made out, but their outlines are blurred and indistinct.

"The tumour is undergoing those forms of degenerative change which are described under the name of 'necrobiosis.' As the specimen was hardened in formalin before it was

cut into, the presence or absence of the characteristic fish-like odour was not determined.

"The specimen illustrates a fact which has been well shown by several degenerate fibroids which have recently been submitted to me for examination, namely, that necrobiosis is not a form of degeneration *sui generis*, but is associated sometimes with calcification and sometimes with the presence of ragged necrotic cavities in the centre of the tumour. HERBERT WILLIAMSON."

Several specimens illustrating sloughing or necrobiotic changes in uterine fibro-myoma have been exhibited before this Society during the present year. In Mrs. Boyd's case (*vide supra*, p. 198) necrobiosis was independent of gestation. In Mr. Malcolm's (p. 15) sloughing of the centre part of a fibroid occurred in the puerperium, and the uterus was removed a few weeks later. A good drawing (*vide supra*, Pl. II, p. 18) of a section made by Mr. Handley illustrates the report of this case. Lastly, Dr. Fairbairn exhibited a necrobiotic fibroid from a recently delivered patient aged 22 (*vide supra*, p. 194). The specimen which I exhibit represents a similar condition with a similar clinical history.

The severe pain, as well as tenderness, was a remarkable feature in this case. Both Dr. Cullingworth and myself have noted tenderness as a symptom in cases of necrobiotic fibroid. Stouffs, of Brussels,* reported a case of necrobiotic fibroid, removed, as in Dr. Fairbairn's and the present case, shortly after pregnancy. The patient complained that the tumour was tender. Pain and rise of temperature were reported as very marked in Dr. Victor Bonney's patient,† where necrobiosis had occurred independently of gestation.

In the present case, where gestation and the puerperium

* "Fibrome utérin en voie de dégenérescence nécrobiotique post partum," 'Bulletin de la Soc. Belge de Gyn. et d'Obstet.,' vol. xiii, 1902—3, p. 71.

† "Uterine Myoma undergoing Red Degeneration," 'Trans. Obstet. Soc.,' vol. xlv, p. 464.

must have played a large share in causing the pathological changes, there was not only tenderness with rise of temperature, there was also acute pain, so sudden in its onset as to simulate a well-known clinical phenomenon associated with ovarian tumours, especially as a complication of pregnancy and the puerperium.

Dr. Amand Routh alluded to a case of necrobiotic change in a fibroid due to axial rotation of its pedicle at the fifth month of pregnancy. The tumour occupied the whole of the right side of the abdomen, and was stated by the medical attendant to have doubled its size in a few days. The symptoms were acute, and consisted of shock, severe pain, and vomiting. Axial rotation of an ovarian cyst with hæmorrhage into its sac was diagnosed. When he opened the abdomen the tumour was found to be a fibroid with a half twist of its pedicle. The fibroid was removed, and the patient recovered without disturbance of her pregnancy. Dr. Lockyer had examined the fibroid, and reports necrobiotic changes, many muscle fibres being opaque and blurred, and their nuclei invisible. The capsule contained much coarse hyaline material.

Mr. Butler-Smythe considered Mr. Doran's specimen interesting from the fact that there was much difficulty in making a diagnosis by those who examined the patient, the general impression being that the woman was pregnant and that she had an ovarian tumour also. Mr. Butler-Smythe had diagnosed pregnancy complicated by a fibroid. Mr. Doran decided to operate, but when the abdominal wall was cut through down to the peritoneum the movements of the child were so evident all over the abdomen that Mr. Butler-Smythe urged Mr. Doran to close the wound as there was nothing about the situation of the tumour that would interfere with labour at the full time. The abdomen was closed and the patient did not miscarry. She went home and was safely delivered, and, in fact, had a perfectly normal labour. Later on she was readmitted by Mr. Doran, and again there was the same difficulty in making a diagnosis. The patient's abdomen was occupied by a centrally situated, movable tumour, in which there was some sense of fluctuation, but which Mr. Butler-Smythe still insisted was a uterine fibroid with some softening connected with the changes following pregnancy. The abdomen was opened, a perfectly simple fibroid was disclosed, pyriform in shape, and an ideal one for hysterectomy from a teaching point of view.

Dr. Fairbairn was very interested in this specimen, as it corresponded closely to several of those in the series of nineteen which he had investigated. With regard to the influence of

pregnancy he found that seven of them were from pregnant or recently delivered patients, another seven from patients who had been pregnant at some time, but in the remaining five cases the patients had never been pregnant. Pregnancy, therefore, appears to have some influence in the causation of this necrobiotic change, but cannot be the only factor. That it is not due to labour and the changes during the puerperium is shown by its frequent occurrence early in pregnancy. Mr. Bland-Sutton was the first to call attention to the resemblance of the acute symptoms which sometimes arise to those of axial rotation of an ovarian cyst, and several cases have been put on record where this mistake was made, including the one recently shown by the speaker at this Society. Tenderness certainly appears to be more common in the pregnancy cases than in the non-pregnant ones, but generally speaking it is not so common a symptom as pain, which was present in five sixths of the nineteen cases mentioned. Fever, though occasionally observed, is unusual.

Mr. Alban Doran, in reply, said that the histories of axial rotation of the uterus itself by fibroid tumours were of high interest, but that complication was not detected in his own case, notwithstanding the symptoms. He remained firm in his opinion that the exploratory operation showed that there was nothing present to interfere with normal labour, so that removal of the uterus would then have been quite unjustifiable. As for the cause of necrobiosis, Mr. Doran had operated on many cases where there had been no pregnancy. In two the patients were neurotic spinsters, one of whom had been laid up for nearly twenty years after a railway accident. In a specimen which he had removed and had described in a paper prepared by Dr. Lockyer and himself ('Trans. Obstet. Soc.,' vol. xliii, p. 272) the necrobiotic fibroid lay in a position unfavourable for its nutrition. There was some doubt as to whether it had been infected through an intestinal adhesion.

FIBROMA OF THE OVARY.

Shown by Dr. Frank E. Taylor.

This specimen was removed on June 27th, 1904, by Mr. Bland-Sutton in the Chelsea Hospital for Women, from a sterile married woman, aged 50, who complained of

dyspareunia of extreme severity and of many years' duration. On bimanual examination, a small, irregularly lobulated mass was felt behind the cervix at the bottom of the pouch of Douglas. The tumour was of such stony hardness that the diagnosis of calcified *corpus fibrosum* of the ovary was made.

A median subumbilical cœliotomy was performed. A solid tumour of the left ovary was found, and the left appendage was ligatured off and removed. The uterus was small and rudimentary. The right ovary showed no sign of disease. There was no trace of ascites.

The specimen consists of the left appendage, in which the tube and mesosalpinx, though somewhat lacerated during removal, are normal. In the outer border of the mesosalpinx, close to the fimbriæ, is a translucent thin-walled cyst containing clear fluid, of the size of a pea.

The ovary presents normal relations to the tube and mesosalpinx, and is small and shrunken, an appearance normally presented by ovaries in women past the menopause. From its outer pole there springs a more or less pedunculated, densely hard, lobulated tumour, with a smooth and glistening white surface. It measures $2\frac{1}{8}$ by $1\frac{3}{4}$ inches, and weighs $2\frac{1}{2}$ ounces.

On section of the tumour, no calcareous matter was found, and the resistance to the knife gave the impression of dense fibrous tissue. There was no trace of any capsule, nor is ovarian tissue spread out over its surface. Microscopic examination shows the tumour to be composed of connective tissue rich in nuclei, and with rather large spindle-shaped fibres, giving the appearance of young connective tissue, which is characteristic of the fibrous tissue composing ovarian fibromata. By the application of van Gieson's method of differential staining the whole section takes the pink stain diffusely with a complete absence of yellow-stained fibres. No trace of ovarian tissue is discernible. The tumour is therefore a pure fibroma of the ovary.

Ovarian fibromata have been shown by Fairbairn, in

the 'Transactions' of this Society for 1902, to be of three types.

In the first type the whole ovary is converted into a hard tumour, more or less maintaining its original shape, and leaving no recognisable portion of its original structure. It is to this type that the common text-book descriptions apply.

In the second type the growth forms a hard tumour within the substance of the ovary, which is spread out over its outer surface, so that it is more or less encapsuled within the organ. All Fairbairn's specimens conformed to this type.

The third type consists of pedunculated fibromata springing from the outer surface or from one pole of the ovary. They have been likened to subserous fibro-myomata of the uterus. The possibility of their origin from the fibrous capsule of the ovary has been pointed out. They are undoubtedly the rarest of the three types of ovarian fibromata, and it is as a typical specimen of this, the rarest of all the varieties of ovarian fibromata, that I show this specimen to-night.

The specimen was submitted to the Pathology Committee.

Dr. Fairbairn said this form of ovarian fibroma appeared to be rare, and not to attain the size of the commoner forms. It was also more fibrous, containing few or no muscle cells, and was usually extremely hard. Probably it arose from the tunica albuginea and not from the ovarian stroma.

ON SACS CONTAINING FŒTUSES AND LYING FREE IN THE PERITONEAL CAVITY OF A RABBIT.*

By Dr. M. S. Pembrey and Mr. G. Bellingham Smith.

(Received March 12th, 1904.)

(*Abstract.*)

Five fœtal sacs were found free in the abdominal cavity of a rabbit. They were 7 or 8 cm. in length, 4 or 5 cm. in width, and 2 cm. in thickness. The largest contained four fœtuses, the development of which showed that they were at full term. The sacs are formed of the fœtal membranes thickened by fibrinous exudate; the placenta can be seen, but its maternal surface has been covered over by a similar exudate. The amniotic fluid has been absorbed, and the fœtuses are compressed.

The abdomen of the mother showed well-marked signs of former peritonitis, but there was no evidence of placental attachment. The uterus, on careful examination, showed evidence of a former rupture in the shape of an old scar at the junction of the two uterine horns.

The fœtuses had evidently been retained for at least eight months before the animal was killed, for during the time she was kept in the laboratory she produced four normal litters. The rupture was probably caused by the impaction of the four fœtuses which were found in one sac, and which showed signs of torsion.

The case supports the view of Mr. Bland-Sutton that such fœtal sacs are not due to extra-uterine pregnancy but to rupture

* The specimens were exhibited at a meeting of the Obstetrical Society on July 6th, 1898. *Vide* 'Obstet. Soc. Trans.,' vol. xl, 1898, p. 253.

of the uterus and extrusion of the sacs into the abdominal cavity.

In connection with the subject of extra-uterine pregnancy considerable interest must be attached to the fœtal sacs which have been found by various observers in the peritoneal cavity of domestic animals. Many of these cases have been recorded as extra-uterine gestation, either primary or abdominal; others have been attributed to extrusion of the fœtal sacs after rupture of the uterus. Bland-Sutton has maintained that the latter view explains nearly all the cases of so-called extra-uterine gestation in animals, and in this he is supported by the recent work of Kamann.

In the case which is now recorded the animal had completely recovered from the peritonitis which had apparently followed the rupture of the uterus and the escape of the fœtal sacs into the peritoneal cavity.

Description of case.—A pregnant rabbit was bought for breeding in October, 1897, and between that time and June, 1898, produced four normal litters. It was noticed that the abdomen appeared to be somewhat distended after the casting of a litter. On that account, and because she neglected or devoured her young, she was killed within a week of the last littering. Before the abdomen was opened, palpation revealed two or three discoidal bodies, which were freely movable in the peritoneal cavity. When the abdomen was explored, five white discoidal bodies, 7 or 8 cm. in length, 4 or 5 cm. in width, and 2 cm. in thickness, were found together with a few small pieces of a compact white substance. None of these bodies showed any attachment to the abdominal organs or to the peritoneum; in all but the smallest sac the head, body, and limbs of a fœtus could be felt.

In order that a thorough examination of the viscera might be made, another doe rabbit of a similar size, 53 cm. long, was killed and dissected side by side as a control.

Examination of thorax and abdomen.—There was no sign of pleurisy; the only abnormality in the chest appeared to be some small patches of "lymph"* over the left and right ventricles of the heart. The parietal and visceral peritoneum were carefully examined. The under surface of the diaphragm showed no signs of adhesions, nor were any observed between the intestines and the abdominal wall. There were, however, well-marked adhesions between the coils of the cæcum; and here, in addition to flakes of lymph, was found a small cyst, which was 0·5 cm. in diameter and contained a brownish fluid. The parietal peritoneum of the left, and especially of the right, flank showed numerous small projections of "lymph"; in the hypogastric region these were most marked, and attained a length of half a centimetre. These flakes are deposits of fibrinous exudation, and not the remains of ingrowths into, or of outgrowths from, the abdominal wall; stripping up the peritoneum shows that the flakes are only attached to the free surface, and microscopic examination revealed no sign of placental tissue. In the case of the stomach and spleen nothing abnormal was noted, except that the latter organ was twice as large as the spleen in the control rabbit. The free margins of the liver were rough and thickened, and in two places were attached by adhesions to the omentum.

Generative organs.—The ovaries and Fallopian tubes were normal in appearance; there were no adhesions, and the fimbriated extremities were patent and showed no signs of inflammation. The broad ligaments were thickened, and in places showed patches of lymph; these flakes were numerous upon the two horns of the uterus, and upon the posterior surface of the right horn about 6 cm. from its opening into the vagina was a projection of lymph 1 × 0·5 cm. The two horns were slit open and examined throughout their length; no scar or sign of rupture could be seen. The projection of lymph was at

* The term "lymph" is used to indicate fibrinous exudation.

first considered to be the probable site of a rupture; that portion, therefore, of the right horn of the uterus to which the lymph was attached was excised and examined by means of microscopic sections. No signs of scar tissue could be found.

A further examination of the uterus, however, was more successful. On the front of the uterus, just below the external junction of the two cornua, was found a ridge of tissue lying nearly horizontally, and resembling in appearance a scar. It started as a thickened elevation on the left horn and became thinner as it stretched across the right horn. It was 2·5 cm. long, lay about 1·5 cm. above the openings of the two horns into the vagina, and was confined chiefly to the right horn. Microscopic examination of the bullous portion of the ridge showed well-marked fibrous tissue. No such ridge could be seen in the normal uteri of the other rabbits which were examined.

General description of the fœtal sacs.—The five sacs are flattened ovoid bodies with a smooth white surface; the remains of the placenta can in four of the specimens be easily felt under the surface; the placental tissue is covered by a continuation of the smooth opaque membrane which encloses the fœtus. In each case the sac is apparently composed of the fœtal membranes and a dense layer of adventitious fibrinous deposit; the larger portion of the placenta has been detached or worn away, and evidence of the former fate is forthcoming in the small pieces of compact white substance which were found in the peritoneal cavity. Microscopic examination of this substance showed clearly the remains of placental tissue embedded in fibrinous material. These sections for the sake of comparison were examined side by side with specimens of normal placenta from a rabbit.

The external surface of the sacs appeared to the naked eye to be quite devoid of blood-vessels. None of the sacs contained any free fluid, the body of the fœtus being in close contact with the wall.

The individual sacs and their contents.—The largest

sac, I, is of special interest, for it contained four fœtuses, and it is probable that the impaction of these fœtuses caused a rupture and the extrusion of the fœtal sacs.

The outside of the common sac is roughened in places by flakes of lymph; inside there are several portions of placental tissue, some of the pieces being attached, others free.

Two of the fœtuses are attached by umbilical cords to the remains of the placental tissue in the wall of the sac; they are in a better state of preservation than the other two fœtuses, and their bodies show two complete twists. Their cords have been twisted round and round as many as five or six times, and so tightly around the hind legs that these limbs are much twisted and almost amputated. The twists of the body and of the umbilical cord are in each case continuous and in the same spiral direction.

The other two fœtuses show slight signs of previous torsion, and are not connected by umbilical cords to the sac; there are, however, the remains of the cord in each case.

There are no signs of putrefaction; the fœtuses appear, from their size, from the development of fur upon the head, and from the condition of the incisor teeth, to be at full term. In each case there are patches of lymph scattered over various parts of the body. There is no normal colouring matter in the fœtal bodies; water has evidently been absorbed from them, and some of the tissues have undergone a fatty degeneration or infiltration.

Sac II is 16·5 cm. in circumference, 7 cm. long, and 5 cm. wide. The surface is smooth with the exception of a few fibrinous projections near the placental site, which can be readily distinguished by touch. The wall of the sac is translucent, and is not adherent to the fœtus; the head and body can be easily distinguished by touch, but they are considerably compressed, probably by the absorption of water and the contraction of the sac.

Sac III is 16·5 cm. in circumference, 6·5 cm. long and 5 cm. wide. The surface is smooth, but the wall of the

sac is much thicker than in number II and is opaque. The placental site and the various parts of the body of the fœtus can be easily distinguished by touch. As in the case of sac II, considerable compression has occurred.

Sac IV is 15·5 cm. in circumference, 4·3 cm. wide, and 6 cm. long. The surface is smooth, and in thickness and opacity resembles No. III. It is not possible with certainty to distinguish by touch the placental site or the various parts of the fœtus. The wall of the sac is in places slightly adherent to the fœtus, but can be easily detached. The sac was cut open and the fœtus was found to be tightly compressed and twisted in the posterior portion of the body. The placenta could be easily distinguished, and microscopic section showed the characteristic structure. The body of the fœtus shows signs of fatty degeneration.

Sac V is 13 cm. in circumference, 5 cm. long, and 3·5 cm. wide. The walls of the sac are thin, and on section are found to be firmly adherent to the fœtus, the form of which cannot be distinguished owing to the compression and fatty degeneration or infiltration. The placental site could be easily recognised before the sac was opened.

The evidence in favour of rupture of the uterus and extrusion of the fœtal sacs.—It has already been stated that direct evidence of rupture of the uterus was found. It is necessary, however, to consider also the indirect evidence in favour of this explanation, for the scar might easily have been overlooked or mistaken for a muscular band.

In the first place gestation in the Fallopian tubes or ovaries may be excluded, for the appendages are quite normal. The development of eight fœtuses to full term would doubtless have left indelible marks upon these organs. There remain the possibilities of primary abdominal gestation and rupture of the uterus or vagina. Against the former view is the complete absence of any sign of former placental attachment between any of the

five sacs and the abdominal organs or parietes. It is true that there are flakes of lymph scattered about the abdominal wall and viscera, but none of these show under the microscope any other characteristic than that of a fibrinous exudate. Such an exudation would arise as a part of the inflammatory reaction to the expulsion of the fœtuses into the abdominal cavity. No abnormal vascularity was observed in any part of the abdomen directly after the death of the animal from poisoning with coal-gas.

It has already been stated that a careful examination of the entire genital tract side by side with the organs of a normal doe showed evidence of a former rupture of the uterine horns about 1·5 cm. above their opening into the vagina. This scar, which was overlooked when the specimens were exhibited at the meeting of the Obstetrical Society, showed in microscopic sections the presence of fibrous tissue filling the space between the separated muscle of the uterus. The rupture must have occurred at least eight months before the examination of the animal, for in that interval she had four normal litters. From the size and development of the fœtuses in the sacs there is little doubt but that they had reached full term when the rupture took place. Sufficient explanation for the causation of the rupture is found in the fact that four fœtuses were enclosed in one sac. Two of these were attached by their umbilical cords to the wall of the sac and within three or four centimetres of each other. The twisted condition of these fœtuses and of their umbilical cords would point to the conclusion that it was the impaction of their bodies which caused obstruction to delivery and consequent rupture. Although there is no evidence how this marked torsion was produced, we can come to no other conclusion than that it was caused in the course of labour by the uterine contractions. It is possible that the torsion was subsequently accentuated by the contraction of the inflammatory material which covered the fœtal sacs, and by the absorption of water from the fœtuses.

Previous work upon the subject.—It is unnecessary to refer in detail to the records of similar specimens of fœtal sacs which have been found in the peritoneal cavity, for these have been critically examined by Bland-Sutton and quite recently by Kamann. The view held by Bland-Sutton, that these sacs are not due to extra-uterine pregnancy, but to rupture of the uterus and extrusion of the fœtal sacs into the abdominal cavity, would appear to offer a full explanation of the phenomena.

It is well known that rupture of the uterus does occur in animals during labour, and that a not infrequent cause is a mal-presentation or the impaction of a fœtus which is too large to traverse the genital canal. The mother in some cases recovers, and examination of the uterus some months after the accident may show no obvious scar. Simonds was unable to find any cicatrix in the genital canal of a ewe twelve months after such a rupture. Without a most careful examination, both by dissection and microscopical sections, a former rupture of the uterus may be easily overlooked, and thus erroneous conclusions may be drawn.

That the fœtal sacs become encapsuled by an inflammatory exudate after their expulsion into the peritoneal cavity is shown by the experiments of Leopold. This observer placed fresh fœtal sacs in the peritoneal cavity of rabbits and found that in nine or ten weeks they were covered over with such a fibrinous capsule.

It is of interest, in connection with the torsion which was observed in some of the fœtuses which have been described in the present paper, to note that axial rotation of the gravid uterus has been observed in the ewe, cow, guinea-pig, cat, and hare. Bland-Sutton gives references to such cases; in some of these the torsion was so complete that one horn of the uterus was detached.

The specimens described in this paper have been presented to the Museum of the Royal College of Surgeons of England.

References.

Bland-Sutton.—'Surgical Diseases of the Ovaries and Fallopian Tubes, including Tubal Pregnancy.' London, 1896, p. 319.

Bland-Sutton.—'Journ. Comp. Path. and Therap.,' June, 1891. 'Journ. Comp. Med. and Vet. Arch.,' New York, 1891, vol. xii, p. 429.

Simonds.—'Trans. Vet. Med. Ass.,' 1842-3, vol. ii, p. 492.

Leopold.—'Arch. f. Gynäk.,' 1881, Bd. xviii, s. 53.

Kamann.—'Monatsschrift f. Geburt. u. Gynäk,' 1903, Bd. xvii, s. 588.

Pembrey.—'Obstet. Soc. Trans.,' 1898, vol. xl, p. 253.

Dr. Amand Routh congratulated Dr. Pembrey upon the complete proof his paper afforded of the accepted view that these cases were due to rupture of the uterus and escape of the unruptured fœtal sacs into the abdominal cavity, where they became partly mummified, their cyst walls and placenta becoming much thickened by deposition of fibrin. No such cases were observed in women, because if the uterus ruptured at or near full term the fœtus escaped through the rent without its membranes. He was surprised, however, that these changes had not been observed in some of the cases of tubal abortion where the entire ovum escaped into the peritoneal cavity. The only cases he knew of where such fibrinous coverings were seen were in cases of entirely detached subperitoneal fibroids, and where pseudo-cyst walls were developed round secondary abdominal gestations.

ACUTE INVERSION OF THE UTERUS: SPONTANEOUS REPOSITION.

By Robert Boxall, M.D., M.R.C.P.

On April 2nd, 1901, I was asked to see the following case in consultation with Mr. F. Gravely, of Newick, in Sussex.

Mrs. B—, aged 20, had been married twelve months to a bricklayer. She was delivered at term on Sunday, March 31st, at 2 p.m. Delivery of the child took place normally and occupied seven hours. She was attended by a practitioner who was well advanced in years, and was nursed by an old untrained countrywoman. This woman agrees with the patient in saying that after the birth of the child the doctor pressed very much on the lower part of the belly, but as the after-birth would not come away he then pulled strongly on the cord. This woman added that she thought she should learn something, but she saw more than she bargained for when the womb came outside with the after-birth attached. No bleeding took place till the accident occurred. The doctor removed part of the placenta and pushed the prolapsed mass back into the vagina, saying that he thought he had put it all right.

But, as the inversion had not been remedied and the bleeding continued, he handed over the case to Mr. Gravely, who saw the patient late on the evening of the same day. He found the patient at that time so much blanched from loss of blood that he gave saline injections *per rectum*, and, after giving a hot douche, endeavoured to replace the uterus, but without success. He at once took steps to obtain the services of a trained nurse.

In response to a telegram received from him, I saw the patient on Tuesday, April 2nd, at 3 p.m.—48 hours after the inversion had taken place. She was blanched, but

not deeply. No hæmorrhage was then taking place, nor had the discharge been excessive during the intervening time. Since 10 a.m. that day a fœtid smell had been observed. The temperature was 101° F. A tear had taken place through about one third of the perineum. The uterus was found to be completely inverted and was lying in the vagina. On examining the surface of the mass, the placental site was found in front and to the right, and on it were portions of adherent placenta and a piece of amnion at the back.

The rent in the perineum was washed and the vagina was douched thoroughly with 1 in 3000 sublimate solution. Under chloroform an attempt was then made to replace the uterus. For this purpose, the whole of one hand was introduced into the vagina and steady pressure was made on the inverted mass, combined with counter-pressure exerted by the other hand through the abdominal wall above the pubes. But the cervix remained closed and no impression could be made on it by the thumb through the abdominal wall. At the same time, by pressure from below, the whole mass was pressed up above the brim, until it seemed no longer safe to continue the pressure. No sign of yielding being apparent, it was consequently decided, for the time being, to discontinue the attempt at reposition, and to treat the case as one of chronic inversion at a later stage.

After repeating the douche, about 4 oz. of adherent placenta and membranes were removed, and the whole surface of the inverted mass was cleaned. Some bleeding followed, but was checked by hot douches, first of sublimate solution and then of plain water, till the loss nearly stopped. The whole surface of the inverted uterus was then packed with hot gauze wrung out in sublimate solution. The perineal tear was dressed separately in the same way. The packing was left for twenty-four hours, but the perineal tear was frequently redressed.

The patient was kept in bed for a month, till the discharge stopped, and, till that time, douches were given

regularly night and morning. The temperature reached normal at the end of the first week, but a week later, April 16th, at 8.30 a.m., it ran up with a rigor to 102°, and on the 18th reached 104°. From that time it gradually declined again, became normal on 22nd, and thereafter remained so. During the persistence of this febrile attack the patient lost rather freely, and after the red discharge stopped she had a good deal of whites. Her general health had improved, though she was still pale. I understand that she is naturally anæmic.

Six weeks after delivery, on May 14th, before being sent to London for further treatment, the patient was examined by Mr. Gravely. He found that the uterus had resumed its normal position. I saw and examined the patient on the following day. The uterus was then of the size of a seven weeks' gestation and the cervix was patulous, but it would not admit the index finger. The patient was still rather pale and sallow. Iron and salines were prescribed.

Seven weeks after delivery the periods were re-established. Marital relations did not occur till September. In December a miscarriage at two months took place. Some difficulty was experienced in the removal of the membranes, otherwise the patient made a good recovery. Fifteen months ago she had a child, and was delivered naturally. She is still pale but otherwise enjoys good health.

There are four points in connection with this case on which comment is invited—viz.: the rare occurrence of spontaneous reinversion; the date at which reinversion took place; the treatment adopted; and the action of the douche as a factor in causing reposition of the uterus.

1. *The rare occurrence of spontaneous reinversion.*—Spontaneous reposition of an inverted uterus is an exceedingly rare event. On that ground alone I judged the case to be of sufficient interest to lay before the Society. I hope that the publication of this case will induce others to record any similar experience, for I have

heard of the occurrence of similar cases. One case, and one only, is recorded in our 'Transactions.' In that case, which will be found in the tenth volume, reinversion occurred within a few hours of the accident, during the time that the doctor, having failed in his attempts at reduction, had gone to seek assistance. It differs from the one which I have related in that no considerable interval had taken place since delivery.

2. *The date at which reinversion took place.*—In the case which I have recorded no examination was made from the third day until six weeks after delivery. Hence it is impossible to draw any certain conclusion as to the date of the reposition of the uterus. But I am disposed to think that it took place in the third week after delivery, and that the febrile attack was associated with it. Moreover, I find, on referring to the daily notes made by the nurse, that at that time a certain amount of abdominal pain, as well as free red discharge, was present for some days. In the absence of other obvious cause for these symptoms, it is, I think, fair to infer that they were associated with the process of spontaneous reinversion.

3. *The treatment adopted.*—To abandon, for the time being, attempts at reduction under the circumstances which I have detailed seemed to me the wisest course to pursue in the interest of a patient already weakened by loss of blood and rendered already febrile by absorption of decomposed products, who at that time was not losing more than is usual after delivery. The immediate treatment was directed to cleansing, and keeping clean, the torn surfaces of the perineum and the surface of the uterus, and to prevent further absorption. Considering the facility with which reduction can be effected even in cases of long standing, I had every reason to hope that it would prove easy, and would, I thought, be associated with less risk if deferred for a few weeks. But I must confess that the possibility of spontaneous reduction did not enter into my calculations.

4. *The action of the douche as a factor in causing*

reposition of the uterus.—I am disposed to believe that the constant douching may have materially assisted the process of reposition. The dressing, applied to the uterus on the third day during the first twenty-four hours after the attempt which I made to reduce the inversion, was not applied with any idea of assisting reinversion, but solely as a means of checking bleeding from the surface and of keeping it clean. I feel confident that the vagina was not packed by the dressing in such a way as to have exerted sufficient pressure to produce reinversion at that time.

Dr. Galabin said that it was generally considered that if an inverted uterus could not be restored by taxis in the acute stage, it was necessary to wait for involution of the uterus in all cases before applying elastic pressure. In the last case, however, of inversion of the uterus which he had met with, he had found it quite practicable to restore the uterus with Aveling's repositor about a week after delivery, while the uterus was still very large. He decided on making the attempt because there was a good deal of sanguineous discharge continuing, but found that the ordinary largest cup slipped to one side, being too small to surround the fundus. He had another cup rapidly constructed, more than double the ordinary size. By means of this the fundus was pushed up within the external os. Then a smaller cup was substituted for it, and the reduction was completed within forty-eight hours, as it had been in every case of inversion of the uterus which he had yet met with.

Dr. Herbert Spencer had seen a similar case of spontaneous replacement of an inverted uterus, and Sir John Williams had informed him that he had seen a case of the kind. Spiegelberg, Bandelocque, and others had recorded cases, and there could be no doubt of its occurrence, although its possibility had been denied by some. He was generally in agreement with Dr. Boxall's remarks. If a recently inverted uterus could not be easily replaced, he thought it better to wait for two or three weeks and then to use Aveling's repositor. The uterus was very soft shortly after labour, and might easily be lacerated or perforated, and he considered it was especially bad practice to endeavour to replace the uterus while its mucous membrane was in a septic condition; drainage being free, it was far better to employ irrigation until the uterus was clean. His own case had been attended by a midwife, and he found many of these cases were attended by midwives and inexperienced assistants and very few by skilful practitioners. The midwife had left the uterus

inverted with a large piece of placenta and membranes attached for three weeks. He removed the putrid placenta and membranes, and employed continuous irrigation with boric acid solution. Under this treatment the fundus gradually receded, and in a few days passed within the cervix, and finally was completely reduced under the influence of the irrigation only. It had occurred to him that possibly the gentle continuous pressure of a stream of water would reduce a chronic inversion, although he had not tried it in any other case, being satisfied with Aveling's repositor. In using that instrument he thought it was important to employ a cup which accurately fitted the fundus, as mentioned by Dr. Galabin, and a stem with a proper curve; there was a warning to this effect in Dr. Aveling's own handwriting in a copy of Denucé's work in the Society's library. He thought some of the failures with Dr. Aveling's instrument might be due to want of attention to these details. With regard to the mechanism of spontaneous reduction he thought it probable that the gentle pressure of the stream of water had caused it in his own case, and perhaps in Dr. Boxall's, but in other cases of *sudden* reduction the explanation had been suggested that a violent effort, forcing down the vagina and its attachments to the cervix, might reduce the inversion by causing the round and other ligaments to pull up the fundus.

Dr. Boxall, in reply, said that he was so much impressed with the necessity of using an accurately fitting cup that in two cases with which he had had to deal he had made a mould of the inverted fundus. For that purpose he used a piece of hard bar soap, which had the advantage of being always available. From that model a cup was shaped out of pitch pine. When applied this accurately fitting cup adhered by suction to the inverted fundus, and was thus prevented from slipping. Being made of soft wood, the cup was much more easily removed from the uterus after reinversion was effected, because it could be seized and, if necessary, broken up by forceps with greater ease than a cup made of ebony or vulcanite. In another case, he had, before applying the repositor, attached a stout ligature to the margin of the cup; the stem also was made to screw into a hole which ran through the bottom of the cup. By unscrewing the stem the reinverted fundus was relieved of the suction action of the cup, and by dragging on the ligature the edge of the cup was brought down to the cervix and delivered. In one of these cases he had seen much damage done by Aveling's repositor, which had slipped and, by pressure, caused ulceration at the roof of the vagina, and the patient had nearly lost her life from hæmorrhage. This unsuccessful attempt was made a fortnight after delivery. On that account he preferred to wait till involution was further advanced.

OCTOBER 5TH, 1904.

EDWARD MALINS, M.D., President, in the Chair.

Present—31 Fellows and 1 visitor.

Books were presented by the Madras Government Maternity Hospital, the Gesellschaft für Natur- und Heilkunde in Dresden, the Copenhagen Medical Society, and by Drs. Galabin, Cullingworth, Steele-Perkins, and Sir James Sawyer.

The following candidate was proposed for election:—Frederick William Forbes-Ross, M.D.Ed., F.R.C.S.Eng.

The following gentleman was elected a Fellow of the Society:—Thomas Rose, M.R.C.S., L.R.C.P.

SECTION OF THE WALL OF AN OVARIAN DERMOID SHOWING GIANT CELLS.

(With Plate VIII.)

Shown by Dr. HERBERT WILLIAMSON.

THE occurrence of large giant cells in the walls of ovarian dermoids is a phenomenon which has received, in this country, very little attention. I have, however, so frequently found them present that I venture to bring forward a specimen to-night, in the hope of learning more

than I at present have been able to find out with regard to their origin and significance.

The examination of a considerable number of so-called dermoid cysts of the ovary has convinced me that these structures cannot be explained on the theory of epiblastic inclusions, and that dermoid cysts of the ovary differ in many material respects from dermoid cysts found in other parts of the body.

Wilms and Pfannenstiel, working independently, have reached almost the same conclusions, and have shown that ovarian dermoids consist of two parts—(1) an embryonal rudiment in which, upon careful examination, one can usually demonstrate derivatives of all three layers of the blastoderm, and (2) of a cyst in which this rudiment is growing.

The embryonal rudiment sometimes forms a marked projection or nipple-like process on the wall of the cyst, sometimes it is so compressed and incorporated with the wall that it can only be discovered by microscopic examination. Covering this rudiment, and a portion of the cyst wall immediately surrounding it, is an area of skin from which spring many hairs. I would specially direct your attention to the fact that the whole extent of the cyst wall is never lined by skin, and in most cases over only a very limited portion of it can dermal structures be found.

The rest of the cyst wall is smooth and covered by a dense granulation tissue containing giant cells, cholesterin plates, hairs, and young connective-tissue cells.

As to whether the cyst or the embryoma is the starting point of the tumour it is not my intention to enter into any discsssion to-night. I simply wish to draw your attention to the section I have placed under the microscope illustrating the structure of the non-embryonal portion of these cysts.

The section shows very clearly that the wall is composed of three layers :

1. *An outer,* which consists of ovarian tissue, apparently normal in every respect. Ova cannot be demonstrated,

Section of the inner layer of the wall of a dermoid cyst of the ovary, showing hairs with giant cells clustered around them. × 100. Illustrating Dr. Herbert Williamson's specimen of ovarian dermoid.

Adlard & Son, Imp.

but as the patient was forty-nine years of age this is of no pathological significance. The inner portion of this layer represents the medulla of the ovary, and is very vascular.

2. *The middle layer* consists of dense fibrous tissue arranged in bundles composed of wavy fibres, and is lined by—

3. *The inner layer,* the cells of which are of the connective-tissue type, but present a very great variety in form and size. They are many layers deep, and after staining with eosin and hæmatoxylin exhibit a curious yellow-brown colour; some of them are small, rounded, and possess a single nucleus, some of them are enormous, and contain as many as twenty nuclei. Scattered amongst them are patches of small round inflammatory cells, and lying between them are portions of a number of hairs; no hair-roots or follicles are to be seen.

I would especially direct your attention to a point which is well seen in both the section and the drawing, viz. that the large giant cells are chiefly found clustered around the hairs. The question which I wish to raise is the significance of this inner layer with its giant cells.

The embryonal portion of this tumour contained typical thyroid tissue, and was covered by the usual layer of skin, from which grew a quantity of long black hair. In the non-embryonal part of the cyst no hair follicles are found; the hairs are merely embedded in the inner layer of the wall, and my own view is that this inner layer has arisen in response to the irritation which the hairs have produced. The characters of the cells, and particularly of the giant cells, resemble very closely those of the tissue which we find surrounding a foreign body, a ligature, a needle, or a splinter of wood which has been for some time embedded in living tissues.

CARCINOMA IN THE MUSCULAR WALL OF THE UTERUS SECONDARY TO CANCER OF BOTH OVARIES.

Shown by Dr. Cuthbert Lockyer.

In June of this year Dr. Cuthbert Lockyer showed a case of what he regarded as primary carcinoma of both ovaries, in which both Fallopian tubes, though apparently healthy, were found on microscopical examination to be secondarily involved in the carcinomatous process. The invasion of cancer cells was traced from the ovaries through the mesosalpinges to the tubes.

Dr. Lockyer remarked at the time that "the condition of the tube (which should have read *tubes*) raises the important question as to whether the uterus itself might not be likewise involved in secondary growth, and if this can be shown to be the case the correct treatment would include not only the removal of tubes and ovaries, but also total abdominal hysterectomy."

The patient died a few weeks after the above remarks were made, and, by the courtesy of Dr. W. J. Maurice, Dr. Lockyer has had an opportunity of examining the uterus and structures connected with it, obtained for the purpose by post-mortem examination. The parts removed consist of the uterus, upper portion of vagina, and an adherent piece of small intestine. The latter is firmly attached to the left cornu and back of the fundus uteri. It is sharply kinked upon itself, and at the bend is much thickened in all its coats. On section the lumen is seen to be nearly, if not entirely, obliterated at this spot; the reason for not being certain as to whether total obstruction has taken place lies in the fact that the tissue occupying the lumen is very soft, friable, and brain-like, and a probe passes through it without the least resistance. The fact that the proximal part of the bowel contained a

lot of thick creamy pus favoured the idea that the obstruction was complete. A portion of this thickened bowel wall was taken for microscopical examination.

The uterus was atrophied and very hard. Sagittal sections were made through the body so as to include the cavity at the entrances of both Fallopian tubes.

The thickening in the adherent small intestine showed the presence of a columnar carcinoma—a growth arising in the cells lining Lieberkühn's follicles. This had invaded the muscular wall, in which it had set up much inflammatory reaction; the carcinoma had not reached as far as the serous coat of the bowel, it was clearly travelling from within—out and not *vice versâ*.

The uterine sections from either cornu both showed the presence of an invasion of the perivascular lymphatics by a glandular carcinoma, the cells of which resemble in all their features those seen in the cancerous ovarian growths, and in the tubal metastases. It was noticeable that the mucous membrane of the body of the uterus was not the seat of growth, either primary or secondary.

The invasion of cancer which spread from the ovaries *viâ* the broad ligaments and tubes to the uterus stopped short in the uterine muscle. The channels selected were, as one would expect, those well-defined lymphatics which accompany and run the same anatomical course as the larger blood-vessels. These lymphatics were filled by malignant emboli, and the latter, as was the case with those in the tubes, were practically confined within the walls of the lymph-channels. No destruction or disruption was to be seen in the muscle-tissue around, nor was there any great reaction of an inflammatory character visible in the fibro-muscular wall of the uterus. These facts are explained by the rapidly fatal issue of the case, no time having been afforded for the metastases to grow and develop in the muscularis uteri.

The above investigations on the state of the uterus proved Dr. Lockyer's original supposition to be correct, and showed that it is no use to remove the ovaries only,

when both these organs are the seats of malignant disease. The entire pelvic genitalia must be cleared out, even when tubes and uterus appear normal.

The presence of a small growth in the bowel, localised to the site of its adhesion to the uterus, raises a further therapeutical problem. In the first place, the coincidence of malignant disease of the ovaries and bowel places this case in the same category as the seventy-nine cases recorded by Schlagenhaufer ('Monatsch. für Geburts.,' April, 1904, p. 485).

The writer collected seventy-nine cases of malignant diseases of both ovaries, and found that in sixty-one of these there was present cancer of the stomach, in ten cancer of the bowels, in one cancer of the bile-duct, in one cancer of the supra-renal gland. He does not regard the alimentary and genital growths as mere coincidences, but looks upon the latter as secondary to the former.

The surgical deduction to be made from such a conclusion obviously is, to regard bilateral malignant disease of the ovary as inoperable and hopeless unless the invariable alimentary growth (which may have been overlooked hitherto) can be found and dealt with. If Schlagenhaufer's view is correct, it would be no more logical to remove bilateral malignant ovarian tumours than to remove malignant axillary glands and leave behind a primary cancer of the breast. But Dr. Lockyer was inclined to regard such cases as the one at present under consideration as an example of coincidence, especially since the columnar cancer of the bowel bore no points of structural resemblance to the spheroidal-celled cancer of both ovaries.

The small size of the growth in the bowel and the very considerable bulk of both ovarian growths might be regarded by some to favour the view that the ovarian growths took priority as to date of origin, but inasmuch as it is well known that bowel carcinomata often run a very slow course Dr. Lockyer thought that this point was impossible of proof either way, and inasmuch as he

regarded the two foci of disease as quite separate, distinct, and independent, the question as to which arose first lost much of its importance.

In conclusion the speaker stated that, after careful survey of all the facts afforded by the study of this important case, he regarded carcinomatous disease of both ovaries as a very serious type of malignancy, but one which, although frequently associated with cancer elsewhere—especially along the alimentary tract—was nevertheless not necessarily a metastasis, but rather an independent coincidence, and therefore it was right and proper to cope with it by the radical method of removing all the tissues likely to be involved, namely, ovaries, tubes, and uterus. It was scarcely necessary to add that every means should first be taken to discover the state of the gastro-intestinal tract as the frequency of coincident growth in this situation is sufficiently striking.

CANCER AND FIBRO-MYOMA COEXISTING IN THE BODY OF THE UTERUS.

Shown by Dr. Handfield-Jones.

Dr. Handfield-Jones showed a specimen, in which both fibro-myomata of the uterine body and cancer of the body were present. The patient was an unmarried woman, aged about forty-two. There was a long history of menorrhagia, for which curettage had been performed. The latter operation had led to healthy menstruation for about two years. Then the excessive menstrual loss had begun again.

A later curettage had shown the presence of glandular carcinoma in the body of the womb. The first attempt at extirpation of the uterus had been abandoned owing to the presence of thickening in the lower part of the

broad ligament. Four months later the uterus had been extirpated, and the patient was at present alive and well without any sign of recurrence of the disease. The early age at which cancer of the body of the womb had arisen, and its co-existence with fibro-myoma, were discussed.

Attention was called to the mild character of the malignant disease, as shown by the slow progress of the mischief and the absence of extension at the time of the second operation.

Dr. Herman said he had seen cases in which cancer was present along with fibroids. His impression was that the relations between cancer and fibroids was merely one of coincidence: that fibroids neither protected a patient from cancer nor caused her to be liable to it. He had seen cancer of the body at an earlier age than forty.

Dr. Cullingworth said that recent experience had served to throw considerable doubt on the correctness of the current view that cancer of the body of the uterus was rare. He was strongly of opinion that it would prove to be much more common than had been supposed. It was also becoming evident that the presence of fibroids afforded no presumption against the existence of malignant disease. It would be interesting to determine whether the co-existence occurred more frequently in cancer of the body or cancer of the cervix. His own impression was that it would be found to be more frequent in the former. An instance of cancer of the body of the uterus in a patient under forty would be found in the speaker's recently published Ingleby Lectures ('Journ. of Obstetrics,' July, 1904), where the case is described of a patient aged 33.

Dr. Herbert Spencer had met with carcinoma of the uterus in conjunction with fibroids in four or five cases. He had published one of these in the last fasciculus of the 'Transactions.' In that case cancer of the body with fibroids occurred in a woman aged 36. That was the youngest patient in whom he had met with cancer of the body, but it had been observed by others in much younger patients, even at as early an age as twenty-one.

FIBROID OF THE UTERUS WITH CYSTIC DEGENERATION OF THE SURROUNDING TISSUES.

Shown by Dr. Handfield-Jones.

Dr. Handfield-Jones also showed a specimen of fibro-myoma of the uterus, which was complicated by the presence of cystic change in the surrounding structures. Thus there was a large cyst of the left ovary combined with a hydrosalpinx of the left tube; also there was a hydrosalpinx of the right tube; and a large, thin-walled, broad ligament cyst in the right broad ligament. Again, the peritoneum over the lower part of the uterus on its anterior aspect was raised into large bullæ by the presence of collections of watery fluid beneath the membrane. The question of lymphatic obstruction on a large scale was raised and discussed.

Report from the Laboratories of Pathology and Public Health.

The endometrium is the seat of a malignant growth of the type known as adenoma malignum. It is composed, that is, of tubular processes which are branched, and which have eroded the muscle-walls of the uterus. Some cancer cells can be found wide of the growth, lying in deep lymphatics in the muscular wall.

The interstitial growth ordered to be cut and examined is a simple fibro-myoma which has undergone very extensive hyaline change. The subperitoneal tumour is also a simple fibroid, the tissues of which are fairly normal, but which show some signs of œdema, the tissues being in places lax and reticular.

C. L.

The specimens were referred to the Pathology Committee.

Dr. Cullingworth hoped the attention of the Pathological Committee would be specially directed to the possibility of the specimen being one of tubo-ovarian cyst. So little was known as to the mode of formation of these cysts, that no opportunity of obtaining any fresh light on the subject should be lost. Hence he would suggest that the examination of the specimen should commence by ascertaining whether any direct communication exists between tube and ovary.

CERTAIN DETAILS REGARDING THE OPERATION OF CÆSAREAN SECTION IN CASES OF CONTRACTED PELVIS, BASED UPON A SERIES OF THIRTY CASES.

By J. M. Munro Kerr,

OBSTETRIC PHYSICIAN, GLASGOW MATERNITY HOSPITAL.

(Received May, 1904.)

(*Abstract.*)

The author considers first the maternal mortality, which in his own cases, with two deaths, works out at 6·6 per cent. He then considers morbidity, as based upon a temperature of 100·5° on more than one occasion, and finds it is 26 per cent. The two fatal cases are detailed. In one the patient died on the fifth day; the post-mortem examination revealing the existence of septic peritonitis. In the other the patient died the day after operation of collapse. At the post-mortem examination a large quantity of blood was present in the abdominal cavity, and two or three of the uterine stitches were found untied.

The author then discusses the three different methods of treating the uterus after removing the child:—(*a*) Removal of the uterus by supra-vaginal hysterectomy; (*b*) Retention of the uterus and sterilisation by resection of the tubes; (*c*) Retention of the uterus without sterilisation—the conservative Cæsarean section. From the statistics of himself and others he comes to the conclusion that the best results are obtained by supra-vaginal hysterectomy; there is little time for preparing patients for operation.

The arguments for and against the conservative operation are considered—(*a*) From the ethical standpoint; (*b*) from the

standpoint of the danger to the patient of the repeated operation; (*c*) from the standpoint of the danger of rupture of the uterus in a subsequent pregnancy. From a full consideration of these, he believes that with patients who come under one's care before labour, the conservative operation in a large number of cases is indicated.

Finally, such matters as the preparation of the patient, the time for operating, the controlling of hæmorrhage, and the suturing the uterus are briefly referred to.

In bringing forward this subject of Cæsarean section in contracted pelvis to-night my purpose is not to describe each case of the series of thirty upon which I have operated, but rather to consider certain details of the operation regarding which there are still differences of opinion amongst obstetricians. I have thought it advisable, however, to send round cards with a brief synopsis and temperature chart of each case.

The first matter upon which I wish to touch is the mortality and morbidity from the operation. This subject was gone into very fully by Galabin at the Annual Meeting of the British Medical Association in Manchester in 1902, and I think, on the whole, most of us were disappointed that, on his showing, the results of the operations in England were not better. Harris, and so far as I know there are no later figures than his, gave the English mortality in 1894 as 32 per cent. Since then it has fallen, of course, much below that figure. In the Glasgow Maternity Hospital, for instance, from 1891–96 it was 38 per cent., from 1896—1901 it fell to 20 per cent., and at the present time it is probably less than half that figure. My own cases, as I have said, number thirty, with two deaths, a mortality of 6·6 per cent. Williams, in his recent text-book, states that in 335 operations performed by Chrobak, Schauta, Leopold, Braun, Olshausen, Zweifel, Reynolds, Bar, Charles, and Chagrin there were only twenty-three deaths, a gross mortality of 6·8 per cent., a percentage practically the

same as mine. Olshausen's latest results (1887—1902) are sixty-two cases, with a mortality of 8 per cent.

As already mentioned, I have had two fatal cases. One was most unfortunate, for it might have been avoided. The patient (Case 12), some eight hours after the operation, showed signs of great collapse. Unfortunately I could not get to see her, as I was engaged with an eclamptic, to whom I had been called in consultation. One of the staff, however, saw her, but did not consider the collapse due to internal hæmorrhage, and naturally did not open up the abdominal wound. At the post-mortem examination about twenty ounces of blood were found in the abdominal cavity, and two or three of the catgut uterine sutures were untied. I, doubtless, cut the sutures too short, and, with the alternate contractions and relaxations of the uterus, they must have worked loose. I shall have a word or two to say later about the material for suturing. The patient died as a result of faulty technique—but even that might have been remedied had the abdomen been opened when the collapse occurred.

In the other fatal case (Case 11) death resulted from septicæmia. The patient had been in hospital only a few hours before operation. If you look at the temperature chart you will see that there was no fever. The only symptoms were intestinal paralysis and rapid pulse. At the post-mortem examination there was general peritonitis, and the infection had evidently extended from the uterus.

But although there was only a mortality of 3·7 per cent. attributable to septic disturbances, one or two patients gave me considerable anxiety. Case 5, who had double mitral disease, suffered greatly from bronchitis and dyspnœa for some days after the operation; Case 29 had pleuro-pneumonia; Cases 3 and 18 had intra-uterine douches on account of fœtor of the lochia, and Case 25 had double parotitis. In Case 23 I made deep incisions into the cellular tissue behind and to the right side of the uterus. Briefly her history is as follows:—Mrs. McC—, a primipara, with a generally contracted, flat rachitic

pelvis (C. D. three and a quarter inches), was admitted to the Maternity Hospital with the os fully dilated and the cord prolapsed but pulsating. I delivered a live child by Cæsarean section, and afterwards amputated the uterus, treating the stump retro-peritoneally. She remained very well for the first three days, but after that she developed a high temperature, rapid pulse, and tympanitis. So ill was she that on the ninth day I considered her condition quite hopeless. As, however, there seemed to be some fulness behind and to the right side of the cervix, I made deep incisions into the cellular tissue, but without finding any pus. Within twenty-four hours, however, a free purulent discharge appeared. The patient made steady improvement from that time, and she and her baby left the hospital perfectly well.

If one takes morbidity as represented by a temperature of 100·5° or over on more than one occasion, I find eight cases in which such a state of matters existed, that is to say there was a morbidity of 26·6 per cent. Four of the cases had been in hospital, and were carefully prepared before operation, but four were operated upon immediately after, or very shortly after, admission. Theoretically, if the preparations for operation are perfect, no patient should become septic who has been in hospital for any time before operation. But the vagina is a very difficult canal to cleanse, and there is not the least doubt that it contains in a considerable number of cases organisms of a very virulent character. I say this with full knowledge of the most valuable investigations on the bacteriology of the vagina made by Dowülein, Menge, and others. Leopold has emphasised the great danger of gonococci. I was recently very much struck with the virulence of this organism in the puerperium in the case of a young woman who had a simple and spontaneous delivery of child and placenta. She was never examined vaginally, yet she developed so grave a septicæmia that she died. In the discharge taken from vagina and uterus pure cultures of gonococci were found. In all my cases, there-

fore, I wash out the vagina very carefully, and in most of the cases I do the cleansing and douching myself immediately before operating.

The second matter which I wish to discuss is the treatment of the uterus after the child has been removed. There are three different courses open to one after extracting the child:—(1) Removal of the uterus by Porro's operation or supra-vaginal hysterectomy with intra- or retro-peritoneal treatment of the stump. (2) Retention of the uterus, but sterilisation of the patient by resection of the tubes. (3) Retention of the uterus without sterilisation—the true conservative Cæsarean section.

Each of these methods has its advantages. Not to go further than our own country, one finds Duncan, Routh, and Targett advocating the first; Cameron and Horrocks the second; Galabin, Sinclair, Spencer, and Wallace the third. With such differences of opinion amongst leading obstetricians, it is pretty safe to conclude that the truth rests not with one individual or one group.

(1) *Removal of the uterus by Porro's operation or by supra-vaginal hysterectomy with intra- or retro-peritoneal treatment of the stump.*—Everyone admits that Porro's operation for some years after its introduction gave the best results. It fell out of use, however, more especially in England, after Kehrer, Sänger, and Cameron described their methods of stitching the uterus. Removing the uterus has always been much favoured by continental operators, and is still extensively employed, although not as Porro described it, for most surgeons now treat the stump intra- or retro-peritoneally.

What is the position of the matter in Great Britain? At present you have Cameron protesting, as he did at the Manchester Meeting of the British Medical Association in 1902, "against the appalling frequency of hysterectomy along with Cæsarean section as advocated by some members of the London Obstetrical Society." While, on the other hand, you have Duncan reported as saying, at the July meeting of the Obstetrical Society in 1900, "that

abdominal hysterectomy with intra-peritoneal treatment of the stump was much less dangerous than any Cæsarean section." There you have two absolutely different views, and the question to decide is which of the two is correct?

Taking my own results first, I find twenty-three cases with retention of uterus and two deaths, a mortality of 9·8, and seven cases of hysterectomy with retro-peritoneal treatment of stump with no deaths. Looking at the morbidity, I find with the former it is 28 per cent., with the latter 25 per cent. Further, an examination shows that the hysterectomy cases were complicated, just the cases one would have expected might have had a fatal termination. In three there were extensive adhesions, in two probable infection before admission. I cannot but come to the conclusion, therefore, that hysterectomy is, in a great many cases, the safer operation. Leopold, in his report of 100 cases, gives his total mortality with the conservative operation as 9·8 per cent., and after hysterectomy as 10·3 per cent., but his reduced mortality as 5·8 per cent in the former and 3·7 per cent. in the latter. Braun von Fernwald, in seventy-four cases, gives his mortality as 11·8 per cent. and 5 per cent. respectively. The latter author says the smallest mortality occurred in the operations where the uterus was removed. He considers it, therefore, the safer method. If you take 268 cases reported by Leopold, Braun, Schauta, and Kerr, the conservative operation gives a gross mortality of 10 per cent., and hysterectomy a mortality of 8 per cent. Routh's and Duncan's claim, therefore, that hysterectomy is safer than the conservative operation must, I think, be admitted. The error they have made, and more especially is this the case with Duncan is the advocating of the routine performance of hysterectomy.

The reason why hysterectomy gives the best results is because one has so often to operate on patients hurriedly prepared, and, indeed, not infrequently infected before admission to hospital. Should conditions improve, however, should our patients come to us or be sent to us

earlier, as we hope will be the case in the future, we shall be able more and more to give up hysterectomy, and have recourse to the ideal operation of conservative Cæsarean section. At the present time, and with our present knowledge, we are only justified in doing this in certain cases.

(2) *Retention of the uterus and sterilisation by resection of tubes.*—This method has its chief supporters in this country in Cameron and Horrocks. It has this advantage that it is an easier operation than hysterectomy with intra- or retro-peritoneal treatment of the stump. (It is not easier and certainly is slower than Porro's operation, but the latter has in this country been very largely given up.) It is an operation specially suited to practitioners who have not had experience of abdominal surgery; we would therefore recommend it to those who are suddenly called upon to perform the operation of Cæsarean section in out-of-the-way country districts and without efficient assistants. In hospital practice, on the other hand, if the patient is to be sterilized it is in most cases better to remove the uterus. There is, however, one reason which I think might justify sterilization by cutting and tying the tubes, and it is this that, if at a future date the woman wished to have the chance of another pregnancy, one might perform abdominal section and unite the two ends of the tubes together again. Here are two cases in illustration. A patient who had been sterilised as described came to me in great distress because her child had died. I told her I could do nothing for her, but it occurred to me afterwards that I might have suggested the procedure I have mentioned. Some months later I did suggest the procedure to another patient who had been sterilised after a craniotomy by a colleague, but she would not submit to the operation. Now, such a procedure is quite feasible provided one simply cuts and ties the tubes, for the tubes remain patent after tying and cutting, as I have seen in two cases in which the abdomen was opened on a subsequent occasion. That is the

reason why one can never be sure of sterilising an individual by such treatment. It is, however, so rarely that pregnancy follows that one may consider it a satisfactory method. If, however, one cuts the tubes and covers over the uterine ends with peritoneum then the operation of anastomosis would be more difficult.

(3) *Retention of the uterus without sterilisation—the true conservative Cæsarean section.*—This is the ideal operation. It is the operation which, as far as one can judge at present, will come more and more into vogue, and it is no small satisfaction to have amongst the Fellows of our Society two of the pioneers of this method, viz. Sinclair and Spencer. The latter has for many years been speaking against sterilisation.

With regard to the sterilising of patients after Cæsarean section there are three matters for consideration—(1) the ethical question ; (2) the danger to the patient of the repetition of the operation ; (3) the danger of rupture of the uterus in a subsequent pregnancy.

I must admit to being rather diffident about discussing the matter of sterilisation from the ethical standpoint. It is, indeed, a very subtle subject, although one which might quite profitably be considered this evening. It is not quite correct, as some enthusiasts for the conservative operation have done, to place sterilisation in the same category with, say, the repeated performance of craniotomy or abortion, for in each of these operations one actually destroys a living fœtus. It is much more on a par with the practice of those who give advice regarding the means to be used to prevent conception to patients suffering from some organic disease. All of us refuse to give advice unless we are convinced that pregnancy will seriously injure the patient's health or unduly endanger her life. If, however, a young married woman, say, with serious chronic heart disease, consults us, we caution her against becoming pregnant—we tell her and her husband that there should be no sexual intercourse. From the ethical standpoint we should say no more, but we know it

is seldom that such advice is followed, and so we inform such patients of the preventatives to pregnancy which may be employed. Some may say we are not justified in doing so, but I would only ask these men if they would refuse to empty the uterus should such a patient's circulation become seriously embarrassed by a pregnancy. Now, the position of a man who gives advice regarding preventative means to pregnancy in serious heart cases and the position of him who advocates and practises the sterilisation of the patient by resecting the tubes is very similar, and I think they are each perfectly justified in taking up the positions they do. A most interesting discussion on this question is reported in the 'Transactions of the American Gynæcological Society' for last year (vol. xxviii, 1903). It followed the reading of a paper by Green on "Repetition of Cæsarean Section on the same Patient; the Experience of the Boston Lying-in Hospital." Green took up a very strong position. The following are the words with which he closed his paper: "I venture to assert that the only safe and moral ground for the medical profession is that based on modern medical science, uninfluenced by sociological considerations. If a woman comes to Cæsarean section and recovers, she and her husband, if she has one, should be informed of her condition and of the prognosis and treatment in the event of future pregnancy; if subsequent pregnancy ensues, the responsibility of treatment rests with the obstetric surgeon; but the responsibility for the condition rests elsewhere." Whitridge Williams distinguished between "pauper patients" and "women in the upper walks of life." As regards the latter he is reported to have said, "I do not believe we are justified in allowing pauper patients to be subjected to repeated Cæsarean section unless they particularly desire it." As regards the others he is again reported to have said "that they should be made to share the responsibility with the physician. In such cases the husband and wife have the right to demand sterilisation, though I should

earnestly dissuade them from it after the first operation, and point out to them the possibility of a subsequent death of the child and the absolute impossibility of having another after such an operation. If, however, the patient required a second operation, the matter should be left almost entirely in her hands; but my advice would tend in the direction of rendering her sterile at that time, as no matter how favourable our results may be an occasional death is bound to occur."

Personally, I think that, with results from a primary operation such as I have given, we are not only justified but compelled, judiciously, to expand the field of operative interference. In the days when the mortality from the operation was 20, 30, or 40 per cent. it was not right to subject a woman to a second or third operation, but with a mortality of 7 or 8 per cent. the question has been entirely altered, and particularly is this the case when we know that the percentage mortality in repeated sections is appreciably lower than in first. I have said we should judiciously expand the field of operative interference; everyone must decide for himself what is judicious expansion. I can only give you my own personal and present feelings on the matter; they are as follows :—(1) A patient should be sterilised by hysterectomy if labour has been in progress for long, or if there is the probability of her having become infected. (2) A patient should be sterilised, and preferably by hysterectomy, if she has any organic disease such as valvular disease of the heart, or if she is, constitutionally, very delicate. (3) With the good results now being obtained by Cæsarean section, and especially in cases where the operation is repeated, strong, healthy, uninfected parturients should not be sterilised. (4) As regards how often the operation should be repeated that is a matter which at present must be decided by patients and their medical advisers. I am, however, inclined to agree with Whitridge Williams that if a patient has undergone the operation twice or thrice she should be sterilised.

The danger of repeated Cæsarean section has been gone into so fully by Wallace that it is quite unnecessary to take up much time in considering it. Wallace says, "Taking into consideration sixty modern cases Cæsarean section was performed twice in each of forty-three cases, three times in each of fifteen cases, four times in one case, five times in one case." The mortality in the sixty cases works out at 9·5 per cent. Without attempting to collect all the cases since Wallace's paper I have found that Green has reported nine cases, while in my list there are two. Besides these I have found reported eight single cases, which makes in all nineteen. Amongst them there was only one death reported by Green, which reduces the mortality to 6·3 per cent. One might raise this objection that successful cases are most generally reported, but if you look at the table in which only operators who have reported series of cases are mentioned you cannot fail to be struck with the fact that the repeated operation shows a very small mortality indeed. Wallace has gone into the question of adhesions most carefully, and Spencer, Sinclair, Braun, and others have pointed out the value of such. Personally, I am in entire agreement with Wallace. In the two cases in which I have repeated the operation, on both occasions adhesions to the anterior abdominal wall were most extensive. In a case where the uterus ruptured —not included in my list, but described and shown to-night—there was only a massive fibrous band and a tag of omentum attached to the anterior wall below the fundus. In one of the cases I employed Fritsch's fundal incision, and in one the anterior longitudinal incision. Green's experience in his nine cases is practically the same, in only one case were there no adhesions. Undoubtedly it is most desirable to operate extra-peritoneally if possible, and consequently I am quite in agreement with Sinclair and Wallace in doing everything to favour the formation of adhesions. In stitching the uterine wound, however, after a second operation, the edges of the wound should be separated all round.

In bygone days, when careful suturing of the uterus was not carried out, the accident of rupture through the scar was by no means uncommon. It is now generally considered that such a danger need hardly be reckoned with, especially amongst those who are strong advocates of the conservative operation. Personally, I have experience of the occurrence in one of my cases, and you see on the table the uterus referred to. The patient was admitted for a second Cæsarean section about three weeks before term. The night of admission she complained of slight abdominal pain after an enema had been administered. The pain, however, did not prevent her sleeping soundly. In the morning there was still slight pain, and this gradually increased until it became, finally, pretty severe. There was no collapse, and the pulse did not register more than 86. I performed abdominal section and found the child in the ruptured membranes, and with the placenta attached free in the abdomen, the uterus with the rent through the old cicatrix being retracted and lying down behind. I removed the child, membranes, and placenta, then performed supra-vaginal hysterectomy, and treated the stump retro-peritoneally. The patient made an excellent recovery—I may say that I performed the previous Cæsarean myself, and employed the fundal incision. On the present occasion on opening the abdomen there were only a few adhesions of omentum to uterus. The bowel was not adherent to the uterus.

Having taken up the whole subject of rupture through former Cæsarean section cicatrices in a separate paper, which will shortly appear, I would only mention that I have found, in the recent literature, cases reported by Targett, Galabin, Guillaume, Woyer, Everke, and Meyer, a fairly good number considering how few repeated operations have been performed. But, in addition, it must be remembered that several operators—Korn and Bar for example,—at the subsequent operation, have referred to the great thinning of the uterine cicatrix, and Smyly speaks of the uterine cicatrix being so thin that it gave

way to the pressure of the thumb. Probably the most curious case of all, and one which, of course, was only indirectly associated with the previous operation, was the case recorded by Abel, where the posterior uterine wall ruptured, presumably because it became overstretched. It is perfectly evident, therefore, that the danger of rupture is a very real one, consequently, if the patient is not sterilised, the uterine wound must be very carefully stitched, good union obtained as far as possible, and she must be very carefully watched during any subsequent pregnancy. I certainly think that a most important preventative to the accident is the formation of extensive adhesion to the anterior abdominal wall, and I quite agreed with Wallace and others who advocate that steps should be taken to insure such an occurrence.

There are several other details which, had time permitted, I should have liked to have discussed to-night. Amongst these may be mentioned the preparation of the patient, the time for operating, as to whether the uterus should be opened into before or after being turned out of the abdomen, the controlling of the hæmorrhage from the uterus, and the suturing of the uterus. As, however, the full consideration of these questions would occupy too much time, I can only give you briefly my own practice and experience.

I cleanse not only the abdomen in the ordinary way with soap and water, turpentine, alcohol, and carbolic dressing, but I make a point, and, as I said before, I attach great importance to this, of washing very carefully, not simply douching out the vagina. I employ $\frac{3}{4}$ per cent. lysol for this purpose. During the operation I use only normal saline solution for my hands and swabs. I never use sponges. The swabs are never rinsed and used twice, for that necessitates employing another nurse. I find 50 are required for an operation. One nurse removes the swabs from the dura and rinses them out of saline solution, another attends to the instruments, and my assistant is the only other one who comes directly into

contact with the patient. It is a decided advantage to limit as far as possible the number of those directly taking part in the operation.

I have no hesitation in operating upon multiparæ before labour has started; also in primipara if hysterectomy is to be performed it is always better to operate then, for the stump to be stitched is small. Where, however, the conservative operation is to be performed I now always wait until labour has started, for I have twice seen trouble, once very considerable trouble, follow the operation performed before labour, from the retention of blood-clots in the uterus.

The fundal incision of Fritsch I do not think an advantage except when hysterectomy is to follow. In such cases, however, as it allows more easy extraction of the child I usually employ it.

The hands of the assistant used in any of three ways indicated in the diagrams I have always found quite sufficient for the purpose of controlling hæmorrhage; only once have I seen the uterus remain absolutely atonic and refuse to retract. As will be seen from the report I performed supra-vaginal hysterectomy in that case.

I frequently turn the uterus out of the abdomen before opening into it, but often I do not do so. With intact membranes it is no matter which one does, but if the membranes have been ruptured before operation, and especially if there is any possibility of the amnionic sac having been infected, then the uterus should be turned out first of all.

For suturing the uterus there is no doubt catgut is the best material. Although silk is the pleasanter to work with, and can be more easily sterilised, it has this great disadvantage that if by any chance it becomes infected during convalescence a troublesome discharging sinus results. In two cases in which I used silk this followed, and in one case operated upon some months ago the patient has still a discharging sinus.

As regards the children all except one (Case 2) were extracted alive, but one (Case 5) died in hospital; thus the gross fœtal mortality is 6·6 per cent., precisely the same therefore as the maternal. Many of the children when born were asphyxiated, but as there is always a house surgeon ready to take charge of them no time is lost in resuscitating them.

Case 1.—Mrs. L—, aged 33 years, 3-para; 1 and 2 craniotomy. Admitted March 15th, 1901, with os fully dilated and membranes ruptured. Generally contracted rachitic pelvis, C. D. 3¾ inches. Conservative Cæsarean section; tubes cut and ligatured. Child 7 lbs., alive. Placenta posterior wall. Recovery uninterrupted. Wound healed by first intention. Both dismissed well.

Case 2.—S. C—, aged 23 years, primipara. Admitted April 19th, 1901, with os fairly well dilated; membranes unruptured. Generally contracted flat rachitic pelvis, C. D. 3¼ inches. Conservative Cæsarean section; tubes cut and tied. Placenta on posterior wall. Child, female, 7½ lbs., dead (alive two hours before operation). Recovery uninterrupted; lochial discharge very scanty. Wound healed by first intention.

Case 3.—Mrs. B—, aged 25 years, 2-para; 1 craniotomy. Admitted April 15th, 1901. Labour came on April 25th, 1901. Before operation performed os fully dilated and membranes ruptured. Generally contracted flat rachitic pelvis, C. D. 2¾ inches. Conservative Cæsarean section; tubes cut and tied; great difficulty in extracting the child. Placenta on posterior wall. Female, alive, 6½ lbs. Rise of pulse and temperature with fœtor of lochia on fourth day. Uterine douches—immediate fall. Wound healed by first intention. Both dismissed well.

Case 4.—Mrs. F—, aged 32 years, 4-para; (1) dead, full-time—"instruments;" (2) induction, 7½ months—dead; (3) premature—dead. Generally contracted flat

rachitic pelvis, C. D. 3½ inches. Admitted July 25th, 1901. Operation August 11th, 1901. Patient not in labour. Conservative Cæsarean section; tubes cut and tied. Placenta on left postero-lateral wall. Child alive, 5½ lbs. Puerperium normal. No trouble with retained clots. Wound healed by first intention. Both dismissed well.

Case 5.—A. D—, aged 25 years, primipara. Generally contracted flat rachitic pelvis, C. D. 3 inches. Admitted September 27th, 1901. Operation same day on commencement of labour. Conservative Cæsarean section; tubes cut and tied. Placenta anterior wall. Child alive, 5½ lbs. Great dyspnœa first few days of puerperium (mitral disease). Abdominal wound healed by first intention. Child died.

Case 6.—Mrs. S—, 2-para. Generally contracted rachitic pelvis, C. D. 3¼ inches. Admitted September 25th, 1901. Operation September 30th, 1901, before labour had commenced. Conservative Cæsarean section; patient not sterilised. Placenta anterior wall. Child alive, weighed 9 lbs. Slight intestinal trouble on third and fourth days of puerperium; disappeared after purgative. Wound healed by first intention. Both dismissed well.

Case 7.—M. M—, aged 23 years, primipara. Generally contracted rachitic pelvis, C. D. 3¼ inches. Admitted October 27th, 1901. Operated on same day. Fritsch's fundal incision. Placenta not encountered in incision. Child alive. Tubes cut and tied. Puerperium normal. Wound healed by first intention. Both dismissed well.

Case 8.—Mrs. M—, 3-para. Both (1 and 2) children extracted dead—craniotomy. Flat rachitic pelvis, C. D. 3¾ inches. Admitted October 28th, 1901. Labour came on twelve hours after; allowed labour to go on, intending to do symphysiotomy, but found child's head too large. Fritsch's fundal incision. Placenta encountered. Puer-

perium normal. Wound healed by first intention. Both dismissed well.

Case 9.—Mrs. H—, aged 25 years, primipara. Flat rachitic, generally contracted, pelvis, C. D. 2½ inches. Admitted January 15th, 1902. Operated upon twenty-four hours after admission, when labour commenced. Fritsch's fundal incision was employed. Placenta encountered. Patient not sterilised. Child alive. Membranes very adherent. Puerperium uneventful. Wound healed by first intention. Both dismissed well. This patient operated upon again (Case 20).

Case 10.—Mrs. A—, 4-para; 1 premature, 2 and 3 craniotomy. Flat rachitic pelvis, C. D. 3¾ inches. Admitted May 2nd, 1902. In labour; os admitted three fingers. Fritsch's fundal incision. Placenta not encountered. Child alive, 8 lbs. Bronchitis for first few days; slight pleurisy seventeenth day. Both dismissed well.

Case 11.—Mrs. M—, aged 27 years, 3-para; 1 craniotomy, 2 induction and craniotomy. Generally contracted flat rachitic pelvis, C. D. 3¼ inches. Admitted May 15th, 1902. Operated upon some hours later, when os fully dilated. Membranes ruptured and cord prolapsed. Fritsch's fundal incision. Placenta encountered. Child alive. Great tympanitis and persistent intestinal paralysis. *Died* sixth day of puerperium. At post-mortem septic peritonitis; infection apparently from uterus. Child dismissed well.

Case 12.—Mrs. G—, primipara. Admitted June 17th, 1902. Operation three weeks later. Generally contracted flat rachitic pelvis, C. D. 3¼ inches. Ordinary incision. Placenta encountered. Child alive. Some difficulty in stopping hæmorrhage. *Sudden collapse.* At post-mortem about 30 oz. of blood found in abdomen. Child dismissed well.

Case 13.—Mrs. S—, primipara. Flat rachitic pelvis, C. D. $3\frac{3}{4}$ inches. Admitted November 7th, 1902. Operation December 27th, 1902. Child alive. Supra-vaginal hysterectomy because of complete uterine inertia. On seventh, eighth, and ninth days slightly febrile; 100° highest temperature; 138 highest pulse. Wound healed by first intention. Both dismissed well.

Case 14.—Mrs. McM—, primipara. Generally contracted rachitic pelvis, C. D. $3\frac{1}{4}$ inches. Admitted March 12th, 1903. Operation March 17th, 1903, after labour had commenced. Conservative Cæsarean section. Anterior longitudinal incision. Placenta on posterior wall. Child alive. Puerperium normal, except that lochia unusually scanty. Abdominal wound healed by first intention. Both dismissed well.

Case 15.—Mrs. F—, aged 33 years, 5-para; all four children born dead. Patient was sent by ambulance waggon from Saltcoats, a distance of about thirty miles. Admitted March 20th, 1903, with os fully dilated; membranes ruptured for six hours. Supra-vaginal hysterectomy in case of infection. Child alive. Patient was very much collapsed after operation. Wound healed perfectly. Both dismissed well.

Case 16.—M. McG—, aged 19 years, primipara (?). Generally contracted flat rachitic pelvis. Admitted Western Infirmary April 21st, 1903, in labour; operated upon at once. Conservative Cæsarean section. Child alive, $9\frac{1}{2}$ lbs. Recovery excellent. Wound healed perfectly. Both dismissed well.

Case 17.—Mrs. S—, aged 28 years, 3-para; 2nd. Cæsarean section (Case 6). Complained of a great deal of dragging pain in early part of pregnancy. Operated upon at term, before labour commenced. Very extensive, but not very intimate adhesions to anterior abdominal wall. No trace of old uterine cicatrix. Uterus removed by supra-vaginal amputation. Child alive. Recovery

excellent. Wound healed by first intention. Both dismissed well.

Case 18.—Mrs. M—, aged 31 years, 4-para; 1 dead child, 2 induction—child lived only few minutes, 3 dead child. Admitted Western Infirmary August 16th, 1903, in labour, with os well dilated, but membranes unruptured. Cæsarean section (fundal incision); not sterilised. Child alive. Pulse and temperature high for first few days. Lochia scanty; uterine douche. Lochia scanty during whole puerperium. Wound healed perfectly. Both dismissed September 16th, 1903.

Case 19.—Mrs. F—, 4-para. Flat rachitic pelvis, C. D. $3\frac{3}{4}$ inches. Admitted to Maternity Hospital October 24th, 1903; os fully dilated, but membranes unruptured. Conservative Cæsarean section; tubes not tied; child alive. Developed double parotitis, and abscess in breast. Wound not affected; healed by first intention. Both dismissed well.

Case 20.—Mrs. H—, aged 26 years, 2-para; second, Cæsarean section. No discomfort during second pregnancy. Admitted Maternity Hospital, November 3rd, 1903, in labour. Very extensive but not very intimate adhesions to anterior abdominal wall. Child alive. Uterus removed by supra-vaginal amputation; cicatrix of old fundal incision can be seen on uterus; there were no adhesions to that area of uterus, either to bowel or any other part. Uterine cicatrix seems thin. Patient made an excellent recovery. Wound healed by first intention. Both dismissed well.

Case 21.—Mrs. S—, 3-para; 1 dead child, 2 craniotomy. Admitted January 27th, 1904. Delicate; generally contracted flat rachitic pelvis, C. D. $3\frac{5}{8}$ inches. Operation February 3rd, 1904, after labour had been in progress for some hours and membranes had ruptured. Conservative Cæsarean section: tubes cut and tied. Puerperium normal. One stitch abscess. Both dismissed well.

Case 22.—Mrs. W—, aged 32 years, 9-para ; 8 dead-born children. Generally contracted flat rachitic pelvis. Admitted January 10th, 1904, Maternity Hospital. Operation January 30th, 1904, after labour had commenced. Conservative Cæsarean section. Child alive, 9½ lbs. Puerperium normal. Wound healed first intention. Both dismissed well March 2nd, 1904.

Case 23.—Mrs. McC—, aged 24 years, primipara. Generally contracted flat rachitic pelvis. Admitted Maternity Hospital, February 13th, 1904, in labour; os fully dilated, membranes ruptured, cord prolapsed. Cæsarean section with supra-vaginal amputation of uterus. Child alive. Puerperium febrile : septic. Pelvic cellulitis, incisions. Both dismissed well March 19th, 1904.

Case 24.—Mrs. S—, 3-para ; 1 craniotomy, 2 induction—dead child. Flat, generally contracted, rachitic pelvis. Admitted Maternity Hospital, February 16th, 1904; operation February 25th, 1904. Conservative Cæsarean section : tubes cut and tied. Child alive. Puerperium normal, and wound healed perfectly. Both dismissed well March 19th, 1904.

Case 25.—Mrs. H—, aged 37 years, 8-para ; 5 dead children, 2 living. Flat rachitic pelvis, C. D. 3⅝ inches. Considerable overlapping of head at brim. Admitted February 16th, 1904, Maternity Hospital ; operation February 19th, 1904, after labour had commenced. Conservative Cæsarean section ; tubes cut and tied. Child alive. Puerperium satisfactory. Wound not satisfactory ; one or two stitch abscesses. Both dismissed well April 8th, 1904.

Case 26.—Mrs. G—, aged 23 years, primipara. Generally contracted flat rachitic pelvis, C. D. 3¼ inches. Admitted Maternity Hospital February 6th, 1904, in labour (examined outside Hospital). Supra-vaginal am-

putation of uterus. Child alive, 8½ lbs. Puerperium normal. Wound healed by first intention. Both dismissed well March 16th, 1904.

Case 27.—Mrs. S—, aged 21 years, 4-para. History of three different labours with dead children. Admitted Maternity Hospital May 9th, 1904. Flat, generally contracted, rachitic pelvis, C. D. 3½ inches. Operation following day, when os well dilated, but membranes unruptured. Conservative Cæsarean section; tubes cut and tied. Child, male, alive. Puerperium uneventful. Both dismissed well June 10th, 1904.

Case 28.—Mrs. E—, aged 24 years, 3-para. Two previous pregnancies—abortion and premature labour. Admitted Maternity Hospital May 5th, 1904. Flat rachitic pelvis, C. D. 3½ inches. Operation performed May 16th, 1904. Cæsarean section, followed by supravaginal hysterectomy. Child, male, alive. Puerperium uneventful. Both dismissed well June 11th, 1904.

Case 29.—Mrs. K—, aged 21 years, primipara. Admitted Maternity Hospital April 30th, 1904. Generally contracted rachitic pelvis, C. D. 3½ inches. Operation May 30th, 1904. Conservative Cæsarean section before labour; tubes cut and tied. Very disturbed puerperium. Retention of blood-clots and later pleuro-pneumonia. Both dismissed well July 1st, 1904.

Case 30.—Mrs. McI—, aged 23 years, primipara. Admitted Maternity Hospital May 6th, 1904. Flat rachitic pelvis, C. D. 3¼ inches. Operation June 10th, 1904. Conservative Cæsarean section, when os well dilated, but membranes unruptured. Child, female, alive. Puerperium uneventful. Both dismissed well July 8th, 1904.

References.

Galabin.—British Medical Journal, vol. ii, 1902, p. 1123.
Williams.—Obstetrics, 1903.

Olshausen.—Reference, Cent. für Gyn., 1904, No. 40, p. 1207.

Leopold.—Archiv für Gyn., Bd. lvi, p. 1.

Cameron.—Brit. Med. Journ., vol. ii, 1902, p. 1126.

Duncan.—Trans. Obst. Soc., vol. xlii, 1900, p. 258.

Targett.— ,, ,, p. 242.

Routh.— ,, ,, p. 244.

Horrocks.— ,, ,, p. 259.

Spencer.—Journ. Obst. and Gyn. British Empire, vol. i, 1902, p. 138.

Sinclair.—Journ. Obst. and Gyn. British Empire, vol. v, p. 13; and Trans. North of England Obst. Soc., 1901, p. 65.

Wallace.—Journ. Obst. British Empire, vol. ii, p. 556.

von Braun-Fernwald.—Archiv für Gyn., Bd. lix, p. 320.

Green.—Trans. Amer. Gyn. Soc., vol. xxviii, p. 120.

Smyly.—Reference, see Wallace's paper.

Suillaume.—Reference, Cent. für Gyn., 1896, p. 1286.

Woyer.—Monat. für Geburt. u. Gyn., Bd. vi, p. 192.

Everke.—Cent. für Gyn., 1901, p. 72.

Meyer.—Cent. für Gyn., 1903, p. 1416.

Bas.—Leçons de Pathologie Obstétricale, Paris, 1900.

Abel.—Mentioned by Braun v. Fernwald.

Munro Kerr.—Journ. Obst. British Empire, vol. ii, p. 21; Brit. Med. Journ., vol. ii, 1902, p. 1130.

The President said that it always seemed to him singular that so many cases were collected by individuals. There must be some local influences to account for so large a number of cases in particular localities. For his own part, he had gone twenty years between his first case and meeting with another requiring Cæsarean section from pelvic deformity. Two years ago he had performed the operation six times in fifteen months. Four of these were for contracted pelves, two for carcinoma. All the cases recovered from the operations and all the children were delivered alive.

Dr. Herman said he wished to thank Dr. Munro Kerr for his very practical, interesting, and reasonable paper. It was necessary that this subject should be re-discussed from time to time, because the statistics of many years ago had no bearing on the

practice of to-day; and even those of a few years ago could hardly be taken as representing what could be done. His own experience led him to think that one of the most important factors in the prognosis of Cæsarean section was the time at which it was done. If performed before labour, or at the very beginning of labour, it was a safe operation; but not so if postponed until the patient had been exhausted by protracted labour. He thought it would be well if those who published statistics of Cæsarean section would divide them into two groups: those done because prolonged ineffective labour had shown that natural delivery would not take place, and those done early to prevent difficulty. Cæsarean section, when performed early, was the simplest and easiest of all abdominal operations, because the parts concerned were healthy and normal; there were none of the unforeseen difficulties that were sometimes met with in the removal of tumours. Cæsarean section performed early ought to have no mortality at all. With regard to sterilisation, he thought if that was to be done the way to do it was to remove the uterus. Tying the Fallopian tubes had been proved to be ineffective. If the patient was not to have children the uterus was a useless organ, liable to disease. He thought it was for the patient to decide whether she would be sterilised or not. If she preferred not to run the risk of rupture of the uterus and repeated Cæsarean sections, he thought she was entitled to have her wish complied with. Suppose that a medical man, in discussing the matter during pregnancy, should tell a patient who wanted to be sterilised that he would on no account do it, the result would be that she would engage another operator; and he thought that an operator should not take advantage of an emergency to make his will prevail over that of his patient. He did not think that the presence of heart disease was a sufficient reason for removing the uterus. If valvular disease of the heart was well compensated, the patient might have any number of children without risk; but if compensation were inadequate, trouble usually came on before the end of pregnancy.

Dr. Griffith stated that there must be many operators who, like himself, had not published results because they felt that the operation of Cæsarean section by competent operators for contracted pelvis, under favourable circumstances, should have no mortality, and he believed that he had not lost a single case. And the only two deaths after Cæsarean section he had operated on, one at St. Bartholomew's was admitted with gangrenous fibroids, which he removed by hysterectomy; the other at Queen Charlotte's Hospital, where he operated on a woman dying from extensive pelvic cancer, so that she might not die undelivered. This patient survived five or six days, a little longer than if he had left her undelivered. Tables of morbidity were usually based on an artificial and arbitrary standard. Dr. Kerr's

standard was 100·5°, the standard at Queen Charlotte's is 100°, and Dr. Griffith thought it might more correctly be 99°. There is nothing in the operation to which ordinary surgical principles, as applied to abdominal surgery, are insufficient to guide the operator. He had never yet used a vaginal douche, and he did not think it at all necessary in cases in which there was no evidence of infective inflammation. As regards sterilisation of the patient, he had invariably done it by ligature of the tubes with fine silk, but he had been much influenced by Dr. Spencer's arguments at the last discussion on the subject, and agreed with him that it was not essential in all cases, and he strongly preferred to do it without removing the uterus, an unnecessary mutilation in contracted pelves.

Dr. Amand Routh spoke in admiration of Dr. Kerr's paper and his successful results. He did not, however, consider that the mortality statistics, as between hysterectomy and simple Cæsarean section, were comparable, unless each series were divided into two groups, one of operations done on patients seen before labour and fully prepared for operations, and the others where the patients were seen after labour had set in. He had had experience of six cases, five seen before labour with no deaths, and one, seen after labour had been in progress for twenty-four hours, who died. He described the last case as emphasising his point. When first seen by him the patient had been in labour twenty-four hours, and was apparently dying of exhaustion. The uterus was in a state of tonic contraction, and Bandl's ring was well marked. The cord and one hand protruded at the vulva, the other hand and one foot were in the vagina, the head had been perforated, and, in the attempt to extract it, much laceration of the vagina and cervix had resulted. The conjugate diameter of pelvis was about $2\frac{3}{4}$ inches. Here it was clear that Cæsarean section afforded the only possible chance, and, after some hours had been spent in rallying the patient's strength, the operation was performed, and, by keeping the abdomen filled up with saline fluid during the operation, she stood the shock excellently, but, after doing well for twenty-four hours, died suddenly, apparently from embolism. Surely this death could not be put down to Cæsarean section, and yet it would ordinarily be included statistically in the same group as cases done after weeks of studied preparation. The author divides the choice of operation into three classes, but, in the first instance, there should be only two. First, operations where a future pregnancy is desirable; second, where it is decided to prevent another pregnancy. If a future pregnancy be desired, a conservative operation is indicated, but the risks should be carefully considered and placed before those interested. It must be remembered that the patient may not be in a suitable environment for operation when next pregnant. The dangers of

rupture of the uterus in subsequent confinements is a very real one, and the risk of sepsis and secondary hæmorrhage after the primary operation is also considerable. The mortality, 8 per cent., of repeated Cæsarean sections must also be taken into account. All these points should be laid before the patient and her friends, and, if after hearing the risks, a chance of another child is still desired by the parents, conservative Cæsarean section should be performed. If a future pregnancy is not desirable some variety of sterilisation is required, and the question is whether it is desirable to sterilise by removing the uterus and leaving the ovaries, or by removing the ovaries, or by resecting the tubes. Removal of the ovaries is not practised now, owing to the known value of their internal secretion; resection of the tubes does not always lead to sterility, and takes quite as long a time to perform as a hysterectomy at full term. A hysterectomy at full term becomes extremely simple, and statistics prove its mortality to be rather less than simple Cæsarean section. Taking into account these points, as well as the greatly diminished risk of sepsis and secondary hæmorrhage, he considered the claims of hysterectomy as a legitimate method of sterilisation were worthy of serious consideration, and, personally, he strongly favoured that operation.

Dr. Herbert Spencer congratulated Dr. Munro Kerr on his interesting paper and upon his results. He was surprised to hear that the Glasgow mortality had been as high as 38 per cent. in the years 1891—1896, and that, too, in the safest class of Cæsarean section, those done for contracted pelvis. He remembered that at the Manchester Meeting of the British Medical Association in 1902 Dr. Murdoch Cameron had given his mortality at 20 per cent. He was sure that these high rates were due to some special causes, and was glad to hear that they had been greatly reduced by Dr. Kerr. His own experience of the operation in the class of cases dealt with by Dr. Kerr was limited to eight cases (six with contracted pelvis and two with obstruction by scars). The patients all recovered. He had also performed the operation four times for tumours. One of the patients died with kidney disease ('Obstet. Trans.,' vol. xxxviii, p. 403). He preferred the conservative operation without sterilisation of the patient in all cases of simple contracted pelvis which were not infected; for tumours and infected uterus, and for uncontrollable hæmorrhage, hysterectomy was sometimes required. He thought that, if at the time of delivery the patient showed signs of infection, they were probably due to infection of the cervix during examination or operation, and it would therefore be better for this and other reasons to remove the whole uterus by total abdominal hysterectomy, an operation which Dr. Kerr had not considered in his paper. He did not agree with Dr. Kerr that Porro's operation was less dangerous

than the conservative operation. As far as he knew no one had yet published statistics showing such good results as Zweifel with the conservative operation. Dr. Griffith's results had been very good, and Dr. Spencer hoped he would publish his cases, but was sorry to see that Dr. Griffith tried to sterilise his patients, and surprised to find that he tried to sterilise them by tying the tubes, which had been proved to be both unreliable and dangerous. He (Dr. Spencer) maintained the view he had always held, that there was no justification for sterilising a patient in simple cases of pelvic contraction, and dissented entirely from Dr. Herman's opinion that "if a patient wanted to be sterilised she should be sterilised." Dr. Spencer held the opinion that the matter was an ethical one, to be decided entirely by the doctor, and that his duty was to deliver the woman and restore her as nearly as possible to a natural condition, a result obtained by the conservative operation without sterilisation, and not by the mutilating operation of hysterectomy, nor by the unreliable and dangerous one of tying the tubes. If the patient became pregnant again the responsibility was not the doctor's, whose duty was to repeat the Cæsarean section, which experience showed to be very safe. He (Dr. Spencer) had operated successfully twice on one patient, and three times on another. In this patient the first two children died when a fortnight old, but the third survives, to the great joy of its mother. However pleased a woman might be at the prospect of having no more children, if her only child died, and she remained childless through the act of the doctor, she not only grieved, but sometimes gave loud and wide expression to her unfavourable opinion of the doctor who had placed her in her grievous position. With regard to Dr. Kerr's remarks on the use of preventives, Dr. Spencer thought it was not the business of a doctor to advise their use, but why in non-infected cases of contracted pelvis Dr. Kerr and others, who advised their use in such cases as heart disease, should not advise their use after Cæsarean section instead of mutilating the woman by removing her uterus or tying her tubes he failed to understand. With regard to the sutures employed in the conservative operation, he preferred silk, owing to the safety of the knot. One of Dr. Kerr's patients died from the giving way of the catgut sutures, and other cases of the same kind had been published. He should therefore continue to use silk, which had never given him any trouble in cases of Cæsarean section. He knew, however, that Olshausen, amongst others, had entirely given up the use of silk in favour of catgut for many years. He hoped yet to see Dr. Munro Kerr perform the conservative operation without sterilisation in all non-infected cases of contracted pelvis requiring Cæsarean section.

Dr. Cullingworth wished to express his appreciation of the

value of the paper. The author had specified the two points to which he desired the discussion to be specially directed. The first of these was the ethics of sterilisation. He (the speaker) was bound to say that he had altered his opinion on this subject, and was now inclined to range himself definitely on the same side as Dr. Spencer. He believed that it was not the business of an operator deliberately and unnecessarily to put it out of a woman's power to bear another child. As Dr. Spencer had said, a woman possessing one living child might consent, or even ask, to be sterilised rather than have again to face a second operation; but supposing her one child died, she might deeply regret having submitted to sterilisation. He could not agree with Dr. Herman that sterilisation should depend upon the expression of the patient's own wish at the moment. It was quite common for women in labour to vow they would never have another child; but sensible persons attached no importance to such vows. Besides, a patient's husband might die, and the fact of her incapacity to bear a child might stand in the way of a second marriage. He was distinctly of opinion that both obstetricians and gynæcologists had shown too little respect for the functional integrity of the female reproductive organs, and he thought a useful lesson might be learnt from the attitude of the surgeon towards the reproductive organs of the male. With regard to the second point emphasized by the author, Dr. Arthur Wallace had shown that there was little, if any, more risk in a second or third Cæsarean operation than in a first, and this formed another strong argument against sterilisation. He was extremely pleased to hear of Dr. Griffith's remarkably successful results. He trusted that, considering the unenviable position that England, and especially perhaps London, held in respect to its statistics of mortality after Cæsarean section, Dr. Griffith's local patriotism would induce him to lose no time in publishing his cases. The author had, in the speaker's opinion, laid more stress than necessary on the danger of infection from the vagina. In the light of our experience of the extreme rarity of any trouble from that source in the operation of vaginal hysterectomy, it seemed unnecessary to waste valuable time in elaborate vaginal disinfection. He would like to ask the author whether, in his opinion, there was any real basis for the warning, emphasised in every text-book, to avoid the *mucosa* when stitching the uterine wound. All such instructions, if unnecessary, were harmful; they diverted the operator's attention from more important matters. And this particular instruction was apt to frighten the inexperienced operator, and prevent him passing his sutures sufficiently deeply. He was in entire agreement with Sir Wm. Macewen's remarks, in his address at Oxford, on the use of non-absorbable sutures within the body. He therefore quite thought, with the author, that catgut sutures were preferable to any other for stitching up

the uterus, provided they could be so prepared as to be able to be tied firmly, and to remain unabsorbed a sufficient length of time to prevent the wound gaping. There seemed reason to hope that some sutures recently placed on the market would be found to fulfil these conditions.

Dr. Munro Kerr, in his reply, pointed out that the subject for consideration to-night was Cæsarean section in contracted pelvis, and that consequently consideration of the operation in other conditions was irrelevant. He pointed out to the President that in no case was the true conjugate more than three inches, and that the reason for the large number of Cæsarean sections in Glasgow was the prevalence of rickets amongst the working classes. It had actually occurred quite recently that his colleague had to perform the operation thrice in twenty-four hours. Some had remarked upon the simplicity of the operation. He quite agreed with these gentlemen; he believed it was probably the simplest operation in abdominal surgery, for there seldom were any complications. But the reason for a maternal mortality of 7—10 per cent., which was about the average at present, was that the patients had to be hurriedly prepared and operated upon. There was no time for careful disinfection of the abdomen and cleansing of the vagina. In addition, it must ever be remembered that cases of Cæsarean section were subjected, not only to the risks of the normal abdominal operation, but to those connected with the puerperal state. On that account therefore hysterectomy at the present time was the safer operation if the patient had not been carefully prepared a day or two beforehand, and he thought that his own figures, and those of almost all operators who had had an extensive experience of the operation, confirmed this view. It was quite otherwise in the case of those who could be carefully prepared; then he thought the conservative operation was the most suitable. In spite of what had been said to the contrary, he believed the thorough cleansing of the vagina was most important. He had given his own views on the ethics of the subject of the repeated operation. He could, however, quite understand the strong position taken up by Dr. Spencer and Dr. Cullingworth, practically the attitude taken by Green in the recent discussion in America on the same subject, and already quoted in the paper. But assuming the mortality in the repeated operation is about the same as in the first operation, namely 7—10 per cent., he contended that the chances of the woman succumbing to the operation must be very considerable after it had been performed three or four times. With regard to the subject of the material used for stitching, to which Dr. Griffith and Dr. Spencer had specially referred, he quite agreed that there was a great deal to be said against catgut. Taking everything into consideration, however, he believed that more could be said against silk for, as he had already mentioned

in his paper, troublesome sinuses occasionally occurred when the latter material was employed and became infected. He certainly was surprised that Dr. Griffith still advocated the use of silver wire; he thought the whole tendency of operators was to employ an absorbable material for ligatures and sutures. He quite agreed with Dr. Cullingworth that it was no great disadvantage to include the mucosa in one's suture, and he certainly thought with Dr. Cullingworth that it was of very great importance to stitch deeply and include the whole thickness of the uterine wall in the suture. There was just one other little matter he wished to refer to, as it had not been touched upon by other speakers or writers, and that was the fact that the uterine sutures were tied very tightly in order to bring not only the edges together, but to stop the hæmorrhage. In consequence the uterine wound might be deprived to some extent of its blood supply, and a less firm cicatrix might be the result. If that should be the case, it would naturally be an argument against the conservative operation.

NOVEMBER 2ND, 1904.

EDWARD MALINS, M.D., President, in the Chair.

Present—38 Fellows and 6 visitors.

Books were presented by the Royal Medical and Chirurgical Society, Dr. Venn, and Dr. Kamann.

J. Cole Marshall, M.B.Lond., F.R.C.S.Eng., was admitted a Fellow.

Norman Blake Odgers, M.B, B.Ch. (Plymouth); Edward Colston Williams, M.B., B.S.Lond. (Liverpool), were declared admitted.

The following gentleman was elected a Fellow:—Frederick William Forbes-Ross, M.D.Edin., F.R.C.S.Eng.

Report of Pathology Committee on Dr. Purslow's Specimen of Cystic Tumour of Uterus.

THE specimen has been unavoidably mutilated to an extreme degree during operation, so that anatomical relations are impossible to define with precision. The only relation clearly to be made out is the uterine cavity, divided apparently a little above the os internum, and

surrounded by thick uterine wall. The uterine cavity is very short; it passes upwards from the cut section for half an inch only. Attached to a central mass of uterine tissue, which probably represents the upper two-thirds of the body, are portions of two cysts, one on either side. Each cyst has very thick walls, which have become shrunken, wrinkled, and distorted by prolonged immersion in spirit.

Histological section through the cyst wall and adjacent uterine tissue shows fibro-myomatous tissue. Other sections from the more distant part of the cyst wall largely consist of fibrous tissue with numerous vessels. No definite anatomical structures have been found in any of the sections by which we can identify the character of the cyst.

C. E. Pursiow,
J. H. Targett,
G. Bellingham Smith,
Cuthbert Lockyer,
Alban Doran, *Chairman.*

October 26th, 1904.

Report of Pathology Committee on Dr. Purslow's Specimen of a Case of Tubal Mole.

The specimen consists of a tuberous mass, measuring $1\frac{1}{2}$ inches in its longest diameter, which, on section, shows a thin capsule, enclosing red spongy placental tissue. In the middle of the latter lies a small cavity in which is a fœtus measuring $\frac{1}{8}$ inch in length.

At the site of attachment the capsule is deficient over a circular area the size of a sixpence.

C. E. Purslow,
J. H. Targett,
G. Bellingham Smith,
Cuthbert Lockyer,
Alban Doran, *Chairman.*

October 26th, 1904.

Report of Pathology Committee on Dr. Frank E. Taylor's Specimen of Fibroma of the Ovary.

We have examined the tumour and the microscopic sections, and we agree with the description given by the exhibitor.

Frank E. Taylor,
G. Bellingham Smith,
Cuthbert Lockyer,
Alban Doran, *Chairman.*

October 26th, 1904.

CASE OF DOUBLE SYMMETRICAL CYSTOMA OF UNUSUAL ORIGIN AND CONNECTIONS.

Shown by Dr. John H. Dauber.

G. G—, aged 27 years, single, a teacher, was admitted to the Hospital for Women, Soho, on June 17th, having previously attended for about two months in the out-patient department. She complained of backache and menorrhagia, from which she had suffered for five or six years. There was nothing otherwise in the previous history of importance.

A note had been made on her out-patient's paper "both ovaries much enlarged and cystic."

After admission the catamenia set in, lasting ten days and being profuse, and, as the menorrhagia and pain seemed due to the (supposed) enlarged ovaries or tubes, it was decided to do an exploratory laparotomy.

On opening the abdomen the left tumour was easily brought to the surface after separating a few slight adhesions. It was yellowish-white, presenting all the appearances of a dermoid, but on further examination the tumour

was seen to be quite independent of the ovary, which was normal in appearance and situation. The mass was attached to the end of the Fallopian tube, the fimbriæ of which grasped it and were adherent to it, covering about a sixth of the total surface.

The tube itself seemed normal in all respects. I should have liked to have dissected the fimbriæ off the tumour, and this, with my present knowledge of the thickness of the cyst wall, is what I should have done, but at the time I was afraid of letting out pus. I therefore ligatured the tube close to the cyst and removed it. Curiously enough, *identically the same conditions were found on the right side.* The right ovary and tube were also apparently normal. The cyst was removed in a similar way.

At the conclusion of the operation one of the masses was cut into. It presented all the naked eye appearances of a dermoid—being full of greasy pultaceous matter.

The cysts were submitted to Dr. Norman Dalton, the Pathologist, who reported as follows:

"The cyst wall has an inner lining of very old fibrous tissue; outside there is loose connective tissue, and in one place a group of small gland acini lined by cubical epithelium; no trace of any epidermal structures. The gland acini are not like sebaceous glands.

"The pultaceous contents contained large numbers of fatty leucocytes and some fine globules of fat. It did not dissolve much in ether, the fat being inter-cellular to a great extent. There were some cholesterin crystals, no hairs.

"I think that it is not a dermoid, but a cyst developed from remnants of Müller's duct, which has suppurated."

This view may be correct. The pedunculated hydatid of Morgagni, the most anterior or cephalic extremity of the Müllerian duct, is often present, and the cysts may have originated from it.

But there is occasionally a small cystic dilatation at the anterior or cephalic extremity of the Wolffian duct. The remnant of the Wolffian duct runs below the Fallopian

tube, and sometimes alongside the uterus and vagina, persisting occasionally as the duct of Gartner, the normal condition in the sow. The tubules in the mesosalpinx are the epoöphoron, those in the mesometrium the paroöphoron. Both these, as we know, give rise occasionally to cysts of large dimensions. According to Arthur Keith ('Embryology,' page 105), "A hydatid attached to the meso-salpinx at the fimbriated extremity of the Fallopian tube is situated at the anterior end of the Wolffian duct, and represents the most anterior or cephalic of the Wolffian tubules, or perhaps the cephalic end of the Wolffian duct, or even the pronephros, although it is improbable that this transient embryonic structure should persist (J. H. Watson). It certainly corresponds to the pronephric remnant found in the frog. It may become enlarged or cystic, but never to a great extent."

I am rather inclined to think myself that these symmetrical cysts originated from this hydatid, the cephalic extremity of the Wolffian duct, rather than from the Müllerian duct, partly on account of its situation,—it was not pedunculated, but closely grasped by the fimbriæ,—and partly because we know how prone other remnants of the Wolffian body are to take on cystic developments.

Microscopically they are clearly not dermoid cysts, nor mere dilatations of the Fallopian tube itself. They are quite outside both the tube and broad ligament, and had no connection whatever, as I have stated, with the ovaries.

Another curious feature in the case is the suppuration of the cysts. The patient never had any temperature either before or after operation. The uterus and vagina were quite normal, and why they should have both suppurated simultaneously, for no reason apparently, is to me very puzzling. The case has seemed to me an interesting one, and I thought it might possibly interest some of the Fellows.

The specimen was referred to the Pathology Committee.

DERMOID CYST OF THE OVARY, REMOVED BY ABDOMINAL SECTION FIVE YEARS AFTER CAUSING OBSTRUCTION TO LABOUR.

Shown by Dr. Walter Tate.

Mrs. L—, aged 34 years, married, had her first confinement five years ago. On that occasion the passage of the head was obstructed, owing to the presence of a tumour in the pelvis. After very great difficulty the medical attendant succeeded in pushing up the tumour beyond the head and delivering with forceps. The puerperium was perfectly normal, and no further investigation was made into the nature of the swelling. The patient has had two easy labours since, the last occurring in April, 1904. Since the last confinement there have been three attacks of abdominal pain, and much discomfort has been suffered owing to bad "prolapse of the womb." Numerous pessaries have been tried, and entirely failed. Dr. Atkey, of Southampton, sent the patient to see Dr. Tate in August, 1904. A cystic tumour could be felt occupying the pelvis and pushing back the uterus. The perinæum was very lax, and there was considerable prolapse of the anterior and posterior vaginal walls. The cervix reached almost to the vulva, and the sound showed the uterine canal to be 4½ inches long.

Plastic operations were performed on the anterior and posterior vaginal walls and perinæum, the cervix was amputated, and finally the ovarian cyst was removed by abdominal section and the uterus fixed to the abdominal wall. The whole series of operations were carried out under one anæsthetic.

The ovarian cyst removed was as large as a fœtal head, and on section was found to contain a mass of hair and sebaceous material, while projecting from the wall of the cyst was a bossy projection containing bones, on the surface of which were several beautifully-formed teeth.

PREGNANT UTERUS WITH CANCEROUS CERVIX REMOVED BY PAN-HYSTERECTOMY.

Shown by Dr. F. N. Boyd.

Mrs. Boyd showed a pregnant uterus removed on July 6th, 1904, by abdominal pan-hysterectomy from a patient of 40, who came to the New Hospital giving a history of five months' hæmorrhage recurring in fortnightly attacks. The cervical growth was not ulcerated, but a wedge excised for diagnosis showed definite squamous carcinoma. The uterus was noted to be held up somewhat towards the left, but no definite infiltration of the broad ligament could be made out. It seemed to be one of the borderland cases, where it was worth while to give the patient the chance afforded by a radical operation, which she accepted.

The operation was somewhat complicated by the size of the uterus, by the difficulty of freeing the cervix on the left side, and by the brittle condition of the vessels here, which made them difficult to secure, so that there was quite a fair amount of bleeding. Consequently, she had to be content with tying the uterine arteries where they could be reached, and was unable to carry out the typical dissection of these vessels with the connective tissue of the broad ligaments.

The uterus with the right appendages was removed through the abdominal wound, the left appendages separately. The pelvic peritoneum was closed in the usual way by catgut suture over a gauze drain passing between the vaginal flaps into the vagina. The abdominal wound healed by first intention, but with the vaginal wound an unusual thing happened: the gauze drain was removed on the third day, and, on examining *per vaginam* on the sixth day, the peritoneal stitch was found to have cut out, and large intestine to be prolapsing into the vagina. After a saline douche she returned it, supporting the

vaginal flaps with a light gauze pack, and, except that it was necessary to keep the patient recumbent for a longer time than usual, no further difficulty ensued, and the vagina healed well. She was more than ever doubtful about the prognosis after the operation, for she was far from satisfied that the left broad ligament was not invaded by the disease, and feared a rapid recurrence.

When the patient was seen a short time ago, however, she was looking well and strong, both abdominal and vaginal scars were soft and sound, and no infiltration could be detected in the neighbourhood of the left fornix.

In commenting on the specimen, Mrs. Boyd said that when Dr. Sanderson showed a similar case before the Society in 1901 most of the Fellows who spoke expressed themselves as opposed to the abdominal operation chosen, preferring the vaginal method, either immediately after emptying the uterus in one way or another, or after the lapse of several days, when involution had occurred to some extent. In the course she had adopted in this case she had followed the practice usual at the New Hospital for Women, where, since 1901, she and her colleague, Miss Aldrich-Blake, in all cases of cancer of the body of the uterus, and in most cases of cancer of the cervix, used the abdominal route. They had now had in all twenty-one cases without a death, so that she claimed that the patient was not exposed to any more risk by adopting this method. She thought the plan of emptying the uterus and waiting for involution before removing it opposed the surgical principles which guided the treatment of cancer elsewhere, viz. to remove a cancerous organ at the earliest possible moment after the diagnosis was established. It would seem that the process of involution following on the activity of a miniature labour, with its increased supply of lymph to the part, might prove specially favourable to the spread of cancer cells in the interval before the growth was removed. This consideration, and the danger of the possible high implantation of cancer cells or of uterine sepsis by the means necessary to empty the uterus, made her think the removal of the uterus entire a safer operation.

Dr. Lockyer remarked that this was the second specimen of its kind shown at this Society where the combined vagino-abdominal method of hysterectomy had been adopted for the treatment of pregnancy complicated by cancer of the cervix. The other case was that of Dr. Sanderson, who, on September 18th, 1901, removed the uterus by this method during the eighteenth week of gestation (see 'Obstet. Soc. Trans.,' vol. xliii, p. 312).

Thanks to Dr. Sanderson, his specimen was again exhibited side by side with that of Mrs. Boyd. Dr. Sanderson had kindly replied to Dr. Lockyer's request for the after-history of the case as follows:—"The case to which you refer remained apparently perfectly well up till the following June, in which month I examined her carefully, and there was no sign of local recurrence. She developed ascites rather suddenly in August, and died in six weeks from peritoneal cancer. The vagina remained free of growth, and the recurrence was entirely abdominal." The speaker remarked upon the significance of the last statement in Dr. Sanderson's letter. It was to him another convincing proof that cases of recurrence after hysterectomy for cancer are due to direct implantation of cancer cells at the time of the operation and through the mode of technique. Dr. Lockyer had shown a case at this Society where, after he had removed a rapidly growing epithelioma of the cervix which had extended to the posterior vaginal wall, death followed five months later from the development of a large growth at the *lower edge of the vaginal incision*, thus affording conclusive evidence of implantation by knife or scissors during removal. Upon that occasion the speaker had suggested that the only method of overcoming this danger was to adopt Dr. Spencer's plan of employing the electro-cautery instead of using knife or scissors, and now, since he learned from the history of Dr. Sanderson's case that "*peritoneal*," but *no local* recurrence occurred after removal of the cervical growth through the abdomen, Dr. Lockyer was driven to the conclusion that in all cases where pregnancy is complicated by operable carcinoma cervicis the uterus should be removed *per vaginam*. In the earlier months the ovum need not be interfered with, but after the fourth month it would be better to empty the uterus before its removal by the cautery.

Replying to Dr. Lockyer, Mrs. Boyd said that she quite agreed as to the desirability of destroying a cervical growth with the cautery before removal through the abdomen, and had adopted that method. But in the present instance, as the growth was not ulcerating, and the mucous membrane intact, she had thought that direct implantation metastases were not likely to occur.

FIBROID OF BROAD LIGAMENT.

Shown by Dr. F. N. Boyd.

Mrs. Boyd showed a case of fibroid of the broad ligament removed at the New Hospital for Women from a patient of 63.

The menopause had occurred at fifty-four, and had been followed two years after by a flooding. For the three months previous to operation she had had copious hæmorrhages every three weeks, and had noticed considerable increase in size for five months.

At the operation a fibroid, springing from the neighbourhood of the left mesosalpinx, was found adherent to the tube and involved with it in a torsion. It was removed with the appendages of the left side, and, as its benign nature was not then clear and the uterus itself was seen to be enlarged, a pan-hysterectomy was done. On opening the uterus the walls were thick and fibroid, and the cavity occupied by a tongue-shaped polypus, consisting of fibrin attached to an adenomatous base. The section showed a benign adenoma. The fibroid sprang apparently, as was common with the pedunculated fibroids of the broad ligament, from the mesosalpinx, but in close relation with the ovarian ligament. The section showed ordinary fibroid structure, and was taken from the pedicle of the growth, quite close to the shrunken ovary.

The specimen was referred to the Pathology Committee.

CARCINOMA OF THE OVARY OF UNUSUAL TYPE.

Shown by Dr. Cuthbert Lockyer.

Dr. Cuthbert Lockyer showed a growth of the left ovary removed on December 12th, 1902.

The clinical history of the case was as follows:

J. F—, aged 44 years, had been married twelve years. She had had one child nine and a half years ago. Two abortions had occurred, the last being in December, 1901.

The patient came to Plaistow Hospital on December 4th, 1902. She had been under treatment for hæmorrhoids for fifteen months, and had obtained relief from aperient pills and simple enemata. During the past year she had been in Dagenham Isolation Hospital for small-pox. When first seen by Dr. Lockyer, at Plaistow, the patient complained of "pain in the back passage, with a discharge of blood and pieces of white stuff." Defæcation was difficult, and never complete; much straining was necessary, the motion being at times tape-like in shape. The patient had to go to stool as often as ten times in a morning; sometimes blood alone passed, at other times fæces in small fragments.

Menstruation was regular, lasting three or four days; it was painful, and occasional clots were passed. Lately the flow had been pale in colour. The pain started in both iliac fossæ, and ran down both thighs, and through to the back. There had been some leucorrhœa, but never a blood-stained discharge between the periods.

Examination revealed a growth in the pelvis of stony hardness, and nodular on the surface, which was pressing upon and displacing the rectum. This hard growth was continuous with a spherical tense mass of cystic consistence, which filled the pelvis below and reached to the umbilicus above. The cervix uteri was pushed to the right; the os was patulous. The sound was not passed.

The tumour was taken to be a fibroid of the uterus which had undergone cystic degeneration in front and above, whilst its still solid portion was pressing upon the rectum behind, and setting up signs of rectal ulceration and obstruction. On December 12th, 1902, the abdomen was opened by a four-inch incision in the mid-line. The abdominal part of the cyst at once presented, and its contents burst into the peritoneal cavity; on passing the hand into the abdomen thin greenish fluid escaped. The pelvis was filled by a second cyst, which was adherent to the floor of Douglas's pouch. Uniting these two cysts upon their posterior aspect was an elongated solid mass made up of three tuberous lobes with a crenated outline, which on section showed a smooth homogeneous surface like that of a potato. This mass lay posteriorly, and pushed the rectum inwards; it was what had been mistaken for a fibroid, and to its relation with the rectum had been attributed all the symptoms which pointed to obstruction of the bowel. This growth, partly cystic and partly solid, belonged to the left ovary, and had stretched the two folds of the left broad ligament over its lower half. Its removal was effected by ligaturing the adnexa close to the uterus, and tying off the expanded broad ligament in front of the tumour. The sigmoid and upper part of rectum were distended by hard fæcal masses.

The right ovary contained two cysts united by a fragment of atrophic ovarian tissue. There was a small pedunculated cyst in the right mesosalpinx. These, together with a part of the right tube, were removed.

The uterus, thus deprived of its supports, was fixed to the anterior abdominal wall, and, after tying off some oozing adhesions on the floor of Douglas's pouch and flushing the abdomino-pelvic cavity with sterile Koch's solution, the abdominal wall was brought together by means of three layers of silk sutures. The patient recovered without a rise of temperature, but rectal obstruction, which would only partially yield to enemata, led to a further examination of the bowel, and then only, after

removal of the ovarian growth, was the carcinoma recti discovered by digital examination. The symptoms of chronic intestinal obstruction became more severe, and were relieved by colotomy, after which the patient only lived for a few months.

Description of the tumour.—The growth consists of two cysts united by solid tissue in the middle. The entire tumour is of an elongated oval shape, and when *in situ* it stood on end, with its long axis in the vertical, so that the larger of the two cysts, which was uppermost, reached to the level of the umbilicus, and extended downwards into the pelvis to about the middle of the sacrum, where it was replaced by solid growth. The latter ran obliquely across the axis of the tumour, and was continuous below with the smaller cyst, which was adherent to the pelvic floor, but not to the uterus. The upper cyst had very thin walls and was unilocular, the lower was multilocular, and contained collaginous material; the upper measured 7 inches in its longest diameter, the lower measured 4 inches in its greatest length.

The solid growth measured $4\frac{1}{2} \times 2\frac{1}{2}$ inches, and consisted of three crenated lobed nodules the size of small tangerine oranges. The solid portion only presented upon the posterior and upper part of the tumour; in front the cysts were in contact and hid the solid growth from view.

On microscopical examination the solid tumour looked at first sight like a fibro-adenoma with far more fibrous tissue than glandular elements. The latter were represented by branching tubules lined by a single layer of columnar epithelium, some of the cells were in the goblet condition.

The ovarian ligament ran into the solid growth, so that this appeared to be a neoplasm of the hilum of the ovary, and the unilocular cyst probably arose from the same source, whilst the multilocular cyst represented the oöphoritic portion of the gland.

The parts removed from the right side consisted of 3 inches of the Fallopian tube, the mesosalpinx, and the

ovary. The latter contained two cysts, each the size of a walnut, and united by a narrow central isthmus of puckered ovarian tissue. The parovarium was well marked, and showed a pendulous cyst the size of a horse-bean, corresponding to a Kobelt's tube.

Although the first impression, gathered from a view of the microscopical section of the solid tumour of the left ovary, gave the impression that it was a fibro-adenoma, *i. e.* a benign growth; a careful survey of several sections led Dr. Lockyer to conclude that he was dealing with a columnar-celled carcinoma, similar in structure to the type of cancer found in the intestine. Portions of the growth very closely resemble the drawings of Dr. W. A. S. Griffith's specimen of "Primary Solid Carcinoma of the Ovary," figured in the 'Transactions' of this Society, vol. xlii, Plate V, page 34, the chief difference being that none of the sections show any resemblance to spheroidal-celled carcinoma, as was the case in Dr. Griffith's specimen, but, as far as the hollow tubules lined by a single layer of columnar epithelium are concerned, the two cases agree. Shattock has recorded a case of columnar-celled carcinoma of the ovary ('Trans. Path. Soc.' vol. xl, p. 208) which consisted, histologically, of tortuous channels of various forms, according to the direction of their section, and lined with remarkably tall, slender, and very closely-compressed columnar epithelium disposed in a single layer and everywhere bounding a lumen. The stroma between the spaces is of a delicate richly-celled connective tissue, and is about in the same proportion as the tubular elements. The contents of the spaces are sharply demarcated from the cells, and consist in many of an unstained, glassy, minutely-fissured substance, presenting very clear traces of concentric lamination.

These are the only two cases the speaker had been able to find which at all correspond to his own case in histological features; both were rapidly fatal.

At the October meeting Dr. Lockyer drew attention to the frequent association of cancer of the alimentary tract

and of the ovary or ovaries, but he could not accept the view that the ovarian growth is *necessarily* always secondary to the growth in the bowel. In cases where one type of carcinoma exists in the bowel and another type in the ovary he (the speaker) argued that the foci were probably independent—an example of carcinomatosis in fact, and not one of primary lesion and metastasis.

In the present case where the bowel symptoms had been shown by the clinical history to exist for fifteen months, and where the ovarian growth resembled in its structure the columnar cancer, so common in the rectum, it certainly seemed highly probable that the solid mass in the hilum of the left ovary (measuring four and a half inches in its longest diameter) was secondary in origin to the carcinoma recti.

Whilst granting that this particular case is one of primary carcinoma of the bowel with a metastasis in the left ovary, the speaker is not prepared to say "ab uno discite omnes."

A NEW GALVANO-CAUTERY KNIFE.

Shown by Dr. Herbert Spencer.

Dr. Herbert Spencer showed a galvano-cautery knife which he had designed, and had had constructed by Messrs.



Mayer and Meltzer. The new feature in it consisted in the method of insulating the wires. In his instrument

the handle itself formed the means of insulating the wires. The handle was made of non-conducting vegetable fibre, and the whole instrument could be boiled. There was the additional advantage that there were no loose points, the platinum wire being fused on to the ends of the thick copper wires which passed through and were fixed in the handle. The handle was attached by means of a plug to flexible wires fixed to a pedal-switch so that the current could be turned on and off quickly without using the hands. He had used the instrument a good many times for high amputation and for hysterectomy.

Dr. Amand Routh asked if the whole operation of vaginal hysterectomy was done with the cautery knife, especially as regards the stripping off of the bladder from the lower uterine segment.

Dr. Lockyer referred to the very bad results in removal of the tongue by the thermo-cautery, in which cases secondary hæmorrhage due to the absorption of sepsis by the eschars was a frequent occurrence. He asked Dr. Spencer if secondary hæmorrhage had occurred in any of his cases where he had used the cautery for vaginal hysterectomy?

Dr. Spencer, in reply to Dr. A. Routh's question, said he *did* remove the cervix and the uterus by the galvano-cautery only, without the use of scalpel or scissors; the bladder was easily kept out of the way by means of a retractor which was placed on the anterior flap. In reply to the question as to secondary hæmorrhage he stated that he had met with it once or twice, but it was due to defective technique and not to the cautery.

THREE CASES OF CANCER OF THE CERVIX COMPLICATING LABOUR IN ADVANCED PREGNANCY, THE PATIENTS REMAINING WELL ELEVEN, EIGHT AND A HALF, AND EIGHT YEARS AFTER HIGH AMPUTATION OF THE CERVIX.

(With Plates IX—XI.)

By Herbert R. Spencer, M.D., B.S., F.R.C.P.,

PROFESSOR OF MIDWIFERY AND OBSTETRIC MEDICINE IN UNIVERSITY COLLEGE, LONDON; OBSTETRIC PHYSICIAN TO UNIVERSITY COLLEGE HOSPITAL.

(Received September 30th, 1904.)

(*Abstract.*)

An account is given of three cases of cancer of the cervix complicating labour in advanced pregnancy which were delivered through the natural passages, and treated by high amputation of the cervix during the puerperium, or (in one case) five months after delivery. The patients remain well and free from recurrence eleven, eight and a half, and eight years after the high amputation.

The children were born alive, and one survives; one of the patients has since been delivered by Cæsarean section of a child which also survives.

The writer has only been able to find two other cases in which the patients operated on for cancer complicating labour in advanced pregnancy have remained well for five years, viz. Olshausen's (five and three quarter years), and von Ott's (eight and a half years.

The five cases were all delivered through the natural passages, and were operated on within a short period after delivery.

The writer also gives short notes of three cases of cancer of the cervix complicating labour in advanced pregnancy in which the disease was too extensive for radical treatment. Two were delivered through the natural passages, and one by Porro's operation (with the *serre-noeud*). All three cases recovered, and the children were born alive.

These six cases comprise the whole of the writer's experience of cancer complicating advanced pregnancy (see Table III).

Tables are given of two series of cases from the Berlin and Leipzig clinics, eighteen cases in all, of which twelve were in the operable stage and were treated by vaginal or abdominal hysterectomy. Of these twelve cases two died from the operation, *i. e.*, the mortality was 16·6 per cent., and only one patient remained well five years after the operation.

Five of the Berlin and Leipzig cases, too far advanced for curative operation, were delivered by Cæsarean section, followed, in three cases, by amputation of the body and suturing of the stump; four of these patients succumbed, giving an immediate mortality of 80 per cent.

The methods of treatment are briefly discussed.

The opinion held by Pinard, Bouilly, and others that these cases are hopeless, that the end of pregnancy should be awaited, and the interests of the child only considered, is shown to be erroneous. In the writer's opinion labour should be induced by de Ribes's bag if the pregnancy is some weeks short of term, and treatment should have in view the cure as well as the safe delivery of the patient. How to attain these objects will best be judged when more gynæcologists publish all their cases, and larger statistics become available. Meanwhile the author is in favour of the following:

1. Great care should be taken by the use of antiseptic solutions, uncontaminated instruments, and the cautery to prevent local implantation of cancer cells.

2. In operable cases delivery should be effected *per vias naturales*, when practicable, followed, during the puerperium, by the high amputation of the cervix with the galvano-cautery, and, in certain cases, by the removal of the body immediately afterwards.

3. In operable cases in which the growth is limited to the cervix

which will not dilate the author suggests (*a*) the removal of the cervix with the galvano-cautery, followed by the delivery of the child and the removal of the body either by the vagina or by the abdomen, as being probably preferable to (*b*) the removal of the child by Cæsarean section, and of the uterus by the vagina (Olshausen), and (*c*) the removal of the child and body by the abdomen, and of the cervix by the vagina (Fehling).

4. For operable cases in which the cancer has extended outside the cervix cauterisation of the growth followed by abdominal hysterectomy.

5. For cases too far advanced for radical operation Porro's operation with the use of the *serre-nœud*.

When a pregnant woman is suffering from operable cancer of the cervix the considerations which will guide us in treatment vary according as the patient is in the first seven months or the last two * months of pregnancy. In the former case the treatment usually adopted entails the sacrifice of the child; but, except in France (where Bouilly, Pinard, Varnier, and Champetier de Ribes † have advocated waiting till the end of pregnancy), I believe gynæcologists agree that the sacrifice of the child is justified in these cases in the interest of the mother. The operative technique offers no special difficulties in the early months.

In the last two months of pregnancy, with which only this paper deals, the difficulties of treatment of operable cancer are increased by the interests of the child and by the great vascularity and large size of the uterus. The infrequency of the cases in the care of individual gynæcologists and the great rarity of "cure" ‡ have rendered the treatment varied, and the results have been very un-

* German authors mostly speak of ten months (*lunar*) where we speak of nine months (*calendar*): the last two months of British writers thus correspond roughly to the last three of German writers in including the ages at which the child has a reasonable chance of survival.

† 'Annales de Gynécologie et d'Obstétrique,' 1901.

‡ I use the term for the sake of brevity in the conventional sense of "freedom from recurrence for five years."

satisfactory. The following three cases successfully treated by an operation which is now uncommon will, I think, be of interest to the Society.

Case 1.—E. W—, aged 33 years, married ten years, who had had four children (born without the aid of instruments) and one abortion, was delivered by forceps in the Maternity of University College Hospital of a full-term living child, through a cancerous cervix, on March 25th, 1893, by my assistant, Mr. H. Ballance, who correctly diagnosed the condition. She had suffered from pains for the previous week, and the discharge of blood, which she had had for eight months, had increased. Regular pains set in on March 24th, at 6 p.m. The os dilated slowly, the posterior lip dilating well, but the anterior lip, occupied by the cancerous growth, not yielding. At 1 a.m. on the 25th the membranes were ruptured artificially. The labour progressed slowly, although the pains were fairly strong. At 5.20 a.m., as the pulse was 100, and the patient had not much strength for bearing down, the forceps was applied (the head being low in the pelvis), although the os was not fully dilated. Very gentle traction sufficed to deliver a living male child.* The placenta was expressed fifteen minutes later. There was no post-partum hæmorrhage. The patient made an uninterrupted recovery, the temperature not rising above 98·4° during the puerperium. Iodine douches were given daily.

She was admitted to University College Hospital on April 5th, 1893. She stated that for the last eight months she had had a bad discharge, consisting of blood and matter, but no clots. The discharge was greater after exertion. It had not altered in amount since the birth of her child. She had not lost flesh, and had generally enjoyed good health, but had been troubled with a white discharge occasionally before her present illness. She began to menstruate at fourteen, was always regular, the periods lasting four days, and being accompanied by a

* This child died when eleven months old of whooping cough.

Fig 1.

Case 1.—Squamous epithelioma of cervix. Sketch by author just before operation. (Natural size.)

Fig. 2.

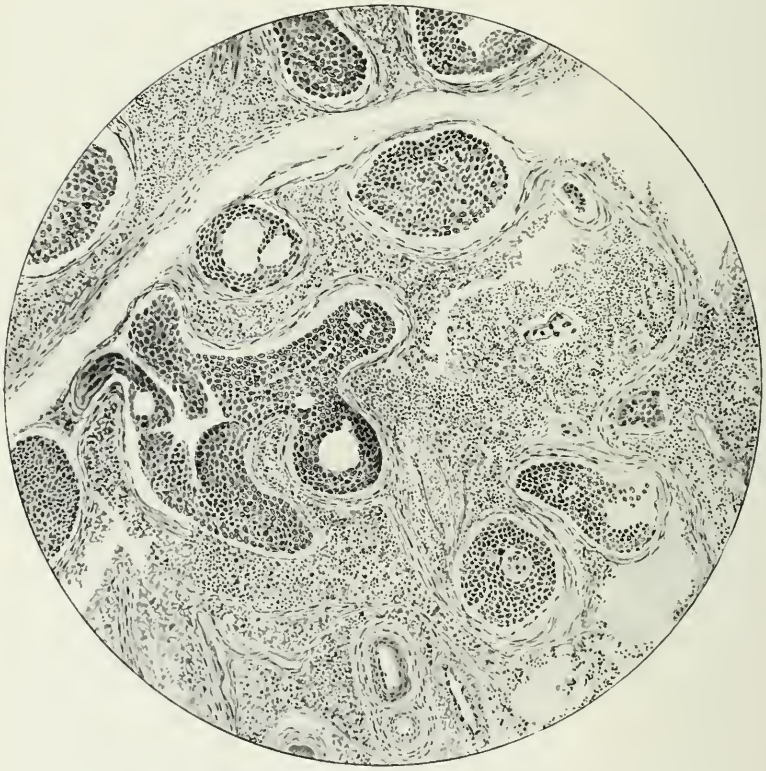

Case. 1.—Squamous epithelioma of cervix. (Microscopic section under low power.)

Adlard & Son, Imp.

good deal of pain at the beginning. There was no history of tumours in the family.

On admission the patient looked fairly well and was not anæmic. The heart-sounds were normal. There were some sibilant râles all over the chest. The fundus of the uterus reached up to a height of three and a half inches above the pubes. There was a slightly enlarged gland to be felt in the right groin. The perinæum, slightly notched, had practically healed. The cervix was rather far back and drawn over to the right side of the pelvis. It was movable. The anterior lip of the cervix was greatly enlarged by an ulcerated, malignant growth, as far as the vaginal insertion; the posterior lip was free. The drawing (see Pl. IX, fig. 1) shows the actual size and appearance of the cervix just before operation. The growth did not bleed much on examination. There was no invasion of the broad ligaments, as determined by rectal examination.

On April 8th, 1893, I removed the cervix by the high amputation. After incising the vagina in front of the cervix and pushing up the bladder, a similar incision was made behind, and the base of the broad ligament was tied with thick catgut ligatures, and the part between the cervix and the ligatures divided with scissors. The cervix was then freed higher up, during which part of the operation the uterine cavity was opened anteriorily. One or two small vessels were temporarily clamped, and then the cervix was cut off, and all bleeding stopped with Pacquelin's cautery. The peritoneum was not opened. The vagina was firmly packed with iodoform gauze and a morphia suppository given. The recovery was uneventful. The gauze was removed on April 11th; afterwards boric acid douches and iodoform bougies were employed. On April 25th the body of the uterus had involuted well; it did not appear to measure more than one and a half to two inches in outside length. At the fundus of the vagina was a healthy, granulating surface, measuring $\frac{3}{4}$ in. by $\frac{1}{2}$ in. Microscopic examination showed the growth to be a squamous epithelioma (see Pl. IX, fig. 2). [The cervix

and sections were shown.] On May 4th the wound had soundly healed, and on May 8th the patient left the hospital, she and her child being quite well. She was regular afterwards and at first menstruated without pain, but in February, 1894, had considerable pain.

On June 6th, 1894, she menstruated for the last time and became pregnant. On March 6th, 1895, I performed Porro's operation, treating the stump extra-peritoneally with the *serre-nœud;* the ovaries and tubes were also removed. Both the mother and the child recovered well. I have published a full account of the operation in 'Obstet. Soc. Trans.,' vol. xxxviii, p. 413. The child weighed 7 lbs. 5 oz. I have seen the patient and her child frequently since.

		Infant
In May, 1894, the patient weighed	8 st. 9 lbs. ...	—
„ May, 1895, „ „	9 „ 3 „ ...	11 lbs.
„ April, 1896, „ „	8 „ 8 „ ...	16¼ „
„ June, 1897, „ „	8 „ 2 „ ...	—
„ May, 1898, „ „	7 „ 12 „ ...	—
„ Feb., 1899, „ „	8 „ 4 „ ...	—
„ Oct., 1902, „ „	8 „ 9 „ ...	3 st. 12 lbs.
„ July, 1903, „ „	9 „ 8 „ ...	—
„ July, 1904, „ „	9 „ 3 „ ...	4 st. 4 lbs.

„ Feb., 1899, she still had flushes two or three times a day.

I saw her on July 16th, 1903; she was quite well. The abdominal and vaginal scars were perfectly sound and free from hernia. The child delivered by Cæsarean section on March 6th, 1895, was also well. Sexual desire and sexual pleasure had been absent since the operation. She was examined by me in July, 1904, when she was quite well, eleven and a quarter years after the high amputation of the cervix. The child also was well.

Case 2.—A. C—, aged 35 years, married sixteen years, during which time she had had eight children but no miscarriage, was admitted to University College Hospital on January 3rd, 1896, complaining of discharge, a burning

and scalding sensation in the womb, bleeding, and pain in the right groin.

Seven months ago she noticed that after coitus, which was painful, she lost a small quantity of blood, but she stated that she had had similar symptoms during her pregnancy in 1891. In June, 1895, she became pregnant, and in September, 1895, she noticed a discharge, white in colour, not blood-stained except after coitus, and in the last six weeks before admission the discharge had been thin, watery, and at times blood-stained and offensive. During the last three days she had lost a considerable quantity of blood with clots, and the discharge had been reddish-yellow in colour.

She had had fairly good health till four years ago, when she came to London, after that time she constantly suffered from cough and shortness of breath. Nineteen years ago she had rheumatic fever. Three years ago she suffered pain in the lower part of the abdomen on the right side and vomited a little blood. A short time before this the patient had some small ulcers about the labia with swelling of these parts, also discharge and scalding in micturition. There were no definite symptoms nor history of syphilis.

A cousin of the patient died of cancer of the womb. There was no family history of tubercle.

The patient's first child was stillborn; some of the labours were long and difficult, but instruments were not used. The patient was last unwell on June 6th, 1895 (seven months before admission). Menstruation began at 14, was always regular, rather profuse, and preceded by rather severe pain in the back.

On admission the patient looked in fairly good condition, not anæmic or cachetic. The heart-sounds were rather weak. There was no murmur. The breath-sounds, rather harsh, were well heard at the bases behind. There were no râles. The abdomen was distended as by the uterus at six and a half months; the girth at the umbilicus was 35½ inches. The uterus reached up verti-

cally to a height of $8\frac{3}{4}$ inches above the pubes, 3 inches above the umbilicus. Fœtal movements were seen and felt. The child was in the second vertex position, the back on the right side of the fundus; there was no placenta on the anterior wall of the uterus. The glands in the groin were not enlarged. The liver appeared to be normal. The cervix was high up and much enlarged. There was an irregular malignant growth on the posterior lip and in the canal on the left side, bleeding a little on examination, and typically malignant both to touch and speculum. The exact shape and dimensions are shown in the drawing made by me just before operation, the measurements being taken with compasses (see Plate X, fig. 2). The growth did not appear to involve the vagina nor the broad ligaments. I advised the patient to have labour induced and the cervix removed, but she refused; and it was only by making threats which I was not in a position to carry out that the patient was persuaded to let me bring on labour. At 3 p.m. on January 9th, the vagina having been douched with 1 : 3000 sublimate solution, I introduced a Champetier de Ribes's bag after dilating with Hegar's dilators. During the night the patient had scarcely any sleep; at 9 p.m. ℥xx of Tr. Opii were given; at 11 p.m. chloral hydrate grs. xii; at 3 a.m. chloral hydrate grs. xv. At 7 a.m. on the 10th, labour pains set in; at 9.45 a.m. the bag was expelled. The head was found in the third position, and four inches of pulsating cord prolapsed. The os was fully dilated. In a few minutes the child was born, and it was followed in twenty minutes by the placenta and membranes. Very little blood was lost, and the uterus retracted well. A vaginal douche of (℥j to Oj) iodine was given and ℥iij of hypodermic injection of ergotin. The temperature was 99·6°, the pulse 84.

On examination the cervix did not appear to be much lacerated, and the growth in the cervix felt much the same as before the introduction of the bag. The child, a male, 16 inches long, weighed 3 lbs. 7 oz. It was very

Fig 1.

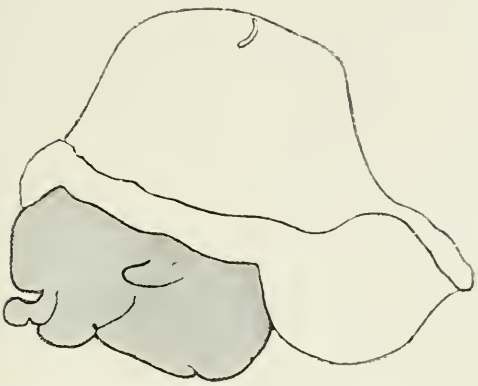

Case 2.—Squamous epithelioma of cervix showing amount amputated.

Fig. 2.

Case 2.—Squamous epithelioma of cervix. Sketch by author just before operation. (Natural size.)

Adlard & Son, Imp.

feeble, and although it gave a few gasps, in spite of artificial respiration it only survived thirty-eight minutes.

Measurements of the child's head,			oc. mental	$4\frac{1}{4}$ ins.
„	„	„	oc. frontal	$3\frac{3}{8}$ „
„	„	„	sub-oc. bregmatic	$3\frac{1}{2}$ „
„	„	„	cervico-bregmatic	$3\frac{3}{8}$ „
„	„	„	bi-parietal	$3\frac{3}{4}$ „
„	„	„	bi-temporal	$2\frac{3}{4}$ „
„	„	„	bi-mastoid	$2\frac{1}{2}$ „
„	„	„	mento-frontal	$2\frac{3}{4}$ „

The patient passed through the puerperium without any serious drawback. The temperature did not reach 100°, and the pulse was only once over 80 during the first ten days; she afterwards had a slight attack of rheumatism which she had previously suffered. This raised the temperature for a few days (on one occasion to 103·8°), but by the fifteenth day it was normal. During the puerperium two douches of iodine solution (5j to Oj) were given daily.

On Jan.	14	the uterus was	$3\frac{1}{2}$	ins.	above the pubes.
„	15	„	$3\frac{1}{4}$	„	„
„	16	„	3	„	„
„	17	„	$2\frac{7}{8}$	„	„
„	18	„	$2\frac{3}{4}$	„	„
„	20	„	$2\frac{7}{8}$	„	„
„	22	„	$2\frac{1}{4}$	„	„

On January 28th, 1896, I removed the cervix by the high amputation, cutting the vagina with scissors, tying the broad ligaments and vessels with catgut and severing the cervix with Pacquelin's cautery. The peritoneum was opened posteriorly and a piece of iodoform gauze inserted. The portion of the cervix removed measured $1\frac{1}{4}$ inches vertically, $2\frac{3}{4}$ inches antero-posteriorly, and $1\frac{3}{4}$ inches transversely. The operation took an hour and a quarter. A vaginal plug of iodoform gauze was placed in the vagina. The patient had a slight attack of cystitis and pain in the left iliac region, and on February 7th a rigor with temperature of 104·8°; it was probably due to

constipation, as it fell, and the pain disappeared after a dose of castor oil. On February 8th the sutures were removed and the wound was found to be granulating well. Microscopic examination showed the growth to be a squamous epithelioma (see Plate X). [The specimen and sections were exhibited.]

On February 11th there was no tenderness around the uterus.

On February 17th the patient left the hospital with the scar quite healed. On March 13th she weighed 9 st. 13 lbs. I have seen the patient every year since.

On July 14, 1896,	she weighed	10 st. 1 lb.
„ Oct. 6, 1896,	„	10 „ 1 „
„ Mar. 30, 1897,	„	9 „ 11 „
„ Oct. 18, 1898,	„	11 „ 0 „
„ May 9, 1899,	„	10 „ 12 „
„ Jan. 30, 1900,	„	10 „ 10 „
„ April 16, 1901,	„	10 „ 11 „
„ June 24, 1902,	„	11 „ 12 „
„ Oct. 20, 1903,	„	12 „ 5 „

I saw her on October 20th, 1903, seven and three quarter years after operation. She was in robust health. The scar was quite healthy and there was no sign of recurrence. Menstruation had been regular every four weeks, for six days. She has had no trouble since the operation except slight pain for two days of the period. This was relieved by five or ten grains of antipyrin. The vagina was capacious, easily took a speculum $1\frac{3}{8}$ inches in diameter for $4\frac{1}{2}$ inches, but would admit a much larger speculum. Coitus took place, but was usually painful. Sexual gratification has never been experienced either before or since the operation. The patient came to the hospital on August 9th, 1904, to show that she was quite well—over eight and a half years since the cervix was removed.

Case 3.*—M. S—, aged 38 years, came to the out-patient department on June 5th, four months and eleven

* In this case the cancer was not actually *observed* until nearly $4\frac{1}{2}$ months after delivery; but the patient had had *every day* since her con-

days after delivery. Cancer of the cervix was diagnosed by Dr. Blacker, and she was admitted to University College Hospital on June 23rd, 1896, complaining of loss of blood *every day* since her last confinement on January 25th, 1896. She has been twice married—first at twenty-one years of age: from this marriage issued six children, including twins; only the eldest child of these six survives, the others died of convulsions—secondly at thirty-two years of age: from this marriage resulted three children, of which the eldest two are healthy; the youngest, five months old, had a red rash on the buttocks, "corruption" round its nose, and a discharge and snuffles. The patient had persistent sore throat in December, 1895, lasting six weeks, but has never had any eruption on the body. Two and a half years ago she had a vaginal discharge and marked swelling of the vulva, with frequent and painful micturition.

The patient was delivered in the Maternity of University College Hospital on January 25th, 1896, being attended by a student. She was at full term, and the delivery was normal, and the child living. There was no bleeding before labour, which was easy and lasted six hours. She got up on the eleventh day, still bleeding. Every day since her delivery she has lost blood and a few shreds, but never any clots, nor has she had pain except once three days before admission when she had paroxysmal pain in the lower abdomen.

On admission the patient was anæmic; the breasts contained milk. There was nothing abnormal to be felt in the abdomen. The glands in the groin were not enlarged. The cervix was in the middle of the pelvis, had been slightly lacerated on both sides. On the left side, especially on the posterior lip, was a papillary soft growth bleeding readily on examination and evidently malignant.

finement loss of blood and shreds, which ceased after the removal of the cancerous cervix. There is, therefore, I think, no doubt that the cancer existed at the time of labour; but those who think differently will exclude this case.

This was confirmed by examination with the speculum, which showed it to be ulcerated (see Pl. XI). The body of the uterus was retroverted, freely movable, not enlarged. Neither broad ligament was affected.

On June 30th, 1896, I performed the high amputation of the cervix, tying the uterine vessels with catgut, and stitching the vaginal mucous membrane to the endometrium. Douglas's pouch was opened, but was closed again with a silk suture. A vaginal tampon of iodoform gauze was afterwards applied. Next day the patient was well and free from pain.

On July 3rd she had abdominal pain, and the temperature rose to 101·6°. The iodoform gauze plugs were removed and two others lightly applied; these were removed on July 7th and the vagina syringed with boric lotion and afterwards with iodine lotion, by means of a glass syringe and rubber tube.

On July 11th the stitches were removed; the wound had healed. Microscopic examination showed the growth to be a squamous epithelioma. [The specimens and sections were exhibited.]

On July 19th the patient went home quite well.

I have seen her every year since. She has remained quite well; has only menstruated once since the operation, but has a little pain every three weeks, and has flushes occasionally.

The patient weighed on		June 23, 1896,	8	st.	9 lbs.
„	„	Oct. 20, 1896,	8	„	6 „
„	„	July 19, 1898,	8	„	8 „
„	„	Oct. 25, 1898,	8	„	10 „
„	„	Jan. 19, 1899,	8	„	3 „
„	„	Mar. 6, 1900,	8	„	5 „
„	„	Oct. 27, 1902,	8	„	6 „
„	„	Feb. 2, 1904,	8	„	0 „

I saw her on October 27th, 1902. She was quite well. The child, a girl, 6½ years old, was 44½ inches in height (with boots on), and weighed 3 st. 5 lbs. I saw the patient again on February 2nd, 1904, quite well; the vagina easily

Fig. 1.

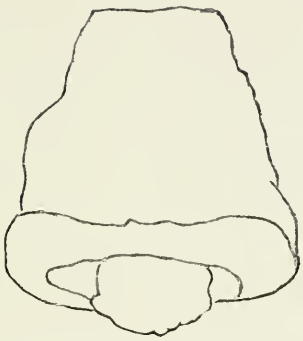

Case 3.—Squamous epithelioma of cervix showing amount amputated.

Fig. 2.

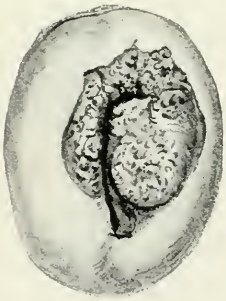

Case 3.—Squamous epithelioma of cervix. Sketch by author of specimen which had been five years in spirit. (Natural size.)

Adlard & Son, Imp.

admitted a good-sized speculum. The vaginal scar was perfect, and there was no orifice to be seen in it. She had had practically no pains since the operation. The child was alive and well and over eight years of age. I heard from the patient on August 6th, 1904, that she is quite well, over eight years since the operation.

O. Sarwey, in 'Veit's Handbuch der Gynäkologie,' 1899, deals with the treatment of cancer of the cervix complicating pregnancy in the last two months. He gives a list of cases under the following headings:

1. Hysterectomy immediately following Cæsarean section (labour pains being absent)—5 cases, with 4 living mothers and 3 living children.

2. Labour, *per vias naturales*, followed by vaginal hysterectomy in *puerperio*—15 cases, with 14 living mothers and 9 living children.

3. Labour, *per vias naturales*, followed by immediate vaginal or combined hysterectomy—4 cases, with 3 living mothers and 3 living children.

4. Cæsarean section followed by immediate abdominal or combined hysterectomy—6 cases, with 2 living mothers and 3 living children.

In all 30 cases, with 23 living mothers, 18 living children. Of these 30 cases in only two is it stated that the patient was alive after five years, viz. in v. Ott's cases (8½ years freedom from recurrence), and Olshausen's (5¾ years freedom from recurrence). Both these cases were delivered *per vias naturales*, and were operated on by vaginal hysterectomy 3½ weeks and 17 days after delivery.

Sarwey's cases have been culled from the literature of published cases; but, as it is certain that thirty is but a small portion of the number of operable cases which have been operated upon, any statistical use of his figures would be vitiated by several well-known factors. I prefer to deal with the figures of those who have published all their cases.

A series of seven cases from Zweifel's clinic in Leipzig

has been published by A. Glockner * (see Table I). Of these seven cases (2, 4, 6, 7, 11, 12, 14 in Glockner's paper) one (No. 4) died on the 28th day of ileus and perforating peritonitis; the other six recovered, but only one remained free from recurrence after 3 years and 2 months, when she died of peritonitis. By adding six cases in which cancer may have been present, although it was not observed at the time of labour, but at an average period of about ten months after labour (the earliest being six months, and the latest thirteen months after labour), better final results are obtained; but the evidence that cancer was present at the time of labour is not convincing; indeed, in one case in which it is stated that there was "a large, freely bleeding erosion" on the anterior lip, no evidence is given that cancer was present at all. I have therefore excluded these six cases, since it is obvious that if we include cases operated on in which cancer was found ten months after labour we shall have to include similar cases not operated upon, the material for which is not forthcoming.

A. Glockner also gives a list of three inoperable cases, in all of which Cæsarean section was done. All three cases were treated by ligaturing the stump which, in two cases, was dropped into the pelvis, and in one was stitched extra-peritoneally to the abdominal wall (Hegar's method). All three cases died of septic peritonitis.

R. Olshausen, 'Carcinom des Uterus und Schwangerschaft,' 1897, gives a list of four operable cases in which pregnancy had advanced to the last two months. These four cases occurred out of thirteen cases of cancer complicating pregnancy he had met with. One of these four cases was free from recurrence after $5\frac{3}{4}$ years, the others recovered from operation, but died within a year. Of the children, in the four operable cases three died at the time of delivery; the final history of the living child is not given. Two cases were inoperable, and were treated

* 'Über Uterus carcinom und Schwangerschaft mit besonder Berücksichtigung der Dauerresultate der operativen Behandlung, 1902.

TABLE I.—*Table of Cases of Advanced Pregnancy* complicated by Cancer of the Cervix at the University Women's Clinic in Leipzig from* 1887 *to* 1901.†

No.	No. in Glockner's paper.	Age.	No. of pregnancies	Result to mother. L=Lived. D=Died. Immediate.	Recurrence.	Result to child. L=Lived. D=Died.	Mode of delivery.	Operation performed.
1	2	38	1	L.	Yes, 16 months	L.	Spontaneous labour	Vaginal hysterectomy on 18th day.
2	4	29	3	Died 28th day	—	L.	Deep cervical incisions	Combined abdominal and vaginal hysterectomy 24 hours after labour.
3	6	31	6	L.	Yes, 12 months, died	D.	Version (transverse presentation)	Vaginal hysterectomy 24 days after delivery.
4	7	26	3	L.	Yes, 5 months, died	L.	Cæsarean section	Supra-vaginal amputation followed by excision of stump *per vaginam*.
5	11	33	6	L.	No; died 3 yrs. 2 months	D.	Spontaneous labour	Vaginal hysterectomy 25 days after delivery.
6	12	30	1	L.	Yes, 22 months	L.	Abdominal Cæsarean section after failure of "Vaginal Cæsarean section"	Abdominal total hysterectomy.
7	14	33	5	L.	Yes, 5 months	L.	Spontaneous labour	Vaginal hysterectomy 24 hours after delivery.
8	15	34	8	D.	—	D.	Cæsarean section. Supra-vaginal amputation, retro-peritoneal stump	Too far advanced for curative operation.
9	16	39	9	D.	—	?	Cæsarean section. Supra-vaginal amputation, retro-peritoneal stump	Too far advanced for curative operation.
10	17	35	7	D.	—	L.	Cæsarean section. Supra-vaginal amputation, ligated stump stitched to abdominal wall extra-peritoneally	Too far advanced for curative operation.

* In the 8th, 9th, or 10th lunar month.

† This table has been prepared from particulars given in A. Glockner's 'Über Uterus Carcinom und Schwangerschaft mit besonderer Berucksichtigung der Dauerresultate der operativen Behandlung," the clinical material being furnished by Prof. Zweifel.

by the conservative Cæsarean section. The first patient died six months after the operation; the other patient died on the fifth day of sepsis; the children were born alive. The other seven cases occurred in the early months of pregnancy.

A. Kaussmann has published all the cases (eight in number) at the University Women's Clinic, in Berlin, from 1886 to 1897, including Olshausen's (see Table II).

Thus adding together the Leipzig and the Berlin cases we get eighteen, of which twelve were operable. These twelve cases gave immediately two maternal deaths and four fœtal deaths. Only one mother survived for five years, Olshausen's case ($5\frac{3}{4}$ years*); the percentage of "cures" is therefore 1 in 12, *i. e.* 8·3 per cent. The immediate maternal mortality is 16·6 per cent. The final result to the children is not given, but the immediate mortality is 5 out of 12 = 41·6 per cent.

Five cases were "inoperable," and for these Cæsarean section or Cæsarean hysterectomy with intra-peritoneal, or (in one case) extra-peritoneal treatment of the stump was done. Of these five mothers four died from the operation, and the fifth survived only five months. The immediate mortality from these operations in inoperable cases in the Leipzig and Berlin clinics is thus 80 per cent., a mortality which, occurring in such skilful and experienced hands, shows the great danger of these abdominal operations in cases of cancer. The result to the children is not fully given, but three were born alive; the final results to the children are not given. The percentage of cures of the whole eighteen (operable and inoperable) cases of advanced pregnancy complicated by cancer of the cervix is 1 in 18 = 5·5 per cent. The

* Olshausen (loc. cit.) gives $5\frac{3}{4}$ years; Kaussmann (loc. cit. in footnote to Table II) gives $6\frac{1}{2}$ years; the operation was performed on June 23rd, 1891; therefore on the date of publication of Kaussmann's Dissertation, August 6th, 1897, the period of freedom from recurrence could not have exceeded $6\frac{1}{2}$ years. I have therefore given Olshausen's figure as probably more accurate.

TABLE II.—*Table of Cases of Advanced Pregnancy* complicated by Cancer of the Cervix at the University Women's Clinic in Berlin from* 1886 *to* 1897.†

No.	Age.	No. of pregnancies.	Result to mother. L = Lived. D = Died. Immediate.	Result to mother. L = Lived. D = Died. Recurrence.	Result to child. L = Lived. D = Died.	Mode of delivery.	Operation performed.
1	28	5	L.	Yes, 5 months	D.	Induced labour	Vaginal hysterectomy 12 days post partum.
2	38	5	L.	No, after 5¾ years ‡	D.	Spontaneous labour	Vaginal hysterectomy 17 days post partum.
3	29	7	L.	? Died, 6 months	L.	Spontaneous labour	Vaginal hysterectomy 11 days post partum.
4	41	12	L. (ureteral fistula)	Died after some months	D.	Spontaneous labour and version	Vaginal hysterectomy 2 days post partum.
5	33	12	L.	Died, 6 months	L.	Conservative Cæsarean section	Too far advanced for curative operation.
6	30	4	D. (sepsis)	—	L.	Conservative Cæsarean section	Too far advanced for curative operation.
7	41	15	D. (peritonitis 8th day)	—	L.	Spontaneous labour	Vaginal hysterectomy 33 days post partum.
8	38	14	L.	?	L.	Spontaneous labour	? No operation performed.

* In the 8th, 9th, or 10th lunar month.

† The table has been prepared from the tables given in R. Olshausen's "Carcinom des Uterus und Schwangerschaft," 1897, and in A. Kaussmann's "Über Uterus carcinom bei Graviditat, Geburt und Wochenbett mit eine Casnistik der Falle aus der Königlichen Universitäts-Francen-Klinik zu Berlin vom Jahre 1886 an, 1897." The first six cases in the above table are Prof. Olshausen's.

‡ Kaussmann (loc. cit.) gives 6¼ years, but see footnote, p. 370.

percentage of cases operated on to eradicate the disease is 12 = 66·6 per cent. The total immediate mortality (in all cases operable and "inoperable") is 6 = 33·3 per cent.

From these figures it is seen that two of the finest clinics, and some of the most experienced and skilful operators in the world have only one patient alive of twelve operated upon at the end of five years, a percentage of cure = 8·3; and of five cases (too far advanced for radical cure) operated on by conservative Cæsarean section or Cæsarean hysterectomy leaving the stitched stump retro-peritoneal or stitched to the abdominal wall, only one survived the operation, that is, the immediate mortality was 80 per cent.

This is but a sad result, but there is no doubt that it is much better than the general results of similar treatment. I have no other statistics with which to compare them, but I have been able to find only one other case recorded of freedom from recurrence after five years, the case of von Ott's before alluded to, in the whole of medical literature. As very many cases must have been operated on, it follows, I think, that the results of the ordinary operations are dismal indeed.

In seventeen years at University College Hospital I have had under my care six cases of advanced pregnancy complicated with cancer of the cervix. I have not seen a case in private practice. Three of the cases were too far advanced for radical treatment. Of these one ruptured the uterus into the broad ligament under spontaneous labour; treated by gauze packing she recovered and lived for twelve months. The child weighed 8 lbs. 11 oz., and left the hospital after five weeks, weighing 10 lbs. 11 oz., and was living six months later (see 'Obstet. Soc. Trans.,' xlii, p. 15). The second I delivered by forceps. She recovered and the child also. The mother died of the cancer seven months later, the child when eight months old. The third I delivered by Cæsarean section, treating the pedicle extra-peritoneally with the *serre-nœud;* she also recovered, and the child

(about seven and a half months) was alive, but died on the fifteenth day.

To sum up my experience of cancer complicating advanced pregnancy (see Table III). Three of the cases were too far advanced for radical treatment. Two were treated *per vias naturales*, one was treated by the old Porro operation. The three patients recovered and the children were born alive. The other three cases were delivered *per vias naturales*, and high amputation of the cervix was performed by Pacquelin, scissors and ligatures with sublimate and carbolic douches during operation and iodine douches afterwards. The three patients recovered and are now well after eleven, eight and a half, and eight years. One of them has since by means of Cæsarean section had a boy who is now nine years old, healthy and strong.

If we take the only two other cases of "cure" (using that term in the conventional sense now usual amongst Continental gynæcologists of "freedom from recurrence after five years") we find that the five cases have been delivered through the natural passages, and have been operated on in the puerperium, or, in one case, five months after delivery.

When we meet with a case of cancer of the cervix in the operable stage complicating advanced pregnancy, the first question we have to decide is whether to deliver by Cæsarean section or *per vias naturales*. The mortality of Cæsarean section which I have given above (80 per cent. in advanced cases in the hands of the most skilful operators), and the experience of all who have performed abdominal section when an infected growth is present show that an abdominal section is very dangerous in these cases. Some have advised that the uterus should be removed per abdomen. Of this operation Fritsch ('Zentral. für Gynäkol., 1898, p. 1) says that it is a "very difficult, bloody, long and severe operation," and finished his remarks by prophesying that the operation "will certainly no longer be performed." On the other

TABLE III.—*Table of the Author's Cases of Advanced Pregnancy* complicated by Cancer of the Cervix at University College Hospital from July, 1887, to October, 1904.*

No.	Age.	No. of pregnancies.	Month.	Result to mother. L=Lived.		Result to child. L=Lived.		Mode of delivery.	Operation performed.
				Immediate.	Remote.	Immediate.	Remote.		
1	33	5	Term	L.	Well 11 years after high amputation of cervix	L.	Died 11 months later of whooping cough	*Per vaginam*, forceps	High amputation of cervix (April 8th, 1893) a fortnight after delivery. Two years later Porro-Cæsarean section: the child is living and healthy (1904).
2	35	8	8th	L.	Well 8½ years after high amputation of cervix	L.	Died in 38 minutes	*Per vaginam*, induction of labour by de Ribes's bag	High amputation of cervix (January 28th, 1896) eighteen days after delivery.
3	38	9	Term	L.	Well 8 years after high amputation of cervix	L.	Well 8 years later	*Per vaginam*, unassisted, easy	High amputation of cervix (June 30th, 1896) five months after delivery.
4	30	6	8th	L.	Died 7 months later	L.	Died 8 months later	*Per vaginam*, forceps	No. Too far advanced for curative operation.
5	39	15	8th	L.	Died 12 months later	L.	Living 6 months later	*Per vaginam*, forceps (rupture of uterus)	No. Too far advanced for curative operation. Rupture packed with iodoform gauze.
6	34	11	8th	L.	Died 7 months later	L.	Died 10 days later	*Per abdomen* by Porro-Cæsarean section, with use of serre-nœud	No. Too far advanced for curative operation.

* In the eighth or ninth calendar month.

hand, experience shows that while the growth is still in the operable stage the unaffected part of the cervix dilates and allows the fœtus to pass in many cases without much difficulty or danger. Olshausen (loc. cit.) has advised that after cauterising the cervical growth Cæsarean section should be done, the placenta removed, the wound rapidly stitched up, the broad ligaments tied, and the organ then removed *per vaginam*. Fehling* has recommended that after the Cæsarean section the uterus should be amputated above an elastic ligature and the stump excised *per vaginam*. As yet no one has "cured" a patient by these operations. There may perhaps be cases, still in the operable stage, where the cervix will not dilate even after small incisions, and in such cases it appears to me that it might be possible to remove the cervix by the galvano-cautery knife and afterwards to deliver either *per vaginam* or *per abdomen*, and then to remove the body of the uterus. This might entail a long operation, but it appears to me to be more in accord with surgical principles than the operations I have just mentioned.

Dührssen† and others have suggested the so-called "vaginal Cæsarean section," that is, stripping up the bladder and incising the anterior uterine wall up to the peritoneum, delivering the child and immediately removing the uterus *per vaginam*. The risk of implantation of cancer by such a procedure is sufficient to condemn the operation in my opinion, though it meets with Fritsch's approval (*loc. cit.*). E. Schroeder‡ has published four cases in which this treatment was adopted (by Chrobak, Fritsch, Winter, Seiffart). Three of the patients recovered. Winter, who operated forty hours after delivery, says that the separation of the bladder was very difficult ("recht schwierig"), as all will admit who have removed large uteri by the vagina. In cases which are

* Fehling, 'Münchener med. Wochensch.,' No. 47, 1897.

† Dührssen, 'Centralbl. für Gyn.,' 1897, p. 942.

‡ E. Schroeder, 'Zeitschr. für Geburtsh. und Gynäkol.,' 1898, Bd. 39.

comparatively early and clean I believe it is much better that the patient should be delivered by the natural passages.

The cases quoted show that it is possible to remove the uterus through the vagina immediately after delivery, but the operation is not easy, and I think it will generally be better to wait for a fortnight before proceeding to the radical operation. Of course the case should be watched, and if the growth increases or infection occurs immediate operation should be performed. As to the nature of the operation, abdominal hysterectomy, in addition to its high mortality, has not fulfilled the hopes of its advocates (see Jacobs,* 'Bull. de la Soc. Belge de Gynéc. et d'Obstétrique,' xv, p. 13). I think it should only be done if the growth has extended beyond the uterus, and yet does not preclude the possibility of complete removal with the increased facilities afforded by the abdominal operation. In other cases operation by the vagina appears to me to be preferable.

Should the whole uterus be removed or a high amputation of the cervix be performed? The cases I have reported show that in some cases (all those I have operated on) the simple and safe operation of high amputation is sufficient to "cure" the patient. But if there be any sign of sepsis, or the peritoneum be extensively opened, or there be any difficulty in controlling bleeding, the body should also be removed; but in my opinion the cervix should first be amputated with the galvanocautery to remove the infected cervix and to prevent local implantation of cancer.

To what is the success of the cases I have published to be attributed? I attribute it partly to the use of the cautery (which was used freely in the first case and to sever the cervix in the second) and to the use of strong antiseptic douches (carbolic and mercury during the

* "C'est avec un réel sentiment de découragement que je vous présente les resultats tardifs des opérations abdominales que j'ai pratiqués depuis 1897"—95 cases, 6 deaths, 1 cure after 5 years.

operation and iodine afterwards); perhaps also to the fact that the operation was done in the puerperium when the tissues were undergoing involution (I have seen a great diminution in size of the growth take place after delivery in an inoperable case). Case 3, in which the cautery was not used, was in an early stage of the disease, and was therefore less likely than the others to give rise to local implantation. For the removal of the cervix I much prefer the galvano-cautery knife to the Pacquelin cautery, which was used in these cases. I have used the galvano-cautery knife for several years both for high amputation and for hysterectomy; the credit for its introduction belongs to the late Dr. Byrne, whose results (by high amputation) have never been equalled. I believe it is the best means of preventing local implantation, and probably the heat destroys outlying cancer cells, which are said to be more vulnerable to heat rays than ordinary cells.* In no other way than by the avoidance of local implantation of cancer cells, especially by the use of the cautery, can I explain the difference between the results obtained by Byrne, Baker, myself, and others, when compared with the results after the use of the scissors and knife by such skilled operators as Jacobs,† Morisani,‡ and Halliday Croom,§ who between them had 121 cases of vaginal hysterectomy for cancer with only two deaths from the operation, but not one patient remained free from recurrence after five years.

I have endeavoured in this paper to present some facts for the consideration of the Fellows of our Society upon a subject which is of transcendent importance in obstetrics and gynæcology. I hope the Fellows will add to

* Jensen ('Centralbl. für Bact.,' 28th June, 1903) quoted by R. Lomer, 'Zeit. f. Geb. und Gyn.,' v. 50, p. 331.

† Jacobs, 'Bulletin de la Soc. belge de gynecologie et d'obstetrique,' xv, 1904-1905, p. 16.

‡ Morisani, 'Centralbl. für Gyn.,' 1902, p. 1211.

§ Halliday Croom, 'Edin. Med. Journ.,' vol. v, 1899, p. 249.

those facts by giving the whole of their experience of advanced pregnancy complicated by cancer of the cervix.

Siquid novisti rectius istis
Candidus imperti; si non, his utere mecum.

Dr. Tate referred to the remarkable extent to which a cervix diseased with cancer will dilate, providing there is even a small portion of the cervical ring free from disease. In one of Dr. Spencer's cases, which Dr. Tate had had the opportunity of examining, it seemed as though nothing short of Cæsarean section would be a possible means of delivery when the patient was examined in an early stage of labour. Later on, however, considerable dilatation of the os had taken place, in spite of the fact that the disease involved more than three fourths of the circumference of the cervix, and delivery was completed by means of forceps.

Dr. Thomas Wilson congratulated the author on the extremely satisfactory lasting result of his operations in these three cases, but stated his opinion that the best method of operation for cases of this sort had not yet been determined. When the best method, whether abdominal or vaginal, in cases of uncomplicated cervical cancer had been determined, then it would be possible to apply a similar operation to cases occurring in connection with pregnancy. Dr. Wilson referred to two cases in which he had recently performed the so-called vaginal Cæsarean section in the eighth month of pregnancy with immediate results favourable to both mothers and both children. He discussed the reasons which led him to adopt the vaginal operation in these cases, and described the proceeding, which he found not difficult.

Referring to Dr. Spencer's recommendation that in the last months of pregnancy labour should be induced and a radical operation only undertaken later, Dr. Wilson remarked upon the usual influence of pregnancy in hastening the growth of cancer, and referred to a case where abortion took place at the fourth month in a patient of twenty-four: cancer of the vaginal portion of the cervix which was present appeared before the abortion to be easily operable, but afterwards made rapid progress, so that on the seventeenth day supra-vaginal amputation did not suffice to eradicate the mischief. In all operable cases, therefore, at whatever month of pregnancy they may be recognised, immediate radical operation should be undertaken. Whether this operation should be vaginal or abdominal the next ten years may be expected to show.

Dr. Herman expressed his appreciation of Dr. Spencer's able paper. He thought the general rule of treatment in all forms of cancer, viz. to remove it as soon as possible, applied to cancer

of the cervix in the later months of pregnancy. He had not himself in recent years had the opportunity of treating a case in which removal of the disease was practicable; but if he had, he thought he should have treated it by vaginal hysterectomy immediately after delivery. He had read in a German paper (by an author whose name he did not remember) that at this time the operation was easy, because the vagina was then so relaxed that the uterus could easily be pulled down to the vulva. This seemed to have been Dr. Wilson's experience. Dr. Spencer said it was difficult. Dr. Herman would be glad to hear from Dr. Spencer wherein the difficulty lay. He could not follow Dr. Spencer in advising Porro's operation with the serre-nœud where delivery through the natural passage was impossible. In abdominal hysterectomy and in Cæsarean section for conditions other than cancer surgeons had found intra-peritoneal methods much better than the serre-nœud; and he (Dr. Herman) saw no reason for going back to it in the case of cancer. He had once only performed Cæsarean section for cancer: he sewed up the uterus in the usual way, and the patient recovered.

Dr. Amand Routh thought that conservative Cæsarean section was the correct treatment in inoperable cases, and gave details of one case where the woman recovered, but died in three months, a healthy child surviving. He thought Dr. Spencer's success was due to his use of the thermo-cautery, but asked if he had had similar success in cancer of the uterus apart from pregnancy.

Dr. Handfield-Jones drew attention to the fact that in the first three cases, in which operation had been so successful, and the disease had not recurred after a long period of years, the microscope had shown that the disease was a squamous epithelioma in type. Every operator knew how very different was the degree of malignancy shown by the cervical carcinomata, some cases having a very mild degree of malignancy, and showing very little disposition either to spread or to recur after removal, while others were more of a mushroom type, grew rapidly, and recurred with certainty. Judging from the description which Dr. Spencer had given of his first three cases, it was fair to assume that the cases were of the favourable type, and that the fact of non-recurrence after a lapse of years depended more on the type of the disease than on any detail of treatment.

Dr. Briggs (Liverpool) considered the growths in Dr. Herbert Spencer's three cases, from the extent of infiltration visible under the microscope, were of the less virulent type of cervical cancer. He agreed with the author and Dr. Thomas Wilson in advocating the vaginal operation.

Dr. Griffith joined in congratulating Dr. Spencer on the success of his treatment of the three cases, but could not help feeling that the result was in some degree due to the nature of

the disease, squamous-celled carcinoma, the only form of cancer of the uterus which in its earlier stages presented a reasonable hope of cure by complete removal.

Dr. Heywood Smith said he could quite corroborate what Dr. Griffith had said with regard to the efficacy of chloride of zinc. In it he had a means whereby the major portion of the uterus could be removed with very little risk.

Dr. Lockyer noted that it was Dr. Spencer's wish to collect the experience of every Fellow of this Society on the question of treatment of cancer complicating pregnancy. The speaker's personal experience was confined to one case, in the treatment of which he proceeded counter to rules laid down in Dr. Spencer's abstract. The lady had been in labour many hours and was very exhausted when Dr. Lockyer first saw her, the pulse was beating 120 times to the minute, and was very feeble; the uterus was hard, tender, and painful, and the lips parched. Upon examination, Dr. Lockyer found the vagina filled with a cancerous growth, the cervix could not be felt at all, the growth was very friable, and a large piece was removed by the finger and subsequently examined microscopically; it proved to be a glandular carcinoma. With the assistance of Mr. P. L. Daniel the speaker opened the abdomen and delivered the child through an incision in its anterior wall. After removal of the placenta 1 : 100 gr. of ergotinin was injected into the buttocks, and this within a few seconds caused the most marked contraction of the uterus. The organ appeared in a state of pallor and spasm, No blood was lost. Removal of the growth was out of the question, and Porro's operation, with so extensive a growth, would have involved amputation above the level of the internal os, and also the leaving behind of a certain amount of the body cavity. This procedure was not for a moment entertained, but whilst fully apprehensive of the risk of insufficient drainage of the puerperal cavum uteri, Dr. Lockyer closed the opening in the uterine wall with fishing-gut sutures and sewed up the abdominal wound, thus performing "conservative Cæsarean section." The child, a strong boy, lived and thrived as well as if born *per vias naturales*. The mother recovered from the effects of the operation, and after a prolonged puerperium was allowed to get up from bed, but she soon sank after this from the exhaustion due to the growth. From a surgical point of view, therefore, the result was a complete success for "conservative Cæsarean section."

Dr. Herbert Spencer thanked the Society for the reception given to his paper, and in reply to Dr. Tate, said he had especially called attention to the facility with which the cervix dilated in some early cases, and it was partly on this fact that he based his recommendation of delivery *per vias naturales*.

He thanked Dr. Thomas Wilson for the excellent account he

had given of his two cases treated by "vaginal Cæsarean section," and he should look forward with interest to the publication of the after-history. His objection to vaginal Cæsarean section was due to the risk of local implantation. Dr. Wilson had cut through a healthy part of the cervix, but many of such cases required no cutting operation, but were delivered by the natural passages without difficulty. He was interested to know that Dr. Wilson had found the vaginal hysterectomy immediately after labour easy. Winter, who performed the same operation forty hours after delivery, found the separation of the bladder very difficult. With regard to Dr. Wilson's remark on the "well-known rapid growth of cancer in pregnancy," Dr. Spencer had to observe that this ought not to be well known. Zweifel had shown that it was rapid in his case. He (Dr. Spencer) had shown that it was very slow in his own case (vol. xlii 'Obstet. Soc. Trans.'). The fact was that in some cases it was rapid and in some cases slow.

In reply to Dr. Herman, the reason why he advocated the old Porro operation with the serre-nœud in advanced cases was that it was quicker, and he believed it was safer than the conservative operation (the former having, according to 'L'Operazione Cæsarea Porro,' a mortality of about 35 per cent., the latter, according to Sarwey, a mortality of about 60 per cent.). Septic infection was very apt to occur in these cases. If suppuration occurred there was a way out for the pus by the side of the wire; this was not the case with the conservative operation nor with the intra-peritoneal stump, which operation had given the high mortality of 80 per cent. in Leipzig and Berlin. Dr. Herman's reason for not using the galvano-cautery for cancer because Dr. Byrne's American contemporaries did not use it was, he thought, not a good one. Moreover, as a matter of fact, two of Dr. Byrne's American contemporaries had used the cautery with splendid success. Dr. J. W. Hyde had published three cases which remained free from recurrence eight, eleven, and five years after amputation with the galvano-cautery, and Dr. W. H. Baker of ten cases had four which remained well twenty years after high amputation with the subsequent use of the actual cautery.

Dr. Amand Routh inquired if the results had been equally good apart from pregnancy? Of course they had not. He had not investigated the after-history of his cases apart from pregnancy for five years, but he knew of several which remained well for that period. He thought, with Dr. Handfield-Jones, that the variety of cancer was of importance, and that further study of the histology was necessary; it might, for instance, enable us to explain why in some very early cases the cancer had already invaded the glands. He agreed with Dr. Griffith in considering squamous epithelioma the most favourable form of cancer of the

cervix; his own cases were typical squamous epithelioma. Stenosis occurred in most, if not all, cases after the use of the galvano-cautery for high amputation; but the stenosis usually caused very little trouble, and if that were feared the body could easily be removed after the cervix.

He thanked Dr. Lockyer for obtaining the after-history of Dr. Sanderson's case. He could not accept Dr. Griffith's suggestion that good fortune had anything to do with his results. When one operator had three cases (all those he had operated on) well eight years and more after operation, and all other operators put together only had two cases well after six years, the conclusion was justified that there was something in the technique which explained the difference. He had tried to show what that something was. But we had much to learn on the subject of cancer complicating advanced pregnancy. What was wanted was that operators should publish all their cases five years (not five months) after operation. He confessed he was disappointed that more Fellows of the Society had not given their experience. He still hoped they would do so when they had time to collect their cases.

DECEMBER 7TH, 1904.

EDWARD MALINS, M.D., President, in the Chair, followed by Sir WILLIAM SINCLAIR, and Dr. AMAND ROUTH.

Present—44 Fellows and 3 visitors.

Books were presented by Drs. Nagel and Frommel, and by the Clinical Society.

The following candidates were proposed for election :— Lionel Gordon Hopkins, M.B.Lond. ; George Burnett Currie, M.B.Aberd., D.P.H. ; William B. Swete-Evans, M.A.Cantab., L.R.C.P. ; Daniel E. Anderson, M.B.Lond., M.D.Paris ; Robert Humphrey Marten, M.B., B.C.Cantab. ; Rhys Basil Rees, L.S.A.Lond. ; J. Reginald Fuller, M.D.Durh., M.B., B.S.Durh. ; Martin James Richardson, M.B., C.M.Edin.

Report of Pathology Committee on Dr. Handfield-Jones' Specimen of Fibroid Tumour of the Uterus and Cystic Disease of the Surrounding Tissues.

We are of opinion that this specimen is an ovarian cyst with which a dilated Fallopian tube communicates at its fimbriated extremity.

C. HUBERT ROBERTS.
J. H. TARGETT.
CUTHBERT LOCKYER.
ALBAN DORAN, *Chairman.*

November 11th, 1904.

Report of the Pathology Committee on Dr. J. H. Dauber's Specimen of Double Symmetrical Cystoma of Unusual Origin and Connections.

We quite agree with the exhibitor's view that these growths are not dermoids.

As to their origin we are unable to express a definite opinion.

C. Hubert Roberts.
J. H. Targett.
Cuthbert Lockyer.
Alban Doran, *Chairman.*

November 11th, 1904.

Report of the Pathology Committee on Mrs. Boyd's Specimen of Fibroma of the Ovary.

We have examined this tumour and find that it is attached to the outer pole of the ovary.

Its surface is covered by smooth peritoneum, and on section the cut surface has a mottled, yellowish-grey tint like those of solid ovarian tissue. There are a few small cysts visible.

The microscopic section shows the structure of a pure fibroma.

C. Hubert Roberts.
J. H. Targett.
Cuthbert Lockyer.
Alban Doran, *Chairman.*

November 11th, 1904.

A CASE OF ABDOMINAL GESTATION.

Shown by Lieut.-Col. A. J. Sturmer, I.M.S.

The case I now wish to bring to your notice is one of abdominal gestation, but whether primary or secondary I do not offer an opinion. A few years ago such a thing as ovarian gestation was denied, but this has now been accepted as a fact. Why such an occurrence as primary abdominal gestation should not take place I cannot see; no doubt the difficulty lies in the proof, but this will surely occur.

In this case a portion of the history cannot be relied on, and I will, therefore, tell you the main facts as they occur to me, and leave out the stories given by the patient, which varied considerably in detail. One thing is certain, she never suffered from any of the symptoms one usually associates with rupture of a tube.

K—, a caste woman, aged 35 years, a widow for many years, but living with a man for a long time, states she has had amenorrhœa for five or six months. She thought she was pregnant, and, to avoid the disgrace of having a child, she resorted to the use of strong purgatives, in order to induce abortion. The purgatives were followed by such great pain that she fainted. She, moreover, could not pass urine, though small quantities continued to drain away.

She was admitted into the Madras Government Maternity Hospital complaining of great pain, situated in the right side of the abdomen, on the 4th April. She had never been pregnant before, and the periods had been regular but scanty for the last three years; no clots or pieces of membrane have ever been passed.

On admission the catheter was passed and an enema given, and after this she was able to pass water freely. The temperature was 100°. She was ordered to be kept in bed under observation, and on the 5th, and again on

the 19th, santonin was prescribed, but only one worm was passed. I may mention here that santonin is given as a routine drug, for natives of India suffer very greatly from ascarides, and sometimes as many as 100 worms are voided. Patients from the west coast seem to be extremely affected.

The breasts were full of milk, and a day or two after admission the flow became so great that the breasts had to be packed, and she was ordered some iodide of potash mixture to suppress the flow.

The abdomen was very tender, and a swelling was felt in the middle and to the right, but no fœtal limbs or parts could be made out, no fœtal heart could be heard, and no intermittent contractions could be felt. The abdomen was loaded with fat and kept very tense. From her history, and from the fact of milk in the breasts in such large quantities, it was surmised that she was pregnant, but on examination *per vaginam* only some old cicatricial bands were felt on the left, the uterus appeared to be enlarged and drawn to the left, but the cervix was small and hard, and certainly not the cervix of an uterus that was over five months pregnant. By speculum no vaginal discoloration was found.

She was kept in bed during her stay in hospital. The swelling of the abdomen did not increase in size, but rather seemed to decrease, and it became certain that if she was pregnant, as it was supposed she was, the pregnancy was not uterine. On the 12th April there was a rise of temperature to 100°, and on the 20th she had a pink discharge, which gradually changed to a dirty brown, and this continued up to the date of operation. On the 21st also the temperature rose to 101°, falling to 100° next day, and on the 28th it began to rise again, and was 100·6° at the time of operation. A sound was not passed.

I was going on leave at the beginning of May, and she begged me to do something before I left. I told her the only thing I could do was to open the abdomen, and that there were certain risks attached, but she said she was

willing to undergo them, so on the 30th April I opened the abdomen, making my incision over the right rectus muscle. On opening the peritoneal cavity a blue looking mass appeared, which was the head of the fœtus, and on incising this a large quantity of fluid blood escaped. This blood had accumulated between the scalp and bone. The back of the child was behind, and the legs towards the liver. One arm was drawn out and then the other, and after a little traction the head was delivered, followed by the body. The cord was black, and was much twisted. On being cut through no blood followed the knife. After the removal of the fœtus a smooth-lined cavity was seen, and below this were the coils of intestine, covered over by the placenta. The amniotic sac was of a greenish-yellow colour. A finger was pushed through the upper left hand corner of the smooth membrane, which was evidently the amnion, and the placenta gradually separated from the omentum and intestine, partly by the finger, and partly by sponge pressure. Portions of the omentum had to be tied off, but there was very little bleeding, the placenta appearing to be quite dead. When, however, the lower attachments began to be separated the bleeding became very free; no particular points could be seen, and the tissues were so rotten that they would not stand the application of pressure forceps. It was then seen that the bleeding came apparently from the top of the uterus, and, on further examination, it was seen that the top of the uterus was wanting, having been removed with the placenta. Supra-vaginal hysterectomy was therefore performed. The amniotic sac reached as high as the liver, and some meconium was found at the upper part. The chorion was much more firmly adherent than the placenta, and was attached to the parietal peritoneum, and some difficulty was experienced in removing it, but there was very little bleeding; it extended much more on the right side. About a pint of blood-stained liquor amnii escaped before the child was extracted. The reason why the scalp was incised was to lessen the size of the head, for it

was very evident that the blue tumour presenting was cystic. The abdomen was washed out with saline solution, and the incision closed in three layers.

Parts removed.—Fœtus measuring fourteen inches between uprights, female. Eyes open, mouth widely open, anus open, and on pressure meconium issues. Hands reach nearly down to the knees. Weight 2 lbs. 6 oz. Placenta more solid than usual, dark, apparently all has been brought away, is much elongated, and spread out towards one end. *Tubes, etc.*, both fimbriated ends open, and a bristle can be passed up some way; on the right side the fimbriæ are not very distinct. There is considerable matting of the appendages on both sides. Uterus small; at the top and behind the whole fundus appears to have disappeared, and the raw surface does not look like that of a recent rupture. At the time of the operation a ring of small vessels was seen at the top which bled very freely; below this ring the tissue looked white and healthy.

Douglas's pouch was quite roofed in. The placenta, as it grew, drew the intestine towards the uterus, and, after its removal, the gut could be separated from the uterus, and Douglas's pouch was laid bare, and was quite free from all growth.

First day after the operation.—Very quiet; complains of pain; vomited three times, greenish fluid; pulse very quick and irregular. Highest temperature 100·4°.

Second day.—Maximum temperature 102·2°. Sleeping on and off; very quiet; complains of great thirst; vomits constantly small quantities of greenish fluid; it is more like regurgitation than vomiting, for the fluid comes up without apparent effort. A good deal of distension of the abdomen; has brought up a great deal of wind by mouth. Urine drawn; clear. Pulse still very bad. Calomel and soda were ordered, and a mustard plaster to the epigastrium, after which the vomiting ceased for a time, and she had some refreshing sleep.

Third day.—Following the calomel magnesia sulphate

was ordered, but she could only retain one dose. The distension was no greater, and the colour of the vomit was not green. The pulse was still very bad. Bowels not acted. Maximum temperature 101·6°.

Fourth day.—Had six motions yesterday, yellow and offensive. Dressings changed; the skin has not united; a thin purulent discharge from the central portion of the wound. Delirious last night. From this point there is no need for a daily record of her case; she went from bad to worse, and died ultimately on the 6th May. The vomiting appeared to have continued up to the time of her death. For the late notes of her case I am indebted to Major Simpson, I.M.S.

The death was evidently due to septicæmia, but how this arose I cannot say. Every possible precaution was taken to avoid such an ending. There was, no doubt, a great deal of handling of the intestine, and a very large extent of tissue that had been covered by placental tissue was exposed, and such parts were ready to absorb any poisonous matter that may have been brought within reach.

The great interest in this case lies in the question where did the fecundation of the ovum occur? The tubes appear to be macroscopically intact, and there is no history of any such occurrence as a rupture. I have purposely not interfered with them or the ovaries. I have been looking through the cases recorded in the 'Transactions,' and find that all the cases of abdominal gestation report pain, as of a rupture of a tube. In the case reported by Mr. Bland-Sutton in the 'Transactions' for the year 1899 he considers that "the enlarging amnion eroded the expanded tube, and slowly made its way into the belly." There is no history of any severe pain or signs of collapse prior to the abdominal gestation. This may have occurred in my case, but there are no signs of any erosion of the tube, and I fancy nature cannot always mend her injuries in such an artistic manner that no sign of a rent or tear is left. I have only once before had the

misfortune to meet with a case of abdominal gestation, and then the placenta was plastered all over the back of the uterus, and, on separating it, no portion of the uterus came away. The difficulty which seems in this case to require explanation is why a portion of the top of the uterus came away with the placenta. Was the pregnancy originally uterine, and did the uterus gradually rupture or become eroded, and the fœtus become extruded into the abdominal cavity?

The specimen was referred to the Pathology Committee.

Dr. Cullingworth said that it did not follow, because the Fallopian tubes presented a normal appearance, that the pregnancy had not originally been tubal. On reference to the Society's 'Transactions' for 1898 (pages 187 and 316, *et seq.*) it would be found that both Mr. Bland-Sutton and he (the speaker) had called attention to the fact that the Fallopian tube may, by virtue of the remarkable properties of unstriped muscle, resume its normal dimensions and appearance, very quickly, after the escape of an ovum from within it. He had related, in the volume of 'Transactions' already mentioned (p. 187 and footnote), a remarkable case in point, which Dr. Arthur Stabb would no doubt remember.

Dr. Amand Routh referred to a case of his own, described by Dr. Cuthbert Lockyer (in 'Obstet. Soc. Trans.,' vol. xlv, 1903, p. 400), where secondary abdominal gestation had followed tubal rupture. Gradual migration of the placenta away from the rupture on to the omentum and other structures occurred, and growth of the fœtus continued. In this case it seemed that migration had not entirely detached the ovum from the seat of rupture in the tube.

THREE CASES OF INTESTINAL OBSTRUCTION FOLLOWING OPERATIONS FOR FIBROID TUMOUR OF UTERUS, WITH SPECIAL REFERENCE TO THE CHOICE OF OPERATION.

By Walter Tate, M.D., F.R.C.P.

(Received November 23rd, 1904.)

(*Abstract.*)

Case 1.—Single woman, aged 23, had suffered from menorrhagia for twelve months, with gradual enlargement of abdomen. Tumour reached to one inch above umbilicus.

Myomectomy performed on May 6th, 1902. No trouble till two days after operation, when vomiting commenced. On May 9th pain and vomiting worse; no result from aperients. At 10 p.m. abdomen reopened, knuckle of bowel found adherent to scar at back of uterus. Bowels well opened next day, followed by uninterrupted recovery.

Case 2.—Single woman, aged 46, with history of menorrhagia for seven years, especially severe the last twelve months. Solid tumour discovered reaching halfway up to umbilicus. On December 18th supra-vaginal hysterectomy performed. Good progress during first week. On eighth day after operation temperature began to rise, and patient complained of pain. On ninth day some distension appeared, and aperients failed to act; sickness began. Sickness continued, pulse-rate increased to 140, distension increased, and on December 28th abdomen was reopened. Several coils of bowel found adherent to stump, and

some serous exudation tracking up towards left lumbar region. Convalescence protracted, but ultimately good recovery.

Case 3.—Young married woman, aged 22, was confined of her first child March 10th, 1904. Some fever on sixth day of puerperium, and tender swelling discovered in hypogastrium. Three weeks later second swelling discovered in right iliac region. Physical signs rather suggested dermoid disease of both ovaries. On April 14th supra-vaginal hysterectomy was performed. Patient got on well, and bowels acted well on morning of 17th. The same evening patient had abdominal pain and began to vomit. Pulse-rate rapidly increased, looked pinched and ill, vomiting continued, aperients and enemata entirely failed. At 5 p.m. on 18th abdomen reopened. Knuckle of bowel found constricted by band of omentum firmly adherent to stump. Band of omentum separated and ligatured. Bowels acted on next day, and patient made good recovery.

Supra-vaginal hysterectomy has been the operation selected by the writer in nearly all cases of fibroids up till the last few months. The occurrence of three cases of obstruction in a series of 150 operations calls for serious reflection. It appears to the writer that dangerous adhesions of bowel are more likely to follow supra-vaginal hysterectomy than pan-hysterectomy. The immediate risk of the two operations in the large bulk of cases is equal, though in a few special cases the complete extirpation may expose the patient to greater risk at the time of operating. There is no advantage to be gained by leaving the cervix, and in some cases the presence of the cervix may give rise to troublesome complications. The possible danger to the ureters is not an argument against the operation of pan-hysterectomy, as the risk of injuring them is to a great extent imaginary, and these structures ought not to be damaged when proper care is taken.

The occurrence of intestinal obstruction after an abdominal operation, and necessitating the reopening of the abdomen, is a complication so serious to the patient, and so disappointing to the operator, that no apology is needed

for bringing these three cases, which have occurred in my own practice, before this Society.

It is hoped that a discussion on this important subject may throw some light on the causation, and may suggest the best means of preventing adhesion of bowel. It would be interesting also to hear the experience of other Fellows as to the frequency of this accident—if I may call it so—in their surgical work, in order to show whether there is or is not a special liability to the occurrence of dangerous bowel adhesions after the operation of supra-vaginal hysterectomy, which has been so generally practised during recent years.

I will first give a short account of my three cases of obstruction, two of which occurred after supra-vaginal hysterectomy, and the third case occurred after myomectomy for a large tumour of the uterus. In all three cases the abdomen had to be reopened.

Case 1.—Single woman, aged 23. Had suffered from menorrhagia for a year, and had noticed a swelling in the abdomen gradually increasing during the same period. On examination, the patient had a smooth, firm, symmetrical-shaped tumour reaching up to one inch above the umbilicus. The uterine canal was lying in front of the tumour.

The abdomen was opened on May 6th, 1902. The tumour was seen to be symmetrical in shape and growing from the posterior wall of the uterus. The uterus with Fallopian tubes were clearly defined. As the patient was only 23 years of age it was decided to do a myomectomy. Two flaps were therefore cut from the base of the tumour, and after enucleation of the tumour the flaps were brought together by fine silk sutures. The fibroid tumour removed weighed 2 lbs. 14 oz.

On May 7th general condition good.

On May 8th patient had troublesome vomiting and retching, and was put on rectal feeding.

On May 9th pain and retching continued. No result

after castor oil, calomel, and saline. Some flatus passed after turpentine and gruel enema. Slight distension. Pulse 120.

At 10 p.m. patient seen again. Not so well. Vomit thick and brownish. Decided to reopen. Old incision opened up. Some blood-stained fluid escaped on opening the peritoneum. On passing hand down into the pelvis a knuckle of small intestine was found adherent to the back of the uterus. Below the knuckle the intestine was collapsed, above it was distended. The dilated portion was punctured in two places and a large quantity of fluid contents evacuated. After this half an ounce of sulphate of magnesium was injected into the bowel. The wound was then closed.

May 10th.—Sickness entirely ceased. Later on had two ounces of Haustus Sennæ Co., followed by turpentine enema, with good result.

Patient subsequently made an uninterrupted recovery.

Case 2.—A. D—, single, aged 46, was admitted to St. Thomas's Hospital on December 9th, 1903. Patient was an anæmic looking woman, who had always suffered from menorrhagia; but during the last seven years the loss had been more profuse, and especially so during the last twelve months. For two years patient has noticed a lump in the lower part of abdomen, and has suffered from pain in this region. On admission the patient had a firm, solid-feeling tumour reaching halfway up to the umbilicus. The cervix was high up and directed backwards. The anterior fornix was depressed by a hard, round mass continuous with the abdominal tumour. There is a certain amount of mobility.

On December 18th laparotomy was performed. The ordinary supra-vaginal amputation of uterus was performed; two small flaps, consisting of peritoneum and a small quantity of underlying muscular tissue, being dissected from the lower uterine segment, and the uterus

and tumour removed. The flaps were united after the manner of Lembert with fine silk sutures.

The tumour removed in this case was a diffuse adenomyoma of uterus, one of the cases I exhibited before this Society in the early part of this year.

After the operation the patient had very slight shock, but the same evening the temperature rose to 100·8°. For the first week after the operation she made satisfactory progress, and did not give any special anxiety. The temperature this week varied between 98·4° and 100·4°. Pulse-rate fluctuated from 88 to 100 per minute. The patient improved in colour and felt well. The bowels were opened with castor oil and enemata.

On December 25th, *i. e.* a week after the operation, the temperature began to rise, and patient complained of pain in the left side of the abdomen, low down. On 26th temperature rose to 103·8°. The sutures were removed, and on the next day the temperature fell to 98·4°. In spite of the fall of temperature the pulse-rate rose to 126, and remained rapid.

On December 26th one drachm of magnesium sulphate was ordered every hour, followed by enemata, without result. There was now a good deal of abdominal distension, and on the evening of the 26th patient began to be sick. This continued on December 27th, and the patient was put on rectal feeding. On the next day the distension was still marked, and the pain and tenderness below and to the left had increased. The general condition of the patient at this time looked very grave, and the evidence of obstruction being quite definite it was decided to reopen the abdomen. The patient's pulse at this stage was 140, and the temperature 99·°6.

On December 28th an incision was made to the left of the old scar through the outer edge of the rectus. On opening the peritoneum several coils of bowel were found firmly adherent to the uterine stump. There was also a collection of inflammatory exudation on the left side in the lower abdomen which was tracking up to the left loin.

The coils of bowel in this region were in many places covered with lymph. The bowel was separated from the uterine stump and the abdomen was thoroughly washed out, a counter-opening being made in the left lumbar region to ensure drainage. A tube was placed in the abdominal wound and a gauze drain in the loin. The patient bore the operation well, but strychnine was given every four hours after the operation as a prophylactic against shock.

On the evening of the operation a turpentine enema was given, which was followed by the passage of some flatus.

On the following day an olive oil injection, followed by soap and water enema, was given with fair result.

On December 30th patient looked and felt much better. Pulse 110, temperature normal.

On December 31st bowels acted well after aperients. Patient still suffers a good deal from hiccough. From this time on the patient made a gradual though slow recovery. There was a good deal of troublesome constipation for some time, and the tympanites took some time to subside. Eventually, however, she made a good recovery and was discharged from the hospital on February 19th.

Case 3.—A. M—, aged 22 years, was admitted to St. Thomas's Hospital April 6th, 1904. Patient had a normal confinement on March 10th, 1904. On the sixth day of the puerperium the temperature rose to 100°, and a large tender swelling was found in the lower abdomen. About three weeks later a second tender swelling was discovered in the right. Patient had continued in bed, the temperature fluctuating between normal and 100°.

On admission to the hospital patient was very anæmic and sallow complexioned. There were two well-marked elastic tumours—one in the hypogastrium and the other in the right iliac region—separated by a sulcus. The cervix was high up and far back, being situated between

the two tumours. It was thought probable the tumours were dermoid cysts of the ovary.

On April 14th, 1904, the abdomen was opened. The tumour proved to be a bilobed fibro-myoma of uterus—one lobe occupying the anterior wall of the uterus, the other lobe growing between the layer of the right broad ligament. An attempt was first made to enucleate the tumours, and this was accomplished, but, owing to the large sac left after removal into which there was considerable oozing, it was thought best to perform supra-vaginal hysterectomy. The uterine tissues were still very soft, and the sutures had a tendency to cut through. The tumour removed weighed 1 lb. 9 oz., and was undergoing marked necrotic change.

The operation was performed on April 14th, and patient had no shock or other discomfort till the evening of the 17th. The bowels acted well after castor oil on the morning of the 17th. On the evening of the 17th patient began to have abdominal pain and commenced to vomit. She rapidly began to look pinched, and to have the typical abdominal facies. On the morning of the 18th she looked very ill. Temp. 97°, pulse 130. Constant vomiting; no result followed administration of enemata. Drachm doses of sulphate of magnesium were ordered hourly without result.

At 5 p.m. the same day, as there was evident obstruction, I reopened the abdomen by a small incision to the left of the former one. There was a small quantity of serum on opening the peritoneum. On passing the finger into the abdomen a firm tag of omentum was felt at once adherent to the stump, tightly stretched, and constricting a coil of small intestine. This was readily separated, ligatured, and removed, and the wound closed.

On the 19th, *i. e.* the day after the operation, the aspect of the patient had resumed its ordinary placid character. There was a good result after Magn. Sulphate, and the patient subsequently made an excellent recovery.

These are short accounts of the three cases, which have

made a very great impression on me. The occurrence of these cases of intestinal obstruction following on, and the immediate result of a particular operation, is an extremely grave matter. It is true that all my cases recovered, but such occurrences add so greatly to the anxieties which every operator is bound to experience who is engaged in abdominal surgery, that if we can, by any special technique or by choice of operation, minimise the risk of this particular complication, we shall, at any rate, be relieved of one of the most disappointing and dangerous sequelæ which may follow a successful operation.

I may say that up to a few months ago I have practised the operation of supra-vaginal hysterectomy in nearly all cases of fibroids requiring surgical treatment which have come under my care. The anterior and posterior flaps have been brought together over the cervix by a series of interrupted sutures of fine silk. With the results of this operation on the whole I have been very well satisfied. Up to November of this year I have performed 162 abdominal operations for fibroids; 130 of these have been supra-vaginal hysterectomies, 12 have been pan-hysterectomies, and 18 have been myomectomies. Putting aside the 12 pan-hysterectomy operations the three cases of obstruction occurred in 150 cases.

Can we offer any explanation for this?

Is it due to the technique of the operation?

Is is due to the nature of the operation?

Is it due to luck—bad luck?

So far as the technique is concerned I have been in the habit of bringing together the flaps over the stump with a series of interrupted sutures of fine silk introduced in Lembert fashion. It is possible that a reliable absorbable ligature, such as can be obtained at the present day, would be an improvement on fine silk, and a continuous suture bringing together the peritoneal flaps would do away with the possible source of irritation to the peritoneum, which the series of knots in the interrupted suture presents. The more nearly we can restore the peritoneum of the

operation area to its natural smooth unbroken state, the less is the risk of troublesome adhesions.

One knows well enough that in a large number of cases after abdominal operations, adhesions must occur, but the adhesions are of such a kind that the natural peristaltic action of the bowels is not interfered with. I am inclined to think that in my cases of intestinal obstruction following on supra-vaginal hysterectomy, the slightly projecting stump of different consistence to the rest of the pelvic peritoneum, covered by a row of sutures, or the sutured uterus after myomectomy, were important factors in the causation. One is driven to the conclusion that these two operations for fibroids leave the site of operation in a condition which may predispose to troublesome adhesions, which may be followed by obstruction.

Sloughing of the flaps covering in the stumps has been reported to occur in certain cases after supra-vaginal hysterectomy. It is easy to understand, if this is so, how bowel adhesions very readily under these circumstances occur, followed by obstruction or by fatal peritonitis. I do not, however, think that this can be anything but a very rare complication. I have never seen anything suggesting it in any of my operations, and in the three patients in whom I had the opportunity of reopening the abdomen and examining the stump, there was no evidence of any necrotic change.

I have not yet performed a sufficient number of pan-hysterectomy operations to compare results with those of the supra-vaginal operations. The thin peritoneal flaps closing the pelvic floor below, and leaving the surface almost absolutely smooth and free from irregular projections, must be less likely to cause adhesions, and seem to me to be an important point in favour of the pan-hysterectomy operation.

Another point which makes one think that the nature of the operation is a factor in the causation of the obstruction is the freedom from such troubles in other abdominal cases of a similar nature.

After ovariotomy operations difficulties with the bowels are in my experience hardly ever met with. Then, again, after vaginal hysterectomy, I have only on one occasion met with intestinal obstruction in a series of considerably over one hundred cases. In this particular case the patient was going on quite satisfactorily, and on the third day the vaginal plug was removed. Later in the day the patient complained of pain and began to vomit. I saw the patient the next morning, and on vaginal examination found a coil of small intestine in the vagina. This was replaced, and another plug of gauze introduced. Distension of the abdomen rapidly increased, with vomiting, and the case terminated fatally.

After operations for extensive suppurative disease in the pelvis, where extensive raw surfaces denuded of healthy peritoneum are necessarily left, a certain number of unfavourable results from extensive bowel adhesions are almost certain to occur as an inevitable result of the operation.

In clean cases, however, one must consider that intestinal complications following on operations are, to a great extent, preventable, and where they do occur, it behoves one to search carefully for an explanation. Taking clean abdominal cases such as operations for ovarian tumours (non-suppurating) and uncomplicated fibroids, I have come to regard the operations of supra-vaginal hysterectomy and myomectomy as peculiarly liable to be followed by dangerous adhesion of bowel. I should be interested to know whether the Fellows of this Society have met with any cases of these complications after these two operations, in which they have been called upon to reopen the abdomen, or in which intestinal obstruction has been the cause of death.

The diminished liability to bowel adhesion is, I believe, one important advantage of the pan-hysterectomy operation. Before deciding to substitute one operation for another, one must first consider the various advantages or objections. A great deal has been written and opinions have

been very freely expressed on the relative merits of the supra-vaginal and total hysterectomy.

It has been suggested that patients suffer more from shock after pan-hysterectomy. In the large proportion of cases operated upon patients do not suffer any serious shock after either operation. There are three important factors on which shock depends in operations on fibroids: one is the prevention of hæmorrhage, the second is the duration of the operation, and the third is the careful packing of the intestines with hot gauze sponges, so as to prevent exposure. Where hæmorrhage is well controlled, and the operation not unduly prolonged, shock is rarely seen.

In certain cases where there is serious inflammatory mischief of the uterine appendages complicating fibroids, which is not by any means uncommon in fibroids impacted in the pelvis, I should suggest that the supra-vaginal hysterectomy is an easier operation, and one of less risk to the patient. In these cases the cervix is often deeply situated, surrounded by a good deal of cellulitic thickening which prevents it from being drawn up, and very troublesome hæmorrhage is likely to occur during the removal of the cervix. For some of these cases the supra-vaginal operation still has a place.

Where, however, the complete extirpation of the uterus does not increase the risk of the operation, I intend, in future, always to select it.

A good deal has been written about the risk of injuring the ureter in the operation for complete extirpation of the uterus. In the whole of my operative work in cases of vaginal hysterectomy, and in the twelve cases of abdominal pan-hysterectomy, I have never met with this accident. When the peritoneum and bladder have been separated from the cervix and the uterus drawn up, the ureters become still farther removed from the field of operation, although in abdominal operation for cancer of uterus where the cellular tissue is extensively removed injury to ureter is a serious factor. In operating for cases of

fibroids injury to the ureters ought not to occur where proper care is taken.

With a view to diminishing the risk of injury to the ureters I see Mr. Bland-Sutton suggests leaving a shell of cervix, and merely removing the mucous membrane of the cervical canal and the surrounding tissue of the cervix. It seems to me that scooping out the cervical canal in this way is exceedingly likely to be followed by troublesome oozing from the walls, and I do not think it has any advantages over the complete extirpation.

The opinion was expressed by Dr. Lewers, in this Society, that where a small portion of mucous membrane of the lower segment of the uterus is left with the cervix, the patient may continue to have a monthly discharge of blood, and she may not suffer to the same extent from the sudden cessation of menses, which is caused by removal of the uterus. This is a point which is very difficult to prove satisfactorily, as the amount of discomfort caused by removal of the uterus in different patients varies so greatly.

One case which occurred in my own practice a couple of years ago shows the disadvantage of leaving a small portion of the lower uterine segment. The patient, who had been losing very excessively for nearly two years, had supra-vaginal amputation of the uterus performed on July 17th, 1902. The fibroids were adherent in the pelvis which made the operation a very difficult one; the left ovary and tube were removed, the right ovary was left. The patient left the hospital at the end of a month, but very soon the discharge returned, and the continuous bleeding quite prevented her from going back to her domestic duties. Some months later she returned to the hospital, and I removed the cervix with uterine stump *per vaginam*. After this she made a good recovery. This case shows the possible disadvantage in leaving a portion of lower segment of the uterus.

I do not propose in this paper to discuss the question of carcinoma occurring in the cervix after the supra-

vaginal hysterectomy. Suffice it to say that, so far as it occurs, it is an argument in favour of the complete operation of pan-hysterectomy.

In conclusion, I would like to ask the Fellows of this Society for their own experience with regard to obstruction following operations for fibroids.

I would also suggest that in the large bulk of cases the immediate risks of supra-vaginal hysterectomy and pan-hysterectomy are equal.

Where fibroid tumours are complicated by extensive inflammatory disease of the uterine appendages, which is by no means uncommon where the tumour is impacted in the pelvis. I would maintain that supra-vaginal hysterectomy still holds a place as being in many such cases a less serious risk to the patient.

In all other cases, both from the point of view of immediate and ultimate results, pan-hysterectomy is the operation of selection.

Mr. Alban Doran preferred the continuous suture for closing the flaps, and agreed with Dr. Tate as to the objection to the interrupted suture. The great disadvantage of supra-vaginal hysterectomy was the necessity for leaving so many knots in the stump. He gave an enema and a purgative as well on the second day. In his own practice one case of obstruction had occurred in ninety-eight supra-vaginal hysterectomies. It was reported in full in his Harveian Lecture published in the 'Lancet' for February 21st, 1903. In regard to the aim of the operation, the safety and comfort of the patient, and in respect to the danger of obstruction, the Abel-Zweifel theory that a portion of the uterus above the level of the os internum should be saved as well as the ovaries was of importance, as it seemed to lessen the risk of future psychical disturbance. This practice, however, involved the fashioning of a relatively big stump, increasing the chances of intestinal obstruction, as well as other complications. He asked Dr. Tate if the stump, which he removed because bleeding continued after hysterectomy, contained any small interstitial fibroids. Mr. Doran always dissected such growths out of the stump. Uncertainty as to physiological effects when the cervix was removed seemed to be an objection to pan-hysterectomy. The sutured flaps of peritoneum deep in the pelvis might cause obstruction. Von Winckel recently reported a case of pan-hysterectomy ('Monats-

schr. f. Geb. u. Gyn.,' vol. xviii, p. 792) where a large vaginal hernia developed, and the patient complained that she often found herself sitting on her bowels, an eminent instance of a bad intestinal complication.

Dr. Peter Horrocks, whilst congratulating the author on the boldness of his action and the success that followed, did not think that his conclusion that pan-hysterectomy was preferable to supra-vaginal hysterectomy in cases of fibroid tumours of the uterus was warranted. Ever since Baer's operation was introduced into this country he had adopted this method in nearly all cases. Pan-hysterectomy was more difficult to perform, was followed by greater shock, and had a higher mortality. Moreover, it left the pelvic floor in a weaker state. Of Dr. Tate's three cases, only one, the second, could be looked upon as an ordinary fibroid tumour of the uterus with which one could compare supra-vaginal with pan-hysterectomy, at all events, with reference to the question of the frequency of intestinal obstruction following, due to adhesion at the line of incision. For in No. 1 it was a case of myomectomy, a very different operation, and in No. 3 the patient was young (twenty-two) and had recently had a child, leaving the uterus in an incompletely involuted condition, with its walls fatty and friable, and therefore with a greater likelihood of causing trouble along the line of incision. He could not help thinking that Dr. Tate's experience of three cases of intestinal obstruction in 150 operations was much higher than that of most operators. In his own experience he thought one case in 150 operations was nearer the mark, and nearer the average, and if Dr. Tate excluded Nos. 1 and 3 it would leave his results very much the same. Probably interrupted sutures were not so good as a continuous one. His own practice was to use fine silk and to leave as much of the cervix uteri as possible, cutting straight across, and sewing the peritoneum over the stump. As a rule the stumps of the right and left broad ligaments were not covered over by the peritoneum, but were left bare, like the cut end of the pedicle in an ovariotomy, and these seldom, if ever, caused any trouble.

Dr. Galabin said that Dr. Horrocks had referred to him as the first introducer into this country of Baer's operation. He believed, however, that he had to yield precedence to Dr. Cullingworth in this matter, though he had followed him very closely. Dr. Galabin said that he did not think that Dr. Tate had proved that supra-vaginal hysterectomy was necessarily more likely to be followed by intestinal obstruction than pan-hysterectomy. Since Dr. Tate had chosen supra-vaginal hysterectomy in almost all cases up to the last few months, any cases of obstruction which occurred in his practice would naturally follow that operation. But he thought that the method of doing the operation might make a difference. Dr. Tate spoke

of covering the stump with flaps, and he presumed that he meant flaps of uterine tissue. Dr. Galabin never made any flaps, but cut straight across at the narrowest part, a little above or below the internal os, thus getting the minimum of hæmorrhage from the cut surface. If fibroids involved the cervix so that he could not get below them he always chose pan-hysterectomy. He adopted for this an elaborate suture, but thought that it was worth the increased time occupied, as he had never had a case of intestinal obstruction after either supra-vaginal hysterectomy, pan-hysterectomy, or vaginal hysterectomy. He first closed the broad ligaments by uniting their anterior and posterior faces with sutures at the site of the round ligaments and the uterine arteries. He then united the peritoneum in a transverse line, getting a sero-fibrous union by piercing the anterior peritoneum twice, and using a continuous suture of fine silk. The stump was never much larger than a normal cervix, and was covered by stitching the edge of peritoneum left above the bladder in stripping it down. The stump thus made no projection, was mainly covered by bladder, and could come in contact with intestines only at its posterior edge. Care was taken to stitch closely enough to prevent any leakage of blood, and he thought that if the operation was thus performed there could be no greater tendency to intestinal adhesion than after pan-hysterectomy. In that operation he united the peritoneum in precisely the same way, since it kept the structures in a more normal relation than the use of a purse-string suture, and finer silk could be used. Similarly, in vaginal hysterectomy he preferred to stitch the peritoneum so as to fix the pedicles of the broad ligaments in the vagina. In two cases, within two or three years after supra-vaginal hysterectomy in neurotic patients, he had opened the abdomen again to search for the source of pain referred to the region of the ovary left behind. In one no adhesion of any sort was found. In the second there was one adhesion of a knuckle of intestine to the free surface of the ovary. In both cases the line of suture was free and smooth, and no trace of the silk was discoverable.

Dr. Herbert Spencer said that Dr. Tate's paper dealt with two subjects which should be kept distinct—the occurrence of intestinal obstruction after myomectomy and after supra-vaginal amputation with intra-peritoneal treatment of the stump. With regard to the former he asked what was Dr. Tate's method of closing the wound. His own practice was to understitch the vessels, then to pass deep sutures, and finally to sew over the peritoneum with Lembert's sutures of fine silk, and to leave salt solution in the abdomen, which he thought tended to prevent the occurrence of adhesions. He was glad to hear that Dr. Tate had during the last few months given up supra-vaginal amputation in simple cases of fibroids. Personally he had not performed it in any

case for over five years. It was an operation which, in his opinion, ought to have no place in the twentieth century. He was surprised to find that Fellows of the Society were so slow in recognising the advantages of total hysterectomy. He had no doubt that Dr. Tate would soon perform it also in cases of complicated fibroids, for which indeed it was especially suitable. In a paper read two and a half years ago at the Manchester Meeting of the British Medical Association he had called attention to this subject of intestinal obstruction after supra-vaginal amputation, and had published a case of his own. He had also nearly ten years ago, and many times since, directed the Society's attention to Klotz's striking three cases of septic peritonitis from infection of the cervical stitches long after the operation. He also knew that some operators who practised the supra-vaginal amputation had not uncommonly cases in which discharges of pus occurred *per vaginam* after the operation. Hæmorrhage and the presence or development of malignant disease in the stump were other disadvantages of amputation, to which he had called attention in his paper. He hoped that Dr. Tate would follow up his cases and publish the results, for he had no doubt that the reason why total hysterectomy had not more advocates was the false impressions derived from reading lists of picked cases published without any reference to the late results of the operation. He agreed entirely with Dr. Tate that the ureter ought not to be injured in total hysterectomy, and in his remarks on Mr. Bland-Sutton's so-called "modified pan-hysterectomy," which, of course, was not a pan-hysterectomy at all. The bogey of prolapse after total hysterectomy had been introduced, although it did not occur any more than it did after the similar operation for cancer, which was daily performed by the advocates of the partial operation for fibroids. Personally he had never seen a case. He was a little amused at Mr. Doran's idea of a "three or four inch seam" after total hysterectomy. The operation as he performed it with a purse-string suture, which was hidden, left no seam or raw surface, but only smooth peritoneum at the bottom of the pelvis.

Mrs. Boyd agreed in the presence of the knots of interrupted sutures as the possible cause of adhesions, and thought the main point in the technique of supra-vaginal amputation was to bury the cervical stump and also the stumps of the adnexa by continuous suture of the overlying peritoneum. She questioned whether Dr. Tate's second case should be regarded as a case of typical mechanical obstruction, and thought it rather a condition of peritonitis with secondary matting of bowel, brought to a successful issue by Mr. Tate's bold intervention.

Dr. Cullingworth would have liked to hear from Dr. Tate what were the symptoms which, to his mind, indicated the necessity for re-opening the abdomen. Dr. Tate's boldness in

resorting to this measure early had been crowned with success, but, for his own part, he knew no more difficult problem with which an operator could be faced than to have to decide, when the abdomen was becoming distended, and other symptoms pointed to either intestinal paresis or obstruction, how long aperients and enemata ought to be tried before having recourse to exploration of the abdominal cavity. Perhaps, however, that was too large a subject to be discussed that evening. It might, with advantage, have an evening all to itself. Dr. Cullingworth had been somewhat surprised to hear that the Fellows had had so small a percentage of cases of obstruction, by which he meant what the reader of the paper meant, namely cases in which it had been proved either by re-opening the abdomen or by examining the body post mortem that mechanical obstruction, in the form of kink or adhesion, was actually present. He had unfortunately himself had a much larger percentage. He had performed Baer's operation very nearly 100 times, and had had four undoubted cases of genuine intestinal obstruction. He had the notes in his hand, but would not trouble the Society with them at so late an hour. He would only say that in none was it noted that the intestine had become adherent to the line of suture on the uterine stump, which, of course, was the point upon which Dr. Tate's argument rested. Dr. Galabin had alluded to Dr. Tate's mention of flaps, and had inquired what was meant by flaps, stating that it was his own (Dr. Galabin's) practice to cut straight across at the level of the *os internum*. He (the speaker) would like to remind Dr. Galabin that the chief characteristic of Baer's operation was the avoidance of the muscular tissue of the uterus during the suturing and the covering of the stump by flaps of peritoneum, dissected off for the purpose and stitched together with their edges turned inwards, so that their serous surfaces were in apposition. As a matter of practice, it was often found desirable to thicken and strengthen the flaps by dissecting off a thin layer of muscular tissue along with the peritoneum. The sutures, however, should penetrate peritoneum only. In regard to the relative merits of supra-vaginal hysterectomy and so-called pan-hysterectomy, he (Dr. Cullingworth) had an open mind. He had had little, if any, personal experience of pan-hysterectomy, so had no means of comparing the one with the other in his own practice. But there were two or three points that it behoved the advocates of pan-hysterectomy to bear in mind. First as to statistics. He did not pin his faith on mortality statistics, but they could not wholly be left out of account. He held in his hand a paper by Dr. C. P. Noble, of Philadelphia, published in 1901 in the 'American Journal of Obstetrics,' in which there occurred the following passage:—"In a series of 345 cases published by myself in 1897, the mortality of hysterectomy by supra-vaginal

amputation in the hands of five American gynæcologists was 4·9 per cent; in a series of 100 total hysterectomies the mortality was 10 per cent. In a collection by Olshausen ('Veit's Handbuch,' 1897, p. 713) of 806 cases of supra-vaginal amputation the mortality was 5·6 per cent., contrasted with a mortality of 9·6 per cent. in a collection of 920 cases of total extirpation." The accuracy of these figures had, he believed, never been called in question, and they were certainly very striking. Then again, Dr. Tate had spoken of the simple transverse wound left after total hysterectomy at the bottom of the pelvis as affording little or no risk of dangerous intestinal adhesion. But was that so? Some years ago he (the speaker) had brought before the Society four cases of vaginal hysterectomy for cancer. One of these cases was immediately fatal. Of the remaining three he had furnished the after-histories in a short supplementary paper. Two out of the three had died from intestinal obstruction the remote result of the operation. Here, at any rate, was no projecting mass like the uterine stump to provoke the fatal adhesion. Lastly, the length of time occupied by the operation seemed to him a very important point. Most operators agreed that total extirpation involved a longer operation. If that were so, undoubtedly it was an argument against it, for there could be no doubt but that the length of time occupied by the operation was an important factor in determining the immediate result. Three or four years ago he was appealed to by Mr. Stanmore Bishop, of Manchester, for some account of his operative work in connection with uterine fibro-myomata and of his results. He then took occasion to communicate as far as possible with every patient upon whom he had successfully operated, and received replies from all but one or two. With scarcely an exception, the patients spoke of themselves as being in excellent health, and glad that they had undergone the operation. In fact, his experience was that after no gynæcological operation involving abdominal section did the patients who survived the operation itself experience the same sense of well-being as after the removal of the body of the uterus for fibro-myomata. He had no doubt the same was true after total extirpation. He congratulated Dr. Tate on his valuable paper, and was much interested in the account he had given of his conversion. If, however, that conversion really rested on the evidence brought forward in that evening's paper, he could not help feeling that it had taken place on very slender grounds.

Mr. Malcolm thought Dr. Tate's cases particularly interesting, in that they illustrated one of the advantages of treatment by purgatives and enemata over the opiate treatment formerly in vogue. He looked upon these cases as a modern manifestation of the old conditions that led to death from paresis or obstruction of the intestines under treatment by opiates. Modern

treatment cured most if not all cases of paresis, but did not cure those in which there was a definite obstruction which would not give way. He had written, many years before, that treatment by purgatives in such cases would enable us to "so clinch the diagnosis that the surgeon must at once consider the question of reopening the abdomen in the expectation of finding a definite mechanical obstruction," 'Med. Chir. Trans.,' vol. lxxi. p. 64. Under opiate treatment, whether paralysis or obstruction was the chief cause of mischief, if the symptoms continued there was great difficulty in deciding whether to reopen the abdomen or not. When this course was taken the surgeon did what he could to relieve obstruction, the patient was put back to bed and more opium was given, so that nature did not get a chance of assisting to put matters right. He remembered hearing of only one case of successful operation for obstructive symptoms arising soon after an abdominal section under treatment by opium. In that case there was a very slight adhesion immediately under the abdominal incision and easily separated. But this was hardly a case in point, for the second operation did not take place until the thirteenth or fourteenth day after the first. There was little doubt that the longer the interval between the first abdominal section and the development of symptoms of obstruction of the intestines the greater the chances of effecting a cure were if a second operation was performed. He was inclined to think that the fact that these cases all followed operations for the treatment of uterine fibroids was due to one of those curious coincidences that constantly occur. Obstructive symptoms might arise from adhesions to any surface. He had never had a case of death from adhesions to the stump of a uterus, but in the first case of fibroid tumour he operated on the patient died from adhesions of a very small area of small intestine to the pedicle of the broad ligament which was left in the peritoneal sac, the stump of the uterus being secured in a serre-nœud outside the abdominal wall, according to the old-fashioned method. The case was treated at first by opiates, and on the second day by purgatives, but the patient died on the third day, and, after death, an acute obstruction was found to be caused by the adhesions. If he had had the courage of his opinions the abdomen would have been opened, but at that time these conditions were generally attributed to peritonitis, and the symptoms simulated those of an acute inflammation. He fully agreed with Dr. Tate and Dr. Spencer that removal of the cervix with the uterus was a more satisfactory operation than that by which the cervix was left in the body. Convalescence was more smooth, but he thought the operation was, in many cases, decidedly more difficult and therefore more dangerous, and it was very often in those cases in which the operation was most difficult, when there had been much inflammatory mischief in

the parts, that the advantages of getting the cervix away and thereby removing a source of irritation were most obvious. He thought that Dr. Tate was to be congratulated very warmly on the success of the treatment of these cases.

Dr. Lewers said that he thought it must be admitted that there was a greater risk of intestinal obstruction following soon after abdominal hysterectomy than after ovariotomy. The risk, in his experience, was a very small one, as in all his cases of abdominal section intestinal obstruction had only happened twice, and in both cases after an abdominal hysterectomy. In one case—a supra-vaginal hysterectomy—a coil of small intestine adhered to the seam over the stump across the floor of the pelvis. In the other case of hysterectomy by the same method intestinal obstruction occurred a month after the operation by a coil of intestine slipping through a hole in the omentum. It seemed to him that the absence of the body of the uterus after hysterectomy, by leaving the pelvis more empty than after an ovariotomy, formed a reasonable explanation of the greater risk of this accident in cases of hysterectomy. An unusually long mesentery would naturally also predispose to it. He always made a practice, as far as possible, of drawing the omentum well down over the intestines at the end of every abdominal section. In the large majority of his hysterectomies for fibroids supra-vaginal hysterectomy, leaving the cervix, was the operation he had adopted. He had done a moderate number of abdominal pan-hysterectomies for fibroids, but the operation took longer, and to his mind presented no advantage over the former operation. He had never had any trouble after supra-vaginal hysterectomy due to suppuration in the neighbourhood of the stump, such as had been referred to by Dr. Spencer.

Dr. Tate did not believe there was any actual advantage to be gained by leaving the cervix, so far as the integrity of the pelvic floor was concerned. After the operation of vaginal hysterectomy, it was not usual to see any unfavourable sequelæ due to the removal of the whole uterus. In the operation of supra-vaginal hysterectomy, he was in the habit of making small flaps of peritoneum with a little subjacent muscular tissue, derived from the lower uterine segment. He did not think much value could be attached to the statistics of Noble and Olshausen which extended back over a number of years, when the methods of operating were very different to what they are at the present time. Although he was strongly in favour of pan-hysterectomy as the routine operation in cases of fibroids, he was still of opinion that the supra-vaginal operation was the safer method in certain cases.

INDEX.

PAGE

Abdominal section for abscess of the uterus developing during the puerperium (A. W. W. Lea) . . . 7

—— for dermoid cyst of the ovary five years after causing obstruction to labour (W. W. H. Tate) . . 344

Abscess in the uterus (W. F. Victor Bonney) . . 2

—— of the uterus developing during the puerperium; rupture into the peritoneal cavity; abdominal section; recovery (A. W. W. Lea) 7

Address (*Annual*) *of the President*, Edward Malins, M.D., February 3rd, 1904 67

Adeno-myoma, diffuse, of uterus, (W. W. H. Tate) . . 141

—— of the uterus (F. E. Taylor) . . . 188

Annual General Meeting, February 3rd, 1904 . . 62

Bartlett (Hedley C.), lithopædion of fourteen years' duration successfully removed (shown) . . . 200

Bell (R. Hamilton), cyst in connection with the right Fallopian tube, arising probably from an accessory Fallopian tube (shown) 21

—— torsion of the pedicle in hydrosalpinx, and other morbid conditions of the Fallopian tube . . . 152

—— *Remarks* in reply 177

Berkeley (Comyns), parovarian cyst with twisted pedicle (shown) 242

Blacker (G. F.), chorionepithelioma of the uterus, with secondary growths in the vagina, the lungs, and the liver (shown) 55

—— *Remarks* in discussion on W. W. H. Tate's specimen of two cases of diffuse adeno-myoma of uterus . . 144

—— —— in discussion on Alban Doran's paper on hæmatoma and hæmatocele 226

Bland-Sutton (J.), acute axial rotation of a calcified fibroid of the uterus (shown) 149

PAGE

Bland-Sutton (J.), ovarian dermoid with a twisted pedicle six inches in length (shown) 147
—— pregnancy in a uterus with fibroids: panhysterectomy during labour in the seventh month (shown) . . 238
—— *Remarks* in discussion on R. H. Bell's paper on torsion of the pedicle in hydrosalpinx, and other morbid conditions of the Fallopian tube 176
—— —— in discussion on C. J. Cullingworth and H. H. Clutton's notes on a case of hydatids of, or connected with, both ovaries, right broad ligament, liver, omentum, and other parts 262
Bonney (W. F. Victor), abscess in the uterus (shown) . 2
Boxall (Robert), acute inversion of the uterus: spontaneous reposition 292
—— *Remarks* in reply 297
—— —— in discussion on H. Cripps's and H. Williamson's paper on two cases involving the site of impregnation . 104
—— —— in discussion on A. J. Sturmer's forty-one cases of puerperal eclampsia treated by thyroid extract . 136
—— —— in discussion on W. W. H. Tate's specimen of fibro-myoma of uterus with extensive carcinoma of body of uterus and fibroma of ovary . . . 141
—— —— in discussion on A. W. Sikes's specimen of three cases of variation of the posterior fontanelle in children . 272
Boyd (Florence N.), fibroid of broad ligament (shown) . 348
—— necrobiotic fibroid (shown) 198
—— pregnant uterus with cancerous cervix removed by panhysterectomy (shown) 345
—— *Remarks* in reply 346, 347
—— two cases of abdominal hysterectomy for fibroids, complicated by pregnancy; with specimens . . 106
—— *Remarks* in discussion on W. W. H. Tate's paper on three cases of intestinal obstruction following operations for fibroid tumour of uterus, with special reference to the choice of operation 406
Briggs (H.), primary cancer of the right Fallopian tube; right ovary normal (shown) 60
—— *Remarks* in discussion on H. R. Spencer's paper on three cases of cancer of the cervix, complicating labour in advanced pregnancy, the patients remaining well eleven, eight and a half, and eight years after high amputation of the cervix 379

PAGE

Broad ligament, degenerated fibro-myoma weighing over seventeen pounds enucleated from, nine hours before delivery at term (H. R. Spencer) . . . 122
—— fibroid of (F. N. Boyd) 348
—— hydatids of, or connected with, right (C. J. Cullingworth and H. H. Clutton) 254
Brook (W. H. B.), further note, case of primary tuberculosis of cervix 265
Butler-Smythe (Albert Charles), *Remarks* in discussion on A. Doran's and H. Williamson's specimen of necrobiotic uterus associated with recent pregnancy . . 279

Cancer and fibro-myoma coexisting in the body of the uterus (M. Handfield-Jones) 305
—— of both ovaries primary to carcinoma in the muscular wall of the uterus (C. Lockyer) . . . 302
—— of the cervix, three cases of, complicating labour in advanced pregnancy, the patients remaining well eleven, eight and a half, and eight years after high amputation of the cervix (H. R. Spencer) . . . 355
—— of the body of the uterus simulating fibroid in a woman aged thirty-six (H. R. Spencer) . . . 235
—— primary, of the right Fallopian tube; right ovary normal (H. Briggs) 60
Carcinoma in the muscular wall of the uterus secondary to cancer of both ovaries (C. Lockyer) . . . 302
—— of body of uterus, with fibro-myoma and fibroma of ovary (W. W. H. Tate) 139
—— of the body in a uterus, with multiple fibroids (A. H. N. Lewers) 266
—— of the ovary of unusual type (C. Lockyer) . . 349
—— primary, of both ovaries (C. Lockyer) . . 229
Cæsarean section in cases of contracted pelvis, based upon a series of thirty cases (J. M. Munro Kerr) . . 309
Cervix, see *Uterus* (cervix of).
Chorionepithelioma of the uterus, with secondary growths in the vagina, the lungs, and the liver (G. F. Blacker) . 55
Clutton (H. H.), *Remarks* in reply . . . 262
—— see *Cullingworth, Charles J.*
Cripps (Harrison) and Herbert Williamson, two cases involving the question of the site of impregnation . 88

PAGE

Cullingworth (Charles J.), and H. H. Clutton, notes on a case of hydatids of, or connected with, both ovaries, right broad ligament, liver, omentum, mesentery, and other parts (shown) 254

Cullingworth (Charles J.), *Remarks* in reply . . 263

—— —— in discussion on Mary A. D. Scharlieb's specimen of unruptured tubal gestation . . . 55

—— —— in discussion on M. Handfield-Jones's two specimens of extra-uterine fœtation 88

—— —— in discussion on H. Cripps's and H. Williamson's paper on two cases involving the site of impregnation . 104

—— —— in discussion on F. N. Boyd's paper on two cases of abdominal hysterectomy for fibroids, complicated by pregnancy 117

—— —— in discussion on Alban Doran's paper on hæmatoma and hæmatocele 224

—— —— in discussion on M. Handfield-Jones's specimen of cancer and fibro-myoma co-existing in the body of the uterus 306

—— —— in discussion on M. Handfield-Jones's specimen of fibroid of the uterus with cystic degeneration of the surrounding tissues 308

—— —— in discussion on J. M. Munro Kerr's paper on certain details regarding the operation of Cæsarean section in cases of contracted pelvis, based upon a series of thirty cases 334

—— —— in discussion on A. J. Sturmer's specimen of abdominal gestation 390

—— —— in discussion on W. W. H. Tate's paper on three cases of intestinal obstruction following operations for fibroid tumour of uterus, with special reference to the choice of operation 406

Cyst, dermoid, of the ovary removed by abdominal section five years after causing obstruction to labour (W. W. H. Tate) 344

Cystoma, double symmetrical, of unusual origin and connections (J. H. Dauber) 341

Cyst in connection with the right Fallopian tube, arising probably from an accessory Fallopian tube (R. Hamilton Bell) 21

—— parovarian, with twisted pedicle (C. Berkeley) . 242

PAGE
DAUBER (John H.), double symmetrical cystoma of unusual origin and connections (shown) . . . 341
Degeneration, sarcomatous, in fibro-myoma of uterus (P. Horrocks) 184
Delivery at term, degenerated fibro-myoma weighing over seventeen pounds enucleated from the broad ligament nine hours before (H. R. Spencer) . . . 122
—— sloughing of the central part of a uterine fibro-myoma shortly after (J. D. Malcolm) . . . 15
Dermoid cyst, see *Cyst*.
DORAN (Alban) and H. WILLIAMSON, necrobiotic uterus associated with recent pregnancy (shown) . . . 274
DORAN (Alban), *Remarks* in reply . . . 280
—— hæmatoma and hæmatocele; a study of two cases of early tubal pregnancy 206
—— *Remarks* in reply 227
—— pregnant fibroid uteri removed by operation (shown) . 119
—— solid mesenteric tumour (fibro-myoma) weighing thirty pounds (shown) 145
—— *Remarks* in discussion on W. A. Meredith's specimen of fibro-myoma of the cervix uteri, removed by abdominal panhysterectomy 13
—— —— in discussion on J. D. Malcolm's specimen of sloughing of the central part of a uterine fibro-myoma shortly after delivery 19
—— —— in discussion on H. R. Spencer's paper on fibro-myoma of the intra-abdominal portion of the round ligament of the uterus 50
—— —— in discussion on Mary A. D. Scharlieb's specimen of unruptured tubal gestation . . . 55
—— —— in discussion on H. Briggs's specimen of primary cancer of the right Fallopian tube: right ovary normal . 61
—— —— in discussion on H. Cripps's and H. Williamson's paper on two cases involving the site of impregnation . 101
—— —— in discussion on R. H. Bell's paper on torsion of the pedicle in hydrosalpinx, and other morbid conditions of the Fallopian tube 176
—— —— in discussion on P. Horrocks's specimen of fibro-myoma of uterus undergoing sarcomatous degeneration . 187
—— —— in discussion on W. W. H. Tate's specimen of fibro-myoma and cystic disease coexisting in the same ovary 273

PAGE

Doran (Alban), *Remarks* in discussion on W. W. H. Tate's paper on three cases of intestinal obstruction following operations for fibroid tumour of uterus, with special reference to the choice of operation . . . 403

Eclampsia, puerperal, treated by thyroid extract (A. J. Sturmer) 126
Ectopic gestation, see *Pregnancy.*
Eden (T. W.), primary hydatid disease (echinococcus) of the Fallopian tube 243
—— *Remarks* in discussion on H. Cripps's and H. Williamson's paper on two cases involving the site of impregnation 103
—— —— in discussion on P. Horrocks's specimen of fibromyoma of uterus undergoing sarcomatous degeneration . 187
—— —— in discussion on J. Bland-Sutton's specimen of pregnancy in a uterus with fibroids: panhysterectomy during labour in the seventh month 241
Election of new Fellows . 1, 53, 87, 126, 178, 229, 264, 299, 339

Fairbairn (John S.), necrobiotic fibroid removed from a recently delivered patient aged twenty-two (shown) . 194
—— *Remarks* in discussion on A. Doran's and H. Williamson's specimen of necrobiotic uterus associated with recent pregnancy 279
—— —— in discussion on F. E. Taylor's specimen of fibroma of the ovary 282
Fallopian tube, cyst in connection with the right, arising probably from an accessory (R. H. Bell) . . 21
—— primary cancer of right; right ovary normal (H. Briggs) 60
—— primary hydatid disease (echinococcus) of (T. W. Eden) 243
—— torsion of the pedicle in hydrosalpinx and other morbid conditions of (R. H. Bell) 152
Fallopian tubes, tuberculous disease of cervix and (W. W. H. Tate) 138
Fellows, see *Lists, Elections.*
—— Honorary, election of 65
Fibroids, see *Tumours* (fibroid).
Fibroma of the ovary (F. E. Taylor) . . . 280
Fibro-myoma and cancer coexisting in the body of the uterus (M. Handfield-Jones) 305

PAGE

Fibro-myoma and cystic disease coexisting in the same ovary (W. W. H. Tate) 273
—— degenerated, weighing over seventeen pounds enucleated from the broad ligament nine hours before delivery at term (H. R. Spencer) 122
—— of the cervix uteri removed by abdominal panhysterectomy (W. A. Meredith) 12
—— of the intra-abdominal portion of the round ligament of the uterus (H. R. Spencer) 26
—— of the uterus undergoing sarcomatous degeneration (P. Horrocks) 184
—— —— with extensive carcinoma of body of uterus, and fibroma of ovary (W. W. H. Tate) . . . 139
—— —— with sloughing of the central part shortly after delivery (J. D. Malcolm) 15
—— solid mesenteric tumour, weighing thirty pounds (A. Doran) 145
Fœtation, see *Pregnancy*.
Fœtus, see *Monsters*.
Fœtuses, on sacs containing, and lying free in the peritoneal cavity of a rabbit (M. S. Pembrey and G. Bellingham Smith) 283
Fontanelle, variation of the posterior, in children (A. W. Sikes) 272

Galabin (Alfred Lewis), *Remarks* in discussion on H. Cripps's and H. Williamson's paper on two cases involving the site of impregnation 104
—— —— in discussion on A. H. N. Lewers's specimen of uterus with carcinoma of the body and multiple fibroids . 268
—— —— in discussion on R. Boxall's note on acute inversion of the uterus; spontaneous reposition . . 296
—— —— in discussion on W. W. H. Tate's paper on three cases of intestinal obstruction following operations for fibroid tumour of uterus, with special reference to the choice of operation 404
Galvano-cautery knife (H. R. Spencer) . . . 353
Gestation, see *Pregnancy*.
Griffith (W. S. A.), *Remarks* in discussion on J. M. Munro Kerr's paper on certain details regarding the operation of Cæsarean section in cases of contracted pelvis, based upon a series of thirty cases 331

PAGE

GRIFFITH (W. S. A.), *Remarks* in discussion on H. R. Spencer's paper on three cases of cancer of the cervix, complicating labour in advanced pregnancy, the patients remaining well eleven, eight and a half, and eight years after high amputation of the cervix . . . 379

Hæmatocele and hæmatoma; a study of two cases of early tubal pregnancy (A. Doran) 206
Hæmatoma and hæmatocele; a study of two cases of early tubal pregnancy (A. Doran) 206
HANDFIELD-JONES (M.), cancer and fibro-myoma coexisting in the body of the uterus (shown) . . . 305
—— fibroid of the uterus with cystic degeneration of the surrounding tissues (shown) 307
—— two specimens of extra-uterine fœtation (shown) . 88
—— *Remarks* in discussion on P. Horrocks's specimen of fibro-myoma of uterus undergoing sarcomatous degeneration 186
—— —— in discussion on J. Bland-Sutton's specimen of pregnancy in a uterus with fibroids: panhysterectomy during labour in the seventh month . . . 241
—— —— in discussion on H. R. Spencer's paper on three cases of cancer of the cervix complicating labour in advanced pregnancy, the patients remaining well eleven, eight and a half, and eight years after high amputation of the cervix 379
HANDLEY (W. S.), *Remarks* in discussion on H. R. Spencer's paper on fibro-myoma of the intra-abdominal portion of the round ligament of the uterus . . . 50
HERMAN (G. Ernest), *Remarks* in discussion on H. Cripps's and H. Williamson's paper on two cases involving the site of impregnation 103
—— —— in discussion on A. J. Sturmer's forty-one cases of puerperal eclampsia treated by thyroid extract . . 135
—— —— in discussion on M. Handfield-Jones's specimen of cancer and fibro-myoma coexisting in the body of the uterus 306
—— —— in discussion on J. M. Munro Kerr's paper on certain details regarding the operation of Cæsarean section in cases of contracted pelvis, based upon a series of thirty cases 330

PAGE

HERMAN (G. E.), *Remarks* in discussion on H. R. Spencer's paper on three cases of cancer of the cervix complicating labour in advanced pregnancy, the patients remaining well eleven, eight and a half, and eight years after high amputation of the cervix 378

HORROCKS (Peter), fibro-myoma of the uterus undergoing sarcomatous degeneration (shown) 184

—— *Remarks* in reply 187

—— twin monster (shown) 183

—— *Remarks* in discussion on W. W. H. Tate's specimen of fibro-myoma of uterus with extensive carcinoma of body of uterus, and fibroma of ovary 141

—— —— in discussion on Alban Doran's paper on hæmatoma and hæmatocele 223

—— —— in discussion on W. W. H. Tate's paper on three cases of intestinal obstruction following operations for fibroid tumour of uterus, with special reference to the choice of operation 404

Hydatid disease, primary (echinococcus), of the Fallopian tube (T. W. Eden) 243

Hydatids of, or connected with, both ovaries, right broad ligament, liver, omentum, mesentery, and other parts (C. J. Cullingworth and H. H. Clutton) . . 254

Hydrosalpinx, torsion of the pedicle in, and other morbid conditions of the Fallopian tube (R. H. Bell) . . 152

Hysterectomy, two cases of abdominal, for fibroids, complicated by pregnancy; with specimens (F. N. Boyd) . 106

Impregnation, two cases involving the question of the site of (H. Cripps and H. Williamson) 89

Intestine, three cases of obstruction of, following operations for fibroid tumour of uterus, with special reference to the choice of operation (W. W. H. Tate) . . . 391

Inversion, acute, of the uterus; spontaneous reposition (R. Boxall) 292

Jenks, Edward W., M.D., Detroit, obituary notice of . 78

Kempster, William Henry, M.D.St. And. Clapham Common, obituary notice of 79

PAGE

Kerr (John Martin Munro), certain details regarding the operation of Cæsarean section in cases of contracted pelvis, based upon a series of thirty cases . . 309
—— *Remarks* in reply 336

Labour, see *Parturition*.
Laws, alterations in 64
Lea (Arnold W. W.), abscess of the uterus developing during the puerperium; rupture into the peritoneal cavity; abdominal section; recovery (shown) . . . 7
Lewers (A. H. N.), uterus with carcinoma of the body and multiple fibroids (shown) 266
—— *Remarks* in reply 269
—— —— in discussion on F. N. Boyd's paper on two cases of abdominal hysterectomy for fibroids, complicated by pregnancy 117
—— —— in discussion on R. H. Bell's paper on torsion of the pedicle in hydrosalpinx, and other morbid conditions of the Fallopian tube 176
—— —— in discussion on W. W. H. Tate's paper on three cases of intestinal obstruction following operations for fibroid tumour of uterus, with special reference to the choice of operation 410
Ligament, round, of the uterus, fibro-myoma of the intra-abdominal portion of (H. R. Spencer) . . . 26
List of Officers elected for 1904 65
—— —— *for* 1905 v
—— *of past Presidents* ix
—— *of Referees of Papers for* 1905 . . . x
—— *of Standing Committees* vii
—— *of Honorary Fellows* ix
—— *of Ordinary Fellows* xiii
—— *of Deceased Fellows* [with obituary notices, which see]
Lithopædion of fourteen years' duration successfully removed (H. C. Bartlett) 200
Liver, chorionepithelioma of uterus, with secondary growths in (G. F. Blacker) 55
—— hydatids of, or connected with (C. J. Cullingworth and H. H. Clutton) 254
Lockyer (Cuthbert), carcinoma in the muscular wall of the uterus secondary to cancer of both ovaries (shown) . 302
—— primary carcinoma of both ovaries (shown) . . 229

PAGE
Lockyer (C), uniovular twins (shown) . . . 191
—— *Remarks* in discussion on P. Horrocks's specimen of twin monster 183
—— —— in discussion on F. N. Boyd's specimen of pregnant uterus with cancerous cervix removed by panhysterectomy 346
—— carcinoma of the ovary of unusual type (shown) . 349
—— *Remarks* in discussion on H. R. Spencer's new galvanocautery 354
—— —— in discussion on H. R. Spencer's paper on three cases of cancer of the cervix complicating labour in advanced pregnancy, the patients remaining well eleven, eight and a half, and eight years after high amputation of the cervix 380
Lungs, chorionepithelioma of uterus with secondary growths in (G. F. Blacker) 55

Malcolm (John D.), sloughing of the central part of a uterine fibro-myoma shortly after delivery (shown) . 15
—— *Remarks* in discussion on W. W. H. Tate's paper on three cases of intestinal obstruction following operations for fibroid tumour of uterus, with special reference to the choice of operation 408
Malins (Edward), *Annual Address* as President . . 67
—— *Remarks* in discussion on H. Cripps's and H. Williamson's paper on two cases involving the site of impregnation 103
—— —— in discussion on A. J. Sturmer's forty-one cases of puerperal eclampsia treated by thyroid extract . . 137
—— —— in discussion on C. J. Cullingworth's and H. H. Clutton's notes on a case of hydatids of, or connected with, both ovaries, right broad ligament, liver, omentum, mesentery, and other parts 262
—— —— in discussion on J. M. Munro Kerr's paper on certain details regarding the operation of Cæsarean section in cases of contracted pelvis, based upon a series of thirty cases 330
Maurice (W. J.), *Remarks* in discussion on C. Lockyer's specimen of primary carcinoma of both ovaries . 233
McCann (Frederick John), *Remarks* in discussion on R. H. Bell's paper on torsion of the pedicle in hydrosalpinx, and other morbid conditions of the Fallopian tube 176

PAGE

Meredith (W. A.), fibro-myoma of the cervix uteri, removed by abdominal panhysterectomy (shown) . . 12
Mesentery, hydatids of, or connected with (C. J. Cullingworth and H. H. Clutton) 254
Mole, tubal (C. E. Purslow) 271
Monster, twin, (P. Horrocks) 183

Nicholson (Harry Oliphant), *Remarks* in discussion on A. J. Sturmer's forty-one cases of puerperal eclampsia treated by thyroid extract 136

Obituary notices of Deceased Fellows:
Thomas, Thomas Gaillard, M.D., New York (Hon. Fellow) 77
Wallace, R. J., M.D., Calcutta . . . 78
Jenks, Edward W., M.D., Detroit . . . 78
Tait, Edward Wilmshurst, M.R.C.S., Hampstead . 78
Stiven, Edward William Flemyng, M.D.Ed., Harrow-on-the-Hill 78
Kempster, William Henry, M.D.St. And., Clapham Common 79
Swayne, John Griffiths, M.D.Lond., Clifton . . 79
Playfair, William Smoult, M.D.Ed., St. Andrews . 80
Omentum, hydatids of, or connected with (C. J. Cullingworth and H. H. Clutton) 254
Ovary, carcinoma of, of unusual type (C. Lockyer) . . 349
—— dermoid cyst of, removed by abdominal section five years after causing obstruction to labour (W. W. H. Tate) . 344
—— fibroma of (F. E. Taylor) 280
—— fibroma of, with fibro-myoma of uterus with extensive carcinoma of body of uterus (W. W. H. Tate) . . 139
—— fibro-myoma and cystic disease coexisting in the same (W. W. H. Tate) 273
—— right, normal, in primary cancer of the right Fallopian tube (H. Briggs) 60
Ovaries, cancer of both, primary to carcinoma in the muscular wall of the uterus (C. Lockyer) . . . 302
—— hydatids of, or connected with, both (C. J. Cullingworth and H. H. Clutton) 254
—— primary carcinoma of both (C. Lockyer) . . 229
Panhysterectomy, abdominal, for removal of fibro-myoma of the cervix uteri (W. A. Meredith) . . . 12

PAGE
Panhysterectomy during labour in the seventh month in a pregnancy in a uterus with fibroids (J. Bland-Sutton) . 238
—— for removal of pregnant uterus with cancerous cervix (F. N. Boyd) 345
Parturition, dermoid cyst of ovary, removed by abdominal section five years after causing obstruction to labour (W. W. H. Tate) 344
—— in the seventh month, panhysterectomy during (J. Bland-Sutton) 238
—— three cases of cancer of the cervix complicating, in advanced pregnancy, the patients remaining well eleven, eight and a half, and eight years after high amputation of the cervix (H. R. Spencer) . . . 355
Pedicle, torsion of, in hydrosalpinx, and other morbid conditions of the Fallopian tube (R. H. Bell) . . 152
—— twisted, in a parovarian cyst (C. Berkeley) . . 242
—— —— of an ovarian dermoid six inches in length (J. Bland-Sutton) 147
Pelvis, contracted, Cæsarean section in cases of (J. M. Munro Kerr) 309
Pembrey (M. S.) and G. Bellingham Smith, on sacs containing fœtuses and lying free in the peritoneal cavity of a rabbit 283
Playfair, William Smoult, M.D.Ed., St. Andrew's, obituary notice of 80
Pregnancy, abdominal (A. J. Sturmer) . . . 385
—— complicating two cases of abdominal hysterectomy for fibroids (F. N. Boyd) 106
—— early tubal, with hæmatoma and hæmatocele (A. Doran) 206
—— in a uterus, with fibroids; panhysterectomy during labour in the seventh month (J. Bland-Sutton) . . 238
—— necrobiotic uterus associated with recent (A. Doran and H. Williamson) 274
—— two specimens of extra-uterine . . . 88
—— unruptured tubal (M. A. D. Scharlieb) . . 54
Puerperium, abscess of uterus developing during; rupture into the peritoneal cavity; abdominal section; recovery (A. W. W. Lea) 7
Purslow (Charles Edwin), cystic tumour of uterus (shown) . 269
—— tubal mole (shown) 271
Pyosalpinx, unsuspected tuberculous salpingitis and (J. H. Targett) 20

PAGE

Rabbit, sacs containing fœtuses and lying free in the peritoneal cavity of (M. S. Pembrey and G. Bellingham Smith) 283

Report (audited) of the Treasurer for 1903 . . 62, 63

—— *of the Chairman of the Board for the Examination of Midwives* 64

—— *of the Hon. Librarian for* 1903 . . . 62

—— *of the Pathology Committee on W. A. Meredith's specimen of cervical fibroid* 14

—— —— *on W. W. H. Tate's two specimens of diffuse adenomyoma of the uterus* (*p.* 141) 178

—— —— *on P. Horrocks's specimen of fibro-myoma of the uterus undergoing sarcomatous degeneration* (*p.* 184) . 265

—— —— *on H. R. Spencer's specimen of cancer of the body of the uterus simulating fibroid* (*p.* 235) . . . 265

—— —— *on C. E. Purslow's specimen of cystic tumour of uterus* (*p.* 269) 339

—— —— *on C. E. Purslow's specimen of tubal mole* (*p.* 271) . 340

—— —— *on Frank E. Taylor's specimen of fibroma of the ovary* (*p.* 280) 341

—— —— *on M. Handfield-Jones's specimen of fibroid tumour of the uterus and cystic disease of the surrounding tissues* (*p.* 307) 383

—— —— *on J. H. Dauber's specimen of double symmetrical cystoma of unusual origin and connections* (*p.* 341) . 384

—— ——, *on F. N. Boyd's specimen of fibroma of the ovary* (*p.* 348) 384

Rotation, acute axial, of a calcified fibroid of the uterus (J. Bland-Sutton) 149

Routh (Amand), *Remarks* in discussion on A. W. W. Lea's specimen of abscess of the uterus developing during the puerperium 7

—— —— in discussion on J. D. Malcolm's specimen of sloughing of the central part of a uterine fibro-myoma shortly after delivery 19

—— —— in discussion on F. N. Boyd's paper on two cases of abdominal hysterectomy for fibroids, complicated by pregnancy 116

—— —— in discussion on Alban Doran's paper on hæmatoma and hæmatocele 226

—— —— in discussion on A. H. N. Lewers's specimen of uterus, with carcinoma of the body and multiple fibroids . 268

PAGE

Routh (Amand), *Remarks* in discussion on A. Doran's and H. Williamson's specimen of necrobiotic uterus associated with pregnancy 279
—— —— in discussion on A. J. Sturmer's specimen of abdominal gestation 290
—— —— in discussion on M. S. Pembrey's and G. Bellingham Smith's paper on sacs containing fœtuses and lying free in the peritoneal cavity of a rabbit . . . 291
—— —— in discussion on J. M. Munro Kerr's paper on certain details regarding the operation of Cæsarean section in cases of contracted pelvis, based upon a series of thirty cases 332
—— —— in discussion on H. R. Spencer's new galvano-cautery 354
—— —— in discussion on H. R. Spencer's paper on three cases of cancer of the cervix complicating labour in advanced pregnancy, the patients remaining well eleven, eight and a half, and eight years after high amputation of the cervix 379

Sacs containing fœtuses and lying free in the peritoneal cavity of a rabbit (M. S. Pembrey and G. Bellingham Smith) 283
Salpingitis, unsuspected tuberculous, and pyosalpinx (J. H. Targett) 20
Scharlieb (Mary A. D.), unruptured tubal gestation (shown) 54
—— *Remarks* in discussion on A. H. N. Lewers's specimen of uterus with carcinoma of the body and multiple fibroids 268
Sikes (A. W.), three cases of variation of the posterior fontanelle in children (shown) 272
Sloughing of the central part of a uterine fibro-myoma shortly after delivery (J. D. Malcolm) . . . 15
Smith (Heywood), *Remarks* in discussion on H. Briggs's specimen of primary cancer of the right Fallopian tube; right ovary normal 61
—— —— in discussion on H. R. Spencer's paper on three cases of cancer of the cervix, complicating labour in advanced pregnancy, the patients remaining well eleven, eight and a half, and eight years after high amputation of the cervix 380
Spencer (H. R.), cancer of the body of the uterus simulating fibroid in a woman aged thirty-six (shown) . 235

PAGE
Spencer (H. R.), *Remarks* in reply . . . 238
—— degenerated fibro-myoma weighing over seventeen pounds enucleated from the broad ligament nine hours before delivery at term 122
—— fibro-myoma of the intra-abdominal portion of the round ligament of the uterus 26
—— *Remarks* in reply 50
—— galvano-cautery (shown) 353
—— three cases of cancer of the cervix complicating labour in advanced pregnancy, the patients remaining well eleven, eight and a half, and eight years after high amputation of the cervix 355
—— *Remarks* in reply 380
—— —— in discussion on W. A. Meredith's specimen of fibro-myoma of the cervix uteri, removed by abdominal panhysterectomy 13
—— —— in discussion on J. D. Malcolm's specimen of sloughing of the central part of a uterine fibro-myoma shortly after delivery 19
—— —— in discussion on J. H. Targett's specimen of unsuspected tuberculous salpingitis and pyosalpinx . 21
—— —— in discussion on F. N. Boyd's paper on two cases of abdominal hysterectomy for fibroids complicated by pregnancy 116
—— —— in discussion on A. H. N. Lewers's specimen of uterus with carcinoma of the body and multiple fibroids . 267
—— —— in discussion on R. Boxall's note on acute inversion of the uterus; spontaneous reposition . . 296
—— —— in discussion on M. Handfield-Jones's specimen of cancer and fibro-myoma coexisting in the body of the uterus 306
—— —— in discussion on J. M. Munro Kerr's paper on certain details regarding the operation of Cæsarean section in cases of contracted pelvis, based upon a series of thirty cases 333
—— —— in discussion on W. W. H. Tate's paper on three cases of intestinal obstruction following operations for fibroid tumour of uterus, with special reference to the choice of operation 405
Spleen, enlarged wandering, forming pelvic tumours (F. E. Taylor) 179
Stiven, Edward William Flemyng, M.D.Ed., Harrow-on-the Hill, obituary notice of 78

PAGE

STURMER (A. J.), abdominal gestation (shown) . . 385
—— forty-one cases of puerperal eclampsia treated by thyroid extract 126
Swayne, John Griffiths, M.D.Lond., Clifton, obituary notice of 79

Tait, Edward Wilmshurst, M.R.C.S., Hampstead, obituary notice of 78
TARGETT (J. H.), unsuspected tuberculous salpingitis and pyosalpinx (shown) 20
TATE (W. W. H.), dermoid cyst of the ovary removed by abdominal section five years after causing obstruction to labour (shown) 344
—— fibro-myoma and cystic disease coexisting in the same ovary (shown) 273
—— —— of uterus, with extensive carcinoma of body of uterus, and fibroma of ovary (shown) . . . 139
—— three cases of intestinal obstruction following operations for fibroid tumour of uterus, with special reference to the choice of operation 391
—— *Remarks* in reply 410
—— tuberculous disease of cervix and Fallopian tubes (shown) 138
—— two cases of diffuse adeno-myoma of uterus (shown) . 141
—— *Remarks* in discussion on H. R. Spencer's paper on three cases of cancer of the cervix complicating labour in advanced pregnancy, the patients remaining well eleven, eight and a half, and eight years after high amputation of the cervix 378
TAYLOR (Frank E.), adeno-myoma of the uterus (shown) . 188
—— fibroma of the ovary (shown) . . . 280
—— two cases of enlarged wandering spleen forming pelvic tumours (shown) 179
—— *Remarks* in discussion on W. W. H. Tate's specimen of two cases of diffuse adeno-myoma of uterus . . 144
—— —— in discussion on H. R. Spencer's specimen of cancer of the body of the uterus simulating fibroid in a woman aged thirty-six 237
—— —— in discussion on C. J. Cullingworth's and H. H. Clutton's notes on a case of hydatids of, or connected with, both ovaries, right broad ligament, liver, omentum, mesentery, and other parts 263
TAYLOR (John W.), *Remarks* in discussion on Alban Doran's paper on hæmatoma and hæmatocele . . . 224

PAGE
Thomas, Thomas Gaillard, M.D., New York (Hon. Fellow), obituary notice of 77
Thorne (Mary), *Remarks* in discussion on C. Lockyer's specimen of primary carcinoma of both ovaries . . 234
Thyroid extract, forty-one cases of puerperal eclampsia treated by (A. J. Sturmer) 126
Torsion of the pedicle in hydrosalpinx, and other morbid conditions of the Fallopian tube (R. H. Bell) . . 152
Tuberculosis of cervix (primary): further note (W. H. B. Brook) 265
Tumour, see *Cysts*.
Tumours, calcified fibroid of uterus, with acute axial rotation (J. Bland-Sutton) 149
—— cystic, in connection with the right Fallopian tube, arising probably from an accessory Fallopian tube (R. H. Bell) 21
—— —— of uterus (C. E. Purslow) 269
—— chorionepithelioma of the uterus, with secondary growths in the vagina, lungs, and the liver (G. F. Blacker) 55
—— fibroid, cancer of the body of the uterus in a woman aged thirty-six, simulating (H. R. Spencer) . . 235
—— —— of broad ligament (F. N. Boyd) . . . 348
—— —— of uterus, three cases of intestinal obstruction following operations for, with special reference to the choice of operation (W. W. H. Tate) . . . 391
—— —— —— with cystic degeneration of the surrounding tissues (M. Handfield-Jones) . . . 307
—— —— pregnancy in a uterus with; panhysterectomy during labour in the seventh month (J. Bland-Sutton) . 238
—— —— pregnant, of uterus removed by operation (A. Doran) 119
—— —— (multiple), in uterus with carcinoma of the body (A. H. N. Lewers) 266
—— —— two cases of abdominal hysterectomy for, complicated by pregnancy; with specimens (F. N. Boyd) . 106
—— fibroma of the ovary (F. E. Taylor) . . . 280
—— fibro-myoma of the cervix uteri, removed by abdominal panhysterectomy (W. A. Meredith) . . . 12
—— fibro-myoma of the intra-abdominal portion of the round ligament of the uterus (H. R. Spencer) . . 26

PAGE

Tumours, fibro-myoma, sloughing of the central part of a uterine, shortly after delivery (J. D. Malcolm) . . 15
—— —— of the uterus undergoing sarcomatous degeneration (P. Horrocks) 184
—— solid (fibro-myoma) mesenteric, weighing thirty pounds (A. Doran) 145
—— necrobiotic fibroid (F. N. Boyd) . . . 198
—— —— —— removed from a recently delivered patient aged twenty-two (J. S. Fairbairn) . . . 194
—— ovarian dermoid, section of the wall showing giant cells (H. Williamson) 299
—— ovarian dermoid with a twisted pedicle six inches in length (J. Bland-Sutton) 147
—— pelvic, two cases of enlarged wandering spleen forming (F. E. Taylor) 179
Twins, uniovular (C. Lockyer) 191

Uterus, abscess in (W. F. Victor Bonney) . . . 2
—— abscess of, developing during the puerperium; rupture into the peritoneal cavity; abdominal section; recovery (A. W. W. Lea) 7
—— acute inversion of: spontaneous reposition (R. Boxall) . 292
—— adeno-myoma of (F. E. Taylor) . . . 188
—— calcified fibroid of, with acute axial rotation (J. Bland-Sutton) 149
—— cancer and fibro-myoma coexisting in the body of (M. Handfield-Jones) 305
—— cancer of the body of, simulating fibroid in a woman aged thirty-six (H. R. Spencer) . . . 235
—— carcinoma in the muscular wall of, secondary to cancer of both ovaries (C. Lockyer) 302
—— cervix of, further note on a case of primary tuberculosis of (W. H. B. Brook) 265
—— cervix of, three cases of cancer of, complicating labour in advanced pregnancy, the patients remaining well eleven, eight and a half, and eight years after high amputation of the cervix (H. R. Spencer) . . . 355
—— chorionepithelioma of, with secondary growths in the vagina, the lungs, and the liver (G. F. Blacker) . 55
—— cystic tumour of (C. E. Purslow) . . . 269
—— fibroid of, with cystic degeneration of the surrounding tissues (M. Handfield-Jones) 307

PAGE

Uterus, fibroid tumour of, intestinal obstruction following operations for (W. W. H. Tate) . . . 391
—— fibro-myoma of cervix of, removed by abdominal panhysterectomy (W. A. Meredith) . . . 12
—— fibro-myoma of the intra-abdominal portion of the round ligament of (H. R. Spencer) 26
—— fibro-myoma of, undergoing sarcomatous degeneration (P. Horrocks) 184
—— fibro-myoma of, with extensive carcinoma of body of, and fibroma of ovary (W. W. H. Tate) . . . 139
—— necrobiotic, associated with recent pregnancy (A. Doran and H. Williamson) 274
—— pregnant fibroid tumours of, removed by operation (A. Doran) 119
—— pregnant, with cancerous cervix removed by panhysterectomy (F. N. Boyd) 345
—— sloughing of the central part of a fibro-myoma of, shortly after delivery (J. D. Malcolm) . . . 15
—— spontaneous reposition of inverted (R. Boxall) . . 292
—— tuberculous disease of cervix of, and Fallopian tubes (W. W. H. Tate) 138
—— tumours of, see *Tumours*.
—— two cases of diffuse adeno-myoma of (W. W. H. Tate) . 141
—— with carcinoma of the body and multiple fibroids (A. H. N. Lewers) 266
—— with fibroids, pregnancy in; panhysterectomy during labour in the seventh month (J. Bland-Sutton) . . 238

Vagina, chorionepithelioma of uterus with secondary growths in (G. F. Blacker) 55

Wallace, R. J., M.D., Calcutta, obituary notice of . . 78
Williamson (Herbert) and Harrison Cripps, two cases involving the question of the site of impregnation . 89
—— *Remarks* in reply 102
—— section of the wall of an ovarian dermoid showing giant cells (shown) 299
—— see *Doran (Alban)*.
Wilson (Thomas), *Remarks* in discussion on H. R. Spencer's paper on three cases of cancer of the cervix complicating labour in advanced pregnancy, the patients remaining well eleven, eight and a half, and eight years after high amputation of the cervix 378

OBSTETRICAL SOCIETY.

ADDITIONS TO THE LIBRARY

BY DONATION OR PURCHASE DURING THE YEAR 1904.

Presented by

Adler (Otto). Die mangelhafte Geschlechtsempfindung des Weibes. Anæsthesia sexualis feminarum. Dyspareunia Anaphrodisia. 8vo. Berlin, 1904 Purchased.

Baisch (Karl). Die Begutachtung gynäkologischer Erkrankungen für die Unfall- und Invaliditätsversicherungen. (Volkmann's Sammlung klinischer Vorträge. Neue Folge, Nr. 367.) 8vo. Leipzig, 1904 Ditto.

Ballantyne (J. W.). Essentials of Obstetrics. 8vo. Edinburgh and London, 1904 Ditto.

——— Manual of ante-natal pathology and hygiene. The embryo. *illust.*, 8vo. Edinburgh, 1904. Ditto.

Barbour (A. H. Freeland). See *Hart*.

Binswanger (Otto). Die Hysterie. (Specielle Pathologie und Therapie herausgegeben von Hofrath. Prof. Dr. Hermann Nothnagel. XII Band, I Hälfte, II Abtheilung.) *illust.*, 8vo. Wein, 1904 Ditto.

Breus (Carl) und Alexander Kolisko. Die pathologischen Beckenformen. I Band, I Theil. Allgemeines. Missbildungs-Assimilations-und Zwergbecken. *illust.*, 8vo. Leipzig u. Wien, 1904 Ditto.

Budin (P.) et L. Demelin. Manuel pratique d'accouchements et d'allaitement. *illust.*, 8vo. Paris, 1904 Ditto.

Presented by

Caruso (Francesco). Ueber Anaemie in der Schwangerschaft. (Volkmann's Sammlung klinischer Vorträge, neue Folge, Nr. 378.)
8vo. Leipzig, 1904 Purchased.

Catalogue of books added to the Radcliffe Library, Oxford University Museum, during the year 1903 4to. Oxford, 1904 The Radcliffe Librarian.

Chrobak (R.). Ueber Retroversio und Retroflexio uteri gravidi. (Volkmann's Sammlung klinischer Vorträge, neue Folge, Nr. 377.)
8vo. Leipzig, 1904 Purchased.

Cullen (Thomas S.). Adeno-Myome des Uterus.
illust., 8vo. Berlin, 1903 Ditto.

Cullingworth (Charles J.). A plea for exploration in suspected malignant disease of the ovary, with illustrative cases. Being the Ingleby Lectures for 1904. Reprinted from 'The Birmingham Medical Review,' June—July, 1904. Author.

——— Charles White, F.R.S. A great provincial surgeon and obstetrician of the eighteenth century. An address delivered before the Medical Society of Manchester, October 7th, 1903. *illust.*, sm. 8vo. London, 1904. Ditto.

Demelin (L.). See *Budin.*

Dohrn (Rudolf). Geschichte der Geburtshülfe der Neuzeit. Zugleich als dritter Band des "Versuches einer Geschichte der Geburtshülfe" von Eduard von Siebold. Zweite Abtheilung. Zeitraum, 1860—1880. sm. 8vo Tübingen, 1904 Purchased.

Edgar (J. Clifton). The Practice of Obstetrics. 2nd edit., revised. *illust.*, la. 8vo. London, 1904 Ditto.

Fiedler (Otto). Beitrag zur Kenntnis der syncytialen Tumoren. *Thesis.* Kiel, 1900 Ditto.

Fothergill (W. E.). Manual of midwifery for the use of students and practitioners. 3rd edit.
illust., sm. 8vo. Edinburgh, 1903 Ditto.

Frank (Fritz). Die Errichtung Geburtshilflicher Polikliniken an Hebammenschulen.
8vo. Berlin, 1904 Ditto.

Frankl (Oscar). Ueber Missbildungen der Gebärmutter und Tumoren der Uterusligamente, im Lichte embryologischer Erkenntnisse. (Volkmann's Sammlung klinisher Vorträge, neue Folge, Nr. 363.) 8vo. Leipzig, 1903 Ditto.

Presented by

FREUND (Richard). Zur Lehre von den Blutgefässen der normalen und kranken Gebärmutter. *illust.*, 8vo. Jena, 1904 Purchased.

FRITSCH (Henrich). Beiträge zur Geburtshilfe und Gynäkologie. *Festschrift* dem Director der Kgl. Universitäts-Frauenklinik zu Bonn, Herrn Geheimen Medicinalrath Professor Dr. Heinrich Fritsch bei Gelegenheit des 25jahrigen Bestehens des *Centralblatts für Gynäkologie* in Dankbarkeit und Verehrung gewidmet von seinen Schülern. *illust.*, 8vo. Leipzig, 1902 Ditto.

GALABIN (Alfred Lewis). A manual of midwifery. 6th edit. *illust.*, 8vo. London, 1904 Author.

——— Diseases of women. 6th edit., much enlarged. *illust.*, 8vo London, 1903 Ditto.

HART (D. Berry) and A. H. Freeland BARBOUR. Manual of gynæcology. 6th edit. *illust.*, 8vo. Edinburgh and London, 1904 Purchased.

HIRST (Barton Cooke). A text-book of diseases of women. *illust.*, 8vo. Philadelphia, New York, and London, 1903 Ditto.

KANTOROWICZ (Ludwig). Eierstockschwangerschaft. (Volkmann's Sammlung klinischer Vorträge, neue Folge, Nr. 370.) 8vo Leipzig, 1904 Ditto.

KERMAUNER (Fritz). Beiträge zur Anatomie der Tubenschwangerschaft. 8vo. Berlin, 1904 Ditto.

KISCH (E. HEINRICH). Das Geschlechtsleben des Weibes in physiologischer, pathologischer und hygienischer Beziehung. 8vo. Berlin u. Wien, 1904 —

KLIX (Dr.). Ueber die Geistesstörungen in der Schwangerschaft und im Wochenbett. (Sammlung zwangloser Abhandlungen aus dem Gebiete der Frauenheilkunde und Geburtshilfe.) Herausgegeben von Dr. Max Graefe in Halle-a.-S., V Band, Heft 6. Purchased.

KNAPP (Ludwig). Der Scheintod der Neugeborenen. Seine Geschichte, klinische und gerichtsärztliche Bedeutung. II Klinisher Teil. *illust.*, 8vo. Wien u. Leipzig, 1904 Ditto.

LABADIE-LAGRAVE (F.) et Félix LEGUEU. Traité médico-chirurgical de Gynécologie. 3ième édit. *illust.*, 8vo. Paris, 1904 Ditto.

Presented by

Landau (Theodor). Wurmfortsatzentzündung und Frauenleiden. 8vo. Berlin, 1904 Purchased.

Legueu (Félix). See *Labadie-Lagrave.*

Lenhossék (M. von). Das Problem der geschlechtsbestimmenden Ursachen. *illust.*, 8vo. Jena, 1903 Ditto.

Malcolm (John D.). Cases of extra-uterine fœtation, and some cases of hæmatocele in the first forty-four volumes of the 'Transactions' of the Obstetrical Society of London. 4to. typewritten, 1904 Author.

Mandl (Ludwig) und Oskar Bürger. Die biologische Bedeutung der Eierstöcke nach Entfernung der Gebärmutter. Experimentelle und klinische Studien. *illust.*, 8vo. Leipzig u. Wien, 1904 Purchased.

Montgomery (E. E.). Practical Gynæcology. A comprehensive text-book for students and physicians. Second revised edition.
illust., 8vo. London, 1904 Ditto.

Nagel (Wilhelm). Gynäkologie für Aerzte und Studierende. Zweite verbesserte und vermehrte Auflage. *illust.*, 8vo. Berlin, 1904 Ditto.

Nothnagel (Hermann). See *Binswanger.*

Pollak (Emil). Kritisch-experimentelle Studien zur Klinik der puerperalen Eklampsie.
8vo. Leipzig u. Wien, 1904 Purchased.

Roberts (C. Hubert). Orthmann's handbook of gynæcological pathology. Translation. Assisted by Max L. Trechmann. 8vo. London, 1904 Author.

Runge (Max). Lehrbuch der Geburtshülfe. Siebente Auflage. *illust.*, 8vo. Berlin, 1903 Purchased.

Sawyer (Sir James). Contributions to practical medicine. 4th edit., with many revisions and additions. sm. 8vo. Birmingham, 1904 Author.

Schapiro (D.). Obstétrique des anciens Hébreux d'après la Bible, les Talmuds et les autres sources rabbiniques, comparée avec la tocologie gréco-romaine. 8vo. Paris, 1904 Purchased.

Schultze (Bernhard Sigmund). Lehrbuch der Hebammenkunst. 13te Auflage.
illust., 8vo. Leipzig, 1904 Author.

Presented by

SINCLAIR (W. J.). The Midwives Act, 1902, and the teaching of midwifery to students of medicine. An address at the beginning of the course of obstetrics, at Owens College, April 23rd, 1903. Author.

STRASSMANN (P.). Beginn, Begriff der Schwangerschaft. Vorgänge bei der Befruchtung, erste Veränderungen des Eies. (Sonderdruck aus: "Handbuch der Geburtshülfe." Herausgegeben von F. v. Winckel, München. 1 Band, 1 Hälfte.) Dr. Strassmann.

TABLES des thèses soutenues à la Faculté de Médecine de Paris pendant l'année scolaire, 1902—1903. 4to, Paris, 1903 Purchased.

VOLKMANN'S Sammlung klinischer Vorträge, neue Folge:

363. *Frankl,* Über Missbildungen der Gebärmutter und Tumoren der Uterusligamente, im Lichte embryologischer Erkenntnisse.
367. *Baisch,* Die Begutachtung gynäkologischer Erkrankungen für die Unfall- und Invaliditäts-versicherungen.
370. *Kantorowicz,* Eierstockschwangerschaft.
373, 374. *Winckel,* Ueber menschliche Missbildungen (besonders Gesichtsspalten und Zystenhygrome).
377. *Chrobak,* Ueber Retroversio und Retroflexio uteri gravidi.
378. *Caruso,* Ueber Anaemie in der Schwangerschaft.
379. *Zangemeister,* Neuere physiologische Forschungen in der Geburtshilfe.

WHITE (Charles.) A great provincial surgeon and obstetrician of the eighteenth century. See *Cullingworth (C. J.).*

WIGGINS (W. Denison). Midwifery for midwives. sm. 8vo. London, 1904 Publishers.

WILLIAMS (J. Whitridge). A sketch of the history of obstetrics in the United States up to 1860. (Published originally in Professor Dohrn's Geschichte der Geburtshülfe der Neuzeit, zugleich als dritter Band des "Versuchs einer Geschichte der Geburtshülfe," von Eduard von Siebold. Tübingen, 1903. Erste Abtheilung, pp. 193—264.) la. 8vo. Balt. Author.

——— Indications for and most satisfactory methods of bringing about premature labor and accouchement forcé. Reprinted from 'American Gynecology,' vol. iii, No. 1, July, 1903. Ditto.

Presented by

Williams (W. Roger). Vaginal tumours with special reference to cancer and sarcoma. 8vo. Lond., 1904 Purchased.

Wilms (M.). Die Mischgeschwülste, III (Schluss) Heft. 8vo. Leipzig, 1902 Ditto.

Winckel (F. von). Handbuch der Geburtshülfe. Erster Band, II Hälfte. *illust.*, 8vo. Wiesbaden, 1904 Ditto.

——— ——— Zweiter Band, I Teil. *illust.*, 8vo. Wiesbaden, 1904 Ditto.

——— ——— Zweiter Band, II Teil. *illust.*, 8vo. Wiesbaden, 1904 Ditto.

——— Ueber menschliche Missbildungen (besonders Gesichtsspalten und Zystenhygrome). (Volkmann's Sammlung klinischer Vorträge, neue Folge, Nr. 373—374). 8vo. Leipzig, 1904 Ditto.

Zangemeister (W.). Neuere physiologische Forschungen in der Geburtshilfe. (Volkmann's Sammlung klinischer Vorträge, neue Folge, Nr. 379.) 8vo. Leipzig, 1904 Ditto.

TRANSACTIONS.

Clinical Society of London— Transactions, vol. xxxvii. 8vo. Lond. 1904 Society.

Deutsche Gesellschaft für Gynäkologie— Verhandlungen. Zehnte Versammlung abgehalten zu Würzburg, 1903. 8vo. Leipzig, 1904 Ditto.

Kjobenhavnske (Det) medicinske Selskabs— Forhandlinger 1903-4, redigeret af Dr. Fr. Vogelius. 8vo. Copenhagen. 1904 Ditto.

Medical (Royal) and Chirurgical Society— Transactions, vol. lxxxvii. 8vo. Lond. 1904 Ditto.

Medical Society of London— Transactions, vol. xxv. 8vo. Lond. 1903 Ditto.

New York Academy of Medicine— 1896—1901. Semi-centennial celebration. 8vo. New York. 1903 Academy.

Société de Médecine de Rouen— Bulletin, 2e Série, volume xvi. 41e année, 1902. 8vo. Rouen, 1903 Society.

REPORTS.

	Presented by
America—Hospitals—Boston Lying-in Hospital: the 71st year for 1903 8vo. Boston, 1904	Hospital Staff.
——— ——— Johns Hopkins Hospital (The). Reports, vol. xi, Nos. 1—9. la. 8vo. Balt. 1903	Ditto.
——— ——— Medical and Surgical Report of the Presbyterian Hospital in the City of New York, vol. vi, January, 1904. 8vo. New York, 1904	Ditto.
——— ——— The Society of the New York Hospital. Annual Report for the year 1903. 8vo. New York, 1904	Society.
Hospitals—Guy's Hospital Reports, 3rd Series, vol. xliii. 8vo. Lond. 1904	Hospital Staff.
——— Middlesex Hospital Reports for the year 1902. 8vo. Lond. 1904	Ditto.
——— St. Bartholomew's Hospital Reports, vol. xxxix. 8vo. Lond. 1904	Ditto.
——— St. Thomas's Hospital Reports, New Series, vol. xxxi. 8vo. Lond. 1902	Ditto.
——— Annual Report of the Government Maternity Hospital, Madras, for the year 1903. la. 8vo. Madras, 1904	Ditto.
Jahresbericht der Gesellschaft für Natur- und Heilkunde in Dresden. Sitgungsperiode 1902—1903. 8vo. Munich, 1904	Society.
Jahresbericht ueber die Fortschritte auf dem Gebiete der Geburtshilfe und Gynäkologie, herausgegeben von Richard Frommel, xvi Jahrgang, 1902. 8vo. Wiesbaden, 1903	Dr. Frommel.
——— XVII Jahrgang, 1903. 8vo. Wiesbaden, 1904	Ditto.
Germany—Lying-in Institutions—Die Universitäts-Frauenklinik in Heidelberg von Dr. phil. Fritz Hirsch und Professor Dr. Alfons v. Rosthorn. 8vo. Heidelberg, 1904	Purchased.
Report of the Select Committee on ventilation appointed by the House of Commons. (Blue Book, 1903.) sm. 8vo. London, 1904	Committee.

PRINTED BY ADLARD AND SON, LONDON AND DORKING.

SERIAL

RC
1
03
v.46

Obstetrical Society of
London
Transactions

GERSTS